

Bangor University

DOCTOR OF PHILOSOPHY

Neuroanatomical and perceptual deficits in auditory agnosia : a study of an auditory agnosia patient with inferior colliculus damage

Poliva, Oren

Award date:
2015

Awarding institution:
Bangor University

[Link to publication](#)

General rights

Copyright and moral rights for the publications made accessible in the public portal are retained by the authors and/or other copyright owners and it is a condition of accessing publications that users recognise and abide by the legal requirements associated with these rights.

- Users may download and print one copy of any publication from the public portal for the purpose of private study or research.
- You may not further distribute the material or use it for any profit-making activity or commercial gain
- You may freely distribute the URL identifying the publication in the public portal ?

Take down policy

If you believe that this document breaches copyright please contact us providing details, and we will remove access to the work immediately and investigate your claim.

**Neuroanatomical and Perceptual deficits in Auditory Agnosia:
A Study of an Auditory Agnosia Patient
With Inferior Colliculus Damage**

Oren Poliva

Bangor University

A thesis submitted to the School of Psychology, Bangor University, in partial fulfillment of the requirement for
the Degree of Doctor of Philosophy.

September 2014

Acknowledgments:

I would like to extend grateful thanks to Professor Robert Rafal for his expertise and guidance throughout these experiments and express my admiration for his close reading of even the most inelegantly written manuscripts. I would also like to extend my gratitude to Dr Patricia Bestelmeyer, Professor Guillaume Thierry, Dr Janet Bultitude, PhD candidate Michel Hall and research co-ordinator Becca Henderson for their contribution to the study of this patient. Without the help of these individuals, it is fair to say that this thesis could not have been completed.

I would also like to thank the members of my supervision committee Dr Stephan Boehm and Dr Ayeleyt Sapir for their input and sound advice.

I'd like to thank my parents, siblings and friends for the love and support that they've given me not just during this work, but before and beyond, and for my son, who did everything in his power for preventing me from finishing this thesis on time.

Table of Contents

| | |
|--|----|
| List of Figures | 11 |
| List of Tables | 12 |
| Summary | 13 |
| Chapter 1 - Preface | 15 |
| Chapter 2 - Introduction | 17 |
| 2.1 The auditory system and auditory disorders | 18 |
| 2.1.1 The peripheral auditory system | 18 |
| 2.1.2 The sub-cortical auditory system | 24 |
| 2.1.3 The auditory cortex | 30 |
| 2.1.4 Electrophysiological Recordings in the Human Auditory System | 38 |
| 2.2 Auditory Agnosia - History | 41 |
| 2.3 Auditory Agnosia and Related Disorders | 46 |
| 2.3.1 Cerebral Deafness | 46 |
| 2.3.2 Pure Word Deafness | 47 |
| 2.3.3 Auditory Agnosia for Environmental Sounds | 52 |
| 2.3.4 Amusia | 54 |
| 2.3.5 Word Meaning Deafness | 55 |
| 2.4 Psychological Deficits in Auditory Agnosia | 57 |
| 2.5 Auditory Agnosia - Open Questions | 60 |
| Chapter 3 - Case Study | 61 |

| | |
|--|----|
| 3.1 History | 61 |
| 3.2 Discussion | 63 |
| Chapter 4 - Auditory Agnosia and the Scientific Literature | 67 |
| 4.1 Introduction | 67 |
| 4.2 Methods | 69 |
| 4.3 Results and Discussion | 71 |
| Chapter 5 - Behavioral Experiments | 75 |
| 5.1 Introduction | 75 |
| 5.2.1 Sound Identification and Recognition | 76 |
| 5.2.1.1 Methods | 76 |
| 5.2.1.2 Results | 76 |
| 5.2.1.3 Discussion | 78 |
| 5.2.2 Two Click Fusion Test and Two Box Fusion Test | 80 |
| 5.2.2.1.1 Methods - Two Click Fusion | 80 |
| 5.2.2.1.2 Methods - Two Box Fusion | 80 |
| 5.2.2.2,1 Click Fusion Test - Results | 80 |
| 5.2.2.2,1 Box Fusion Test - Results | 81 |
| 5.2.2.3 Discussion | 81 |
| 5.2.3 VOT-POA Discrimination | 82 |
| 5.2.3.1 Methods | 82 |
| 5.2.3.2 Results | 82 |

| | |
|--|-----|
| 5.2.3.3 Discussion | 83 |
| 5.2.4 Dichotic Listening Task | 84 |
| 5.2.4.1 Methods | 84 |
| 5.2.4.2 Results | 84 |
| 5.2.4.3 Discussion | 84 |
| 5.2.5 Auditory Localization Task | 86 |
| 5.2.5.1 Methods | 86 |
| 5.2.5.2 Results | 86 |
| 5.2.5.3 Discussion | 88 |
| 5.3 Chapter Discussion | 90 |
| Chapter 6 - Auditory Agnosia - fMRI Study | 91 |
| 6.1 Introduction | 91 |
| 6.2 Methods | 91 |
| 6.2.1 Participants | 91 |
| 6.2.2 Design | 91 |
| 6.2.3 Imaging protocol | 92 |
| 6.2.4 Analysis and mapping of BOLD activation in auditory fields | 96 |
| 6.3 Results | 96 |
| 6.4 Discussion | 99 |
| Chapter 7 - Auditory Agnosia and Mis-Match Negativity | 101 |
| 7.1 Introduction | 101 |

| | |
|--|-----|
| 7.2 Methods | 102 |
| 7.2.1 Participants | 102 |
| 7.2.2 EEG Recordings | 102 |
| 7.2.3 Experimental Design | 103 |
| 7.3 Results | 104 |
| 7.4 Discussion | 105 |
| Chapter 8 - General Discussion | 110 |
| 8.1 Auditory Agnosia is due to Dysfunctional Processing in the Auditory Ventral Streams | 112 |
| 8.2 Auditory Agnosia Patients Perceive Sounds Via the Auditory Dorsal Stream | 116 |
| 8.3 Auditory Agnosia as a Deficit in the Perception of Auditory Objects | 120 |
| 8.4 Auditory Agnosia as an Auditory Temporal discrimination Deficit | 123 |
| 8.5 Assessment of Auditory Agnosia | 125 |
| 8.6 Functional Connectivity in the Auditory Cortex | 126 |
| 8.7 Concluding Notes and Future research | 127 |
| Chapter 9 - Appendix A: List of patients with inferior colliculus damage | 129 |
| Chapter 10 - Appendix B: List of patients with auditory impairment due to temporal lobe damage | 135 |
| Chapter 11 - Appendix C: T1 Weighted Images | 160 |
| Chapter 12 - References | 162 |

Figures

| | |
|---|-----|
| Figure 1. The peripheral auditory system | 22 |
| Figure 2. The sub-cortical auditory system..... | 29 |
| Figure 3. The auditory cortex..... | 37 |
| Figure 4. Auditory evoked potentials..... | 39 |
| Figure 5. The Wernicke-Lichtheim language model..... | 45 |
| Figure 6. Lesion localization with MRI..... | 65 |
| Figure 7. Pure tone and narrow band audiometry..... | 66 |
| Figure 8. Age demographic distribution of patients with auditory perceptual deficits..... | 74 |
| Figure 9. Auditory localization task..... | 87 |
| Figure 10. fMRI activation - display from above.. .. | 93 |
| Figure 11. fMRI activation - display from the side..... | 94 |
| Figure 12. fMRI activation - ROI analysis. | 95 |
| Figure 13. Mismatch negativity - EEG of standard and deviant components. | 108 |
| Figure 14. Mismatch negativity - The MMN component..... | 109 |
| Figure 15. T1-Weighted axial images..... | 160 |
| Figure 16. T1-Weighted coronal images..... | 161 |

Tables

| | |
|--|-----|
| Table 1. Hemispheric damage in auditory disorders..... | 74 |
| Table 2. Identification and recognition of spoken words..... | 77 |
| Table 3. Identification and recognition of spoken environmental sounds | 78 |
| Table 4. The deviants and standards of the mismatch negativity study | 107 |
| Table 5. List of patients with inferior colliculus damage..... | 129 |
| Table 6. List of patients with auditory impairment due to temporal lobe damage | 135 |

Summary:

Auditory agnosia is a rare disorder in which individuals lose the ability to understand sounds. In this thesis, I examine an auditory agnosia patient with brainstem damage, but intact cortex. The patient was severely impaired when instructed to type the names of sounds. The patient, however, was only mildly impaired when instructed to choose the correct sound out of four written alternatives, which implies partial auditory perception.

In two fMRI scans, conducted a year apart, passive listening to sounds resulted with a unique activation pattern in her auditory cortices. In particular, her anterior primary and associative auditory fields were much less responsive to sounds than more posterior primary and associative auditory fields. The functional dissociation between these regions suggests connections between the anterior primary and associative regions, and between the posterior primary and associative regions. Hitherto, these connections were only reported in monkeys.

An EEG study that examined mismatch negativity for frequency, duration, and intensity of sounds, demonstrated that the patient's ability of detecting changes to frequency and duration of sounds is bilaterally impaired, whereas the detection of changes to sound's intensity is impaired in the left hemisphere but intact in the right hemisphere. Behavioral studies also show that the patient's auditory perceptual deficit is partially due to impaired perception of the duration of sounds. For instance, when the patient heard two subsequent clicks, she was impaired at discriminating these sounds by the duration of their intervening interval. In a spoken word discrimination task, she was also impaired at discriminating words that could only be distinguished by their temporal properties (voice onset-time). Based on these findings, I argue that the patient experiences auditory agnosia be-

cause the brain stem injury prevents the transmission of critical auditory information to the auditory cortex. As a result of this absence, the auditory fields responsible for sound recognition, the anterior auditory fields, are not recruited.

In a dichotic listening task, the patient extinguished sounds presented to the right ear, and in a sound localization task she perceived sounds as emerging from the left auditory hemi-field. Given cumulative evidence that associates the posterior auditory cortex with sound localization and phonological-acoustic analysis of verbal material from the contra-lateral hemi-field, the patient's performance in these tasks suggest that her spared auditory abilities is due to processing in her right posterior auditory cortex. This role of the patient's right posterior auditory cortex is consistent with both the fMRI study, in which the right posterior auditory cortex was consistently responsive to sounds, and the EEG study, in which detection of changes to sound intensity was restricted to the right hemisphere.

1. Preface:

Auditory agnosia (AA) is a disorder characterized by an isolated deficit to auditory perception. Patients suffering from AA often describe sounds as over-riding each other, unclear or as if emanating from another room.

This disorder manifests after suffering brain damage to auditory processing centers, primarily the auditory cortex. AA is a very elusive disorder, and although has been studied for more than 130 years, its underlying pathophysiology is still unknown.

The present thesis is chiefly a systematic and comprehensive assessment of a single case study of a patient with AA due to inferior colliculi (IC) damage, primarily on the left side. There is a remarkable similarity between the symptoms expressed by this patient and the symptoms expressed by patients with direct damage to the auditory cortex. This patient thus provides us with a rare opportunity to illuminate the neural basis of audition and the pathophysiology of AA by systematically comparing this patient's symptoms to the symptoms of patients with cortical damage. In this thesis, I examine the patient using functional magnetic resonance imaging (fMRI), electroencephalogram (EEG) recordings and behavioral tests. Based on these studies, I argue that the patient's auditory perceptual deficit manifests because, downstream to the IC, the auditory cortices receive distorted or diminished auditory input and as a consequence the cortical regions dedicated for extracting meaning from sounds, the anterior auditory cortices, are not recruited. To the best of my knowledge, this is the first study that suggests a link between dysfunctional sound processing in the anterior auditory cortices and a sound recognition deficit in humans. In the present manuscript I also argue that the patient's remaining auditory perception is due to spared auditory processing in her right posterior auditory cortex; and further theorize that the posterior audi-

tory cortices are responsible for the remaining auditory perception of other AA patients as well. This study is valuable for future researchers who are interested in further examining this disorder, and for researchers who are interested in mapping the human auditory cortex.

2. Introduction:

The auditory system is unique among the senses in its multi-level and hierarchical processing, which encompasses almost all brain regions (e.g., medulla, pons, midbrain, thalamus and cortex). In the present chapter, I summarize the literature on the anatomy and physiology of the auditory system, with a special attention to the effect of brain damage of each of the auditory centers on auditory perception. I then discuss early models of auditory processing in the cortex, and the role they played in the discovery and research of AA. Next, I present evidence for the existence of different sub-types of AA. Then, I discuss recent advancements in our understanding of the psychological experience of AA patients. In the final portion of this chapter, I discuss how all the studies presented in this chapter motivate the research reported in this dissertation.

2.1 The auditory system and auditory disorders:

In this section, I divide the auditory system into three parts: 1) the peripheral auditory system, which converts air vibrations into a neural code, 2) the sub-cortical auditory system, which processes basic acoustic properties, and 3) the auditory cortex, which is responsible for the perception and recognition of auditory objects.

2.1.1 The peripheral auditory system:

In the peripheral auditory system, air vibrations are converted into mechanical movements and then into an electrical neural code. The peripheral nervous system is composed of three parts: the outer ear, the middle ear and the inner ear (letters O, M, I in Fig. 1A).

The outer ear includes the pinna and the ear canal (Fig. 1A). The pinna is a plate like structure and the ear canal is a hole in the skull located at the center of the pinna. Mathematical models demonstrated that the design of the pinna maximizes the conduction of air vibrations into the ear canal (Rabbit, 1990; Stinson and Khanna, 1989).

In some mammalian species the pinna is mobile, which enables regulatory control over the level of acoustic input.

The middle ear (Fig. 1A) is located in a small cavity of the mastoid bone slightly above the ear canal (tympanic cavity). Bordering between the ear canal and the tympanic cavity is the eardrum (tympanic membrane), which is a stretched flap of skin that systemically folds and unfolds in response to air vibrations. In order to avoid stiffness of the eardrum due to higher pressure level in the middle ear than ear canal, a canal that connects the tym-

panic cavity with the pharynx (eustachian tube) allows air to flow into the middle ear during swallowing to equalize the pressure levels (Rabbit, 1990).

The middle ear consists of three bones: the hammer, anvil and stirrup (Fig. 1A). The hammer is attached on one side to the eardrum and to the anvil on the other. The anvil is further attached to the stirrup, which in turn is attached to a membrane of the inner ear called the oval window. The three bones loosely hang from the surrounding bone via suspensory ligaments, and serve to conduct and amplify the air vibrations of the eardrum onto the oval window. The stirrup is also connected to the surrounding bone via the stapedius muscle, and the hammer is connected via the tensor tympani muscle. As a protective mechanism, these muscles constrict when exposed to loud sounds, which reduces sound amplification. Fusion or disconnection of the bones of the middle ear results in deafness from the same ear, known as conduction deafness (Palva and Ojala, 1955).

The inner ear is a series of canals located deep in the petrous bone (Fig. 1A). It is composed of two compartments, the cochlea, which is part of the auditory system, and the vestibule and semi-circular canals, which are part of the vestibular system. In mammals, the cochlea coils around a bony core (modiolus) two and a half times, forming a spiral shape. Because the cochlea is filled with a liquid (perilymph), air vibrations are here converted into waves (Fig. 1B). The cochlea is divided into two canals by an intermediate membranous canal, the scala media, which is filled with a different liquid (endolymph). Two membranes connects the cochlea with the tympanic cavity, the round window and the oval window. The canal above the scala media, the scala vestibuli, is connected to the oval window, and the one below the scala media, the scala tympani, is connected to the round window (Fig. 1B). In the inner most region of the cochlea (helicotrema), the scala media is not present, and the scala vestibuli and scala tympani are connected. Because the oval window is connected to the

middle ear, listening to sounds results in waves spreading from the oval window to the scala vestibuli. At the helicotrema, the waves then spread into the scala tympani. Each wave ends with the folding and unfolding of the round window.

The membranes separating the scala media from the scala vestibuli and scala tympani are known as Reissner's membrane and basilar membrane, respectively (Fig. 1B, C). Along the basilar membranes (facing the scala media) are lines of sensory cells known as hair cells (Fig. 1C,D). As a group, these hair cells are referred to as the organ of Corti. At the tip of each hair cell are hair-like protrusions (stereocilia), which are further attached to a second membrane located above them (the tectorial membrane; Fig. 1C,D). When hearing sounds, the perilymphatic wave displaces the basilar membrane. Because these waves displace the basilar membrane more than the tectorial membrane, and the hair cells are connected to both membranes, sounds cause deflection of the stereocilia. This event depolarizes the electrical charge of the hair cells. The basilar membrane is not uniform in shape (i.e., it is narrowest and stiffest in its basal segment, and widest and most flaccid near the helicotrema). Consequently, sounds of different frequencies displace the basilar membrane and activate the hair cells at different locations. High tonal frequencies (up to 20,000 Hz) cause maximal displacement of the basilar membrane in its basal segment, middle frequencies in its middle, and low frequencies (low as 20 Hz) near the helicotrema (i.e., apex). Thus, the cochlea is characterized by a gradient of tones (i.e., cochleotopic organization).

There are two types of hair cells in the organ of Corti: inner hair cells (3500 cells) and outer hair cells (12,000 cells). These cells are organized in four lines: a medial line of inner hair cells and 3-4 lateral lines of outer hair cells (Fig. 1D). Throughout the bony area of the cochlea, medial to the hair cells, are neurons with bifurcating axons that synapse on one side with the hair cells of the organ of Corti, and on the other side synapse with neu-

rons in the cochlear nucleus in the brainstem (i.e., the cochlear nerve). Because the cell body of these neurons maintains the spiral shape of the cochlea, it is called the spiral ganglion. The inner hair cells are the primary source of afferents to the cochlear nucleus in the brainstem (type I afferents; Figure 1D), and each such cell was shown to innervate 6-8 type I afferents of the cochlear nerve (Nadol, 1990). The outer hair cells, although provide only 5-10% of afferents to the cochlear nucleus (type II afferents), receive significant innervation via the cochlear nerve from the superior olivary nucleus of the brainstem. The outer hair cells also vibrate as a response to sounds. This vibration causes the outer hair cells to change their length in accordance with the intensity of the sound. This structural plasticity of the outer hair cells increases the sensitivity of the cochlea to sounds, and can increase sensitivity to specific frequencies. Like the cochlea, the spiral ganglion also encodes high tones in the internal segment of the spiral, middle tones in its central segment and low tones in the external segment of the spiral (i.e., cochleotopic organization; Moskowitz and Liu, 1972). In the cochlear nerve, the initial segment of the fibers (100 μ m) is un-myelinated and regarded as the dendrite of the neurons (Spoendlin and Schrott, 1989). In the remaining cochlear nerve, the myelin is formed by Schwann cells laterally, and oligodendritic glia cells medially. The latter section of the cochlear nerve is regarded as part of the central auditory system. Damage to the cochlear nerve results in unilateral deafness of the same ear (Mc Laughlin et al., 1999).

A method for assessing damage to the cochlea is with otoacoustic emissions (Kemp et al., 1990). In this method, sounds of different frequencies are emitted into the ear canal. As a result, outer hair cells of that frequency modify their length. This change in the cellular shape evokes a sound that is recorded by a microphone located in the ear canal. Absence of evoked sound indicates of damage to the organ of Corti. Another method for assessing the function of the cochlea is with electrocochleography (Kaga et al., 1996; Margolis et al., 1995). In this method, an electrode is attached to the ear drum via the ear canal and 1000Hz tone burst is presented. Because of electri-

cal activity discharged from the outer hair cells, the inserted electrode records electrical waves that are very similar in shape to the sound wave. This wave is known as cochlear microphonics. In damaged cochlea, therefore, there is no activation of the outer hair cells and no cochlear microphonics. Cochlear microphonics are inhibited by top-down projections from the brainstem (superior olivary nucleus), and may be disinhibited in patients with lesions of central auditory pathways resulting in ‘ringing cochlear microphonics.’

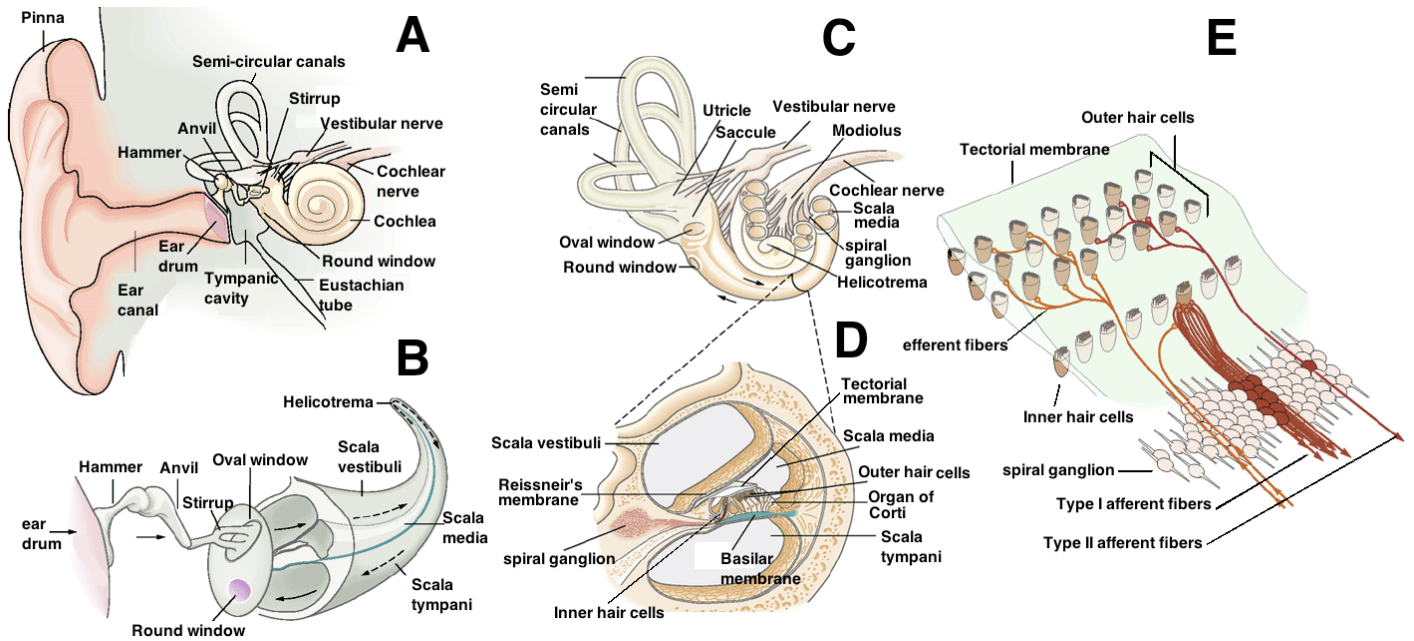


Figure 1. A: The peripheral auditory system is depicted from a coronal view. The peripheral auditory system is divided into the outer, middle and inner ear. The outer ear includes the pinna and ear canal. The middle ear includes the eardrum, eustachian tube and tympanic cavity. In the tympanic cavity are three bones (hammer, anvil and stirrup), which form a bridge between the eardrum and the cochlea of the inner ear. B: The inner ear includes the cochlea and vestibular apparatus (semi-circular canals, utricle and saccule). C: Sounds result with the eardrum folding and unfolding at different frequencies. The bones of the middle ear relay and amplify the mechanical movements of the eardrum. The stirrup bone of the middle ear is attached to the oval window of the inner ear. The mechanical movement of the stirrup bone and oval window causes a wave in the perilymphatic

liquid of the scala vestibuli (arrows). The wave proceeds into the scala tympani via the helicotrema. The wave terminates in the folding and unfolding of the round window. Because of a gradient in the width and flexibility of the basilar membrane, the location in the cochlea of the maximal amplitude of the standing wave displacing it is determined by the frequency of the sound wave. Hence there is a tonotopic gradient such that higher frequencies elicit maximal displacement (and hence hair cell discharges) nearest the oval window and lower frequency sounds displace the basilar membrane further toward the helicotrema. D: The sub-figure shows a cut through a segment of the cochlea. Between the scala media and scala tympani is the basilar membrane. On the basilar membrane is the organ of Corti. This structure is composed of sensory cells, called hair cells. On the tip of the hair cells are stereocilia that are attached to the tectorial membrane. Displacement of the basilar membrane result in movement of the stereocilia and depolarization of the hair cells. The hair cells synapse with the fibers of the spiral ganglion. E: A view of the organ of Corti. Each type II fiber synapses with several outer hair cells. Each inner hair cell synapses with 6-8 type I cochlear nerve fibers. The fibers of the spiral ganglion terminate in the cochlear nucleus in the brainstem. The cochlear nerve also contain efferent fibers the emerge from the superior olivary complex and terminate on the outer hair cells and type I fibers. The figure was modified from Kandel, E. R., Schwartz, J. H., & Jessell, T. M. (2006). Principles of Neural Science, chapter 30.

2.1.2 The sub-cortical auditory system:

The earliest auditory centers of the central nervous system are the ventral and dorsal cochlear nuclei (Fig. 2A,B). The ventral cochlear nucleus is located on the ventro-lateral surface of the inferior cerebellar peduncle. Soon after entering the cochlear nucleus, the axons of the cochlear nerve bifurcate into anterior and posterior branches (Moore and Osen 1979; Terr and Edgerton 1985; Adams 1986). Axons that relay low frequencies bifurcate closer to the point of entry of the nerve, whereas axons that relay higher frequencies bifurcate at a more distal, dorsal location. Animal studies analyzing the neural discharge of cochlear nucleus cells reported initial extraction of acoustic properties, such as sound onset, amplitude and pitch (Pfeifer, 1966; Rhode and Greenberg, 1994; Wiegrebe and Winter, 2001). Studies that followed fiber degeneration as a result of lesion to the cochlear nuclei reported that the cochlear nucleus sends projections to the ipsilateral and contralateral superior olivary nucleus and to the inferior colliculus (Warr, 1966; Strominger, 1977). The ipsilateral connections travel through an ascending fiber group called the lateral lemniscus. The contralateral projections travel via two stria: the ventral and intermediate acoustic stria. The ventral acoustic stria (i.e., the trapezoid body) crosses the ventral pontine tegmentum (immediately dorsal to the descending corticospinal fibers), and terminates in the contralateral superior olivary nucleus. The smaller intermediate cochlear stria crosses the brainstem at its core and joins the contralateral lateral lemniscus en route to the contralateral inferior colliculus. The dorsal cochlear nucleus is located on the inferior cerebellar peduncle, dorsal to the ventral cochlear nucleus. The dorsal cochlear nucleus projects to the contralateral superior olive via the dorsal acoustic stria, which is a fiber group that crosses the dorsal pontine tegmentum (immediately ventral to the 4th ventricle). Some of the fibers of the dorsal acoustic stria ascend via the lateral lemniscus to the contralateral inferior colliculus. Patients with unilateral damage to the cochlear nucleus suffer from unilateral deafness in the same ear, and patients with bilateral cochlear nuclei damage suffer from severe bilateral hearing loss or deafness (Hausler & Levine, 2000; Dix & Hood, 1973).

The second auditory center is the superior olivary complex (Fig. 2A,B). This complex is located in the lower pons, between the ascending fibers of the somato-sensory system, the medial lemniscus, and spino-thalamic tract. This complex includes a medial and a lateral nuclei and surrounding periolivary neurons. The cochleotopic organization is maintained in the olivary complex, with low frequencies encoded primarily in the medial olivary nucleus, and high frequencies in the lateral olivary nucleus. Each cochlear nucleus sends inhibitory projections to the ipsilateral lateral olivary nucleus, and via the ventral acoustic stria (trapezoid body) sends excitatory afferents to the contralateral medial olivary nucleus (Warr, 1966; Strominger, 1977). After their emergence from the cochlear nucleus, some of the fibers terminate in a group of cells interspersed in the ventral acoustic stria (nucleus of trapezoid body). This nucleus sends inhibitory afferents to the contralateral lateral olivary nucleus. Studies that compared animals with lesions above and below the superior olive demonstrated that the superior olive processes the spatial origin of sounds (Yin and Chan, 1990; Casseday and Neff, 1975; Jenkins and Masterton, 1982). The medial and lateral olivary nuclei estimate sound location by calculating the inter-ear latency and inter-ear amplitude interval, respectively. Accordingly, human patients with pontine damage are inaccurate in localizing sounds (Aharonson et al., 1998; Furst et al., 1995; Pratt et al., 1998). Furthermore, two case studies of human patients with a midline brainstem lesion (i.e., damage to the ventral acoustic stria), which bilaterally disconnected each superior olive from its contralateral cochlear nucleus, were reported impaired in sound localization, but had no other auditory impairments (Hausler & Levine, 2000-case 1; Griffiths et al., 1997a). Taken together, these findings suggest that the superior olivary complex is primarily responsible for auditory localization. A second role of the superior olivary complex is in mediating the stapedius reflex. When hearing very loud sounds, the superior olive transmits this information to the facial nucleus. The facial nucleus

in turn projects to the stapedius muscle of the middle ear for reducing sound amplification. Abnormal or absent stapedius reflex is therefore a marker of pontine damage.

The third auditory center, the inferior colliculus (IC), is a small protrusion of the tectum of the lower midbrain (Fig. 2A,B). The two IC are located near each other and are reciprocally connected via a specialized commissure (Moore and Goldberg, 1966; Brunso-Bechtold et al., 1983). The IC is composed of three parts: a central nucleus, a lateral cortex and a dorsal cortex (Geniec and Morest, 1971; Huffman and Henson, 1990; Morest and Oliver, 1984; Noort, 1963). The central nucleus of IC receives its afferents from the ipsilateral superior olive, as well as from the ipsilateral and contralateral cochlear nuclei, via the lateral lemniscus (Adams, 1979; Brunso-Bechtold et al., 1983). Some of the fibers of the lateral lemniscus synapse on scattered neurons located in the lateral lemniscus (dorsal and ventral nuclei of the lateral lemniscus), which send inhibitory afferents to the contralateral IC (Fig. 2B; Merchán and Berbel, 1996; Merchán and Saldana, 1994). Like earlier auditory structures, the central nucleus of IC is organized in a cochleotopic manner, with low frequencies encoded in its dorsolateral region, and high frequencies in its ventromedial region (Saldana and Merchan, 1992). In contrast to the central nucleus of IC, the lateral and dorsal cortices of IC lack cochleotopic organization and their function is as yet unclear. All three compartments of the IC receive direct descending projections from the auditory cortex (Saldana et al., 1996). Recordings from the IC of cats demonstrated that most IC neurons encode sound locations (Delgutte et al., 1999). The IC therefore integrates the different localization cues that are generated by independent neural populations in the superior olive. The IC then mediates the shifting of gaze toward the origin of the sound by projecting fibers to the deep layers of the superior colliculi (Moore and Goldberg, 1966; Edwards et al., 1979; Hartline et al., 1995). The IC, in addition to spatial processing, is also selective to changes in frequency over time (i.e., frequency modulated sweeps; Williams and Fuzessery, 2010), and to detection of sounds that

deviate in frequency from pre-heard patterns (i.e., stimulus-specific adaptation; Ayala and Malmierca, 2012). EEG recordings in humans suggests that the IC is also capable of discriminating sounds by their fundamental frequency, an acoustic parameter that is critical for voice recognition (Kraus and Nicole, 2005). Patients with unilateral damage to the IC have no hearing impairments or only suffer from mild hearing loss, whereas human patients with bilateral IC damage suffer from AA or deafness (see Appendix A for a summary of the literature on patients with IC lesions).

The fourth auditory center, the medial geniculate nucleus (MGN), is a small protrusion on the posterior thalamus, located between the lateral geniculate nucleus and pulvinar (Fig. 2A, B). The MGN is composed of ventral, dorsal and medial nuclei (Winer, 1984). Electrophysiological recordings and neuroanatomical analysis of the MGN of cats indicates that only the ventral MGN receives afferents from the central nucleus of IC and retains its cochleotopic organization (Morest, 1965; Calford, 1983). Higher frequencies are encoded medially and lower frequencies are encoded laterally. The dorsal and medial MGN receive their afferents from the cortex of IC and thus have no cochleotopic organization. The MGN receives its IC afferents via the brachium of IC (Moore and Goldberg, 1966). The MGN projects to the auditory cortex via another fiber group called the auditory radiations (Poliak, 1932; Rademacher et al., 2002; la Mothe et al., 2006b). A study that recorded neural activity in the IC, MGN and auditory cortex of the cat reported that the MGN is the earliest region to suppress masking noise, and thus facilitates auditory acuity (Las et al., 2005). In addition to relaying sensory input to the cortex, like most thalamic nuclei, the MGN is thought to modulate cortical processing via cortico-thalamic-cortical connections (Yvert et al., 2002; Sherman, 2012). This connectivity is consistent with an fMRI study that reported MGN activation during speech perception (Kriegstein et al., 2008). In humans, thalamic damage was shown to result in AA (Hayashi and Hayashi, 2007; Kaga et al., 2000; Karibe et al., 2000; Lhermitte et al.,

1972; Motomura et al., 1986; Takahashi et al., 1992; Shivashankar et al., 2001; Shindo et al., 1991-case 4) or aphasia (Naeser et al., 1982).

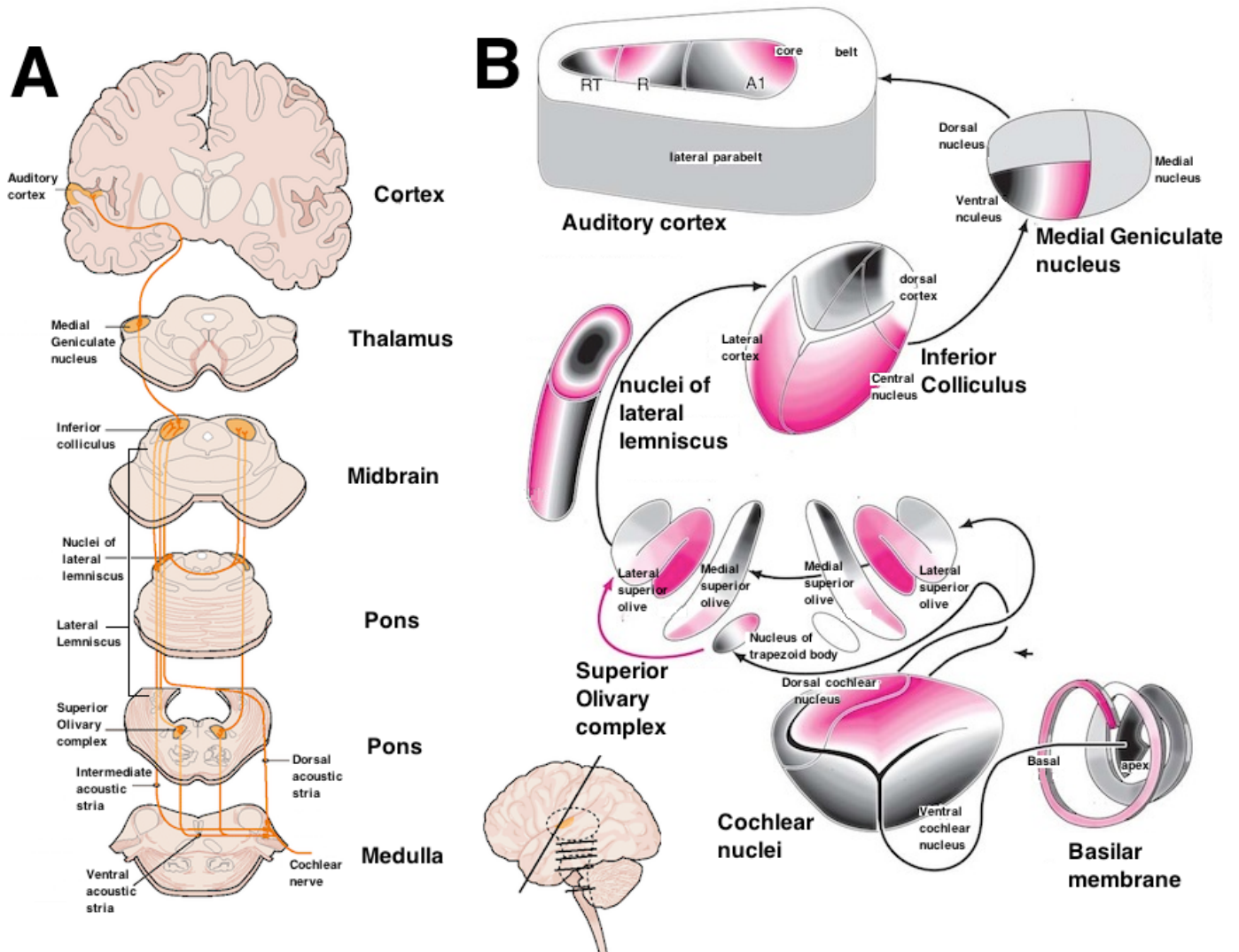


Figure 2. Schematic depiction of the central auditory system. In the left sub-figure (A), connectivity is shown between the auditory centers. In the right sub-figure (B), the sub-nuclei and cochleotopic organization of each auditory center is displayed (red-high frequency, black-low frequency). Description of this figure is provided throughout section 2.1.2. Sub-figure A was modified from Nieuwenhuys, R., Voogd, J., Voogd, J., van Huijzen, C., & van Huijzen, C. (2008). *The human central nervous system*. Springer Verlag, chapter 18. Sub-figure B was modified from Kandel, E. R., Schwartz, J. H., & Jessell, T. M. (2006). *Principles of Neural Science*, chapter

2.1.3 The auditory cortex:

The last auditory center is the auditory cortex. This auditory center is divided into primary and associative territories. Retrograde tracing techniques and histological staining studies in monkeys demonstrated the existence of two auditory fields that receive direct afferents from the ventral nucleus of MGN, and are therefore considered primary regions (Jones, 2003; Hackett et al., 2001; la Mothe et al., 2006b, 2012a). Electrophysiological recordings and functional imaging of monkeys further demonstrated that each of these primary auditory fields has its own cochleotopic gradient (Fig. 2B; Fig. 3 top-left ; Bendor and Wang, 2008; Bieser and Müller-Preuss, 1996; Chiry et al., 2003; Kusmirek and Rauschecker, 2009; Merzenich and Brugge, 1973; Morel and Kaas, 1992; Morel et al., 1993; Rauschecker et al., 1995; Recanzone et al., 2000; Petkov et al., 2006; Woods et al., 2006; Yin et al., 2008). In the most caudal region, A1, high frequencies are represented caudally, while low frequencies are represented rostrally. In area R, located rostral to A1, low frequencies are represented caudally while high frequencies are represented rostrally. The use of cochleotopic mapping in these studies also suggested the existence of a third primary auditory field, area RT, which is located rostral to area R (Fig. 2B; Fig. 3 top-left). However, it is unclear at this point whether area RT receives direct projections from the ventral MGN (Morel and Kaas., 1992; Hackett et al., 2001), and thus it is uncertain whether area RT is a true primary region.

In humans, studies using different post-mortem staining techniques reported that Heschl's gyrus is the main recipient of primary thalamic projections (i.e., the area with the most developed cortical layer 4), and on that account concluded that Heschl's gyrus is the primary auditory cortex (HG in Fig. 3 top-right; Brodmann, 1909, Von Economo and Koskinas, 1925; Galaburda and Sanides., 1980; Morosan et al., 2001; Wallace et al., 2002; Fullerton and Pandya, 2007). Evidence also suggests that the parcellation of Heschl's gyrus into auditory fields is similar to the one reported for monkeys. Post-mortem histological staining in humans demonstrated the exist-

tence of two primary auditory fields, located along the posterior and anterior banks of Heschl's gyrus (Sweet et al., 2005; Wallace et al., 2002). Functional imaging studies further reported similar cochleotopic gradients in the anterior and posterior primary auditory fields in humans and monkeys (Da Costa et al. 2011; Humphries et al. 2010; Langers & van Dijk, 2012; Striem-Amit et al. 2011; Woods et al. 2010). These researchers proposed homology between the monkey and human anterior primary auditory fields (monkey area R and human area hR), and homology between the monkey and human posterior primary auditory fields (monkey area A1 and human area hA1).

Outside of the primary auditory fields (core territory), tracing and histological staining studies further divided the associative auditory fields into two territories: belt and parabelt (Fig. 2B, Fig. 3; Kaas and Hackett, 2000). The belt territory surrounds the primary auditory fields laterally and medially and receive direct projections from them (Morel et al., 1993; la Mothe et al., 2006a; 2012b). The parabelt auditory fields are located on the lateral surface of the superior temporal gyrus, lateral to the lateral auditory belt fields, and receive its projections from belt territory (la Mothe et al., 2012b). In contrast to the selectivity of the primary auditory fields to pure tones, the associative auditory fields are more selective to broad band noise (Rauschecker et al., 1995). Functional imaging and electrophysiological recordings from the belt auditory fields demonstrated the existence of eight auditory belt fields. Each core auditory field was shown to have the same cochleotopic gradient as the belt auditory fields that are immediately lateral and medial to it (Kusmieriek and Rauschecker, 2009; Petkov et al., 2006; Rauschecker et al., 1995). In addition to the separation of the associative auditory fields into belt and parabelt, studies using histological staining and tracing techniques dissociated the associative auditory fields into anterior and posterior regions (Morel et al. 1993; la Mothe et al., 2006a, 2012b). The anterior primary auditory fields (Fig. 3 top - dark red) were shown to project to the anterior belt auditory fields (Fig. 3 - light red),

and the posterior primary auditory field (Fig. 3 top - dark blue) projects to the posterior belt auditory fields (Fig. 3 top - light blue). The anterior belt was also shown to project to the anterior parabelt and the posterior belt to the posterior parabelt (la Mothe et al., 2012).

The anterior-posterior dissociation of the auditory cortex continues beyond the auditory cortex. Studies using anterograde tracing techniques showed that the anterior belt/parabelt regions project to the amygdala (Kosmal, 1997) and to the ventrolateral prefrontal cortex (Munoz et al., 2009; Romanski et al., 1999). Other anterograde tracing studies reported projections from the posterior belt/parabelt to the dorsolateral prefrontal cortex (Cusick et al. 1995; Romanski et al. 1999). Retrograde and anterograde tracing studies and electrophysiological recordings from the intraparietal sulcus further demonstrated that this region serves as an intermediate relay station between the caudal belt/parabelt and the dorsolateral prefrontal cortex (Deacon, 1992; Lewis and Van Essen, 2000; Roberts et al. 2007; Schmahmann et al. 2007; Seltzer & Pandya, 1984). The pathway connecting the rostral auditory cortex with the ventrolateral prefrontal cortex has been designated as the auditory ventral stream (Fig. 3 bottom - red arrows), and the pathway connecting the caudal auditory cortex with the dorsolateral prefrontal cortex as the auditory dorsal stream (Fig. 3 bottom - blue arrows).

There is also some evidence for dissociation of the auditory cortex into ventral and dorsal streams in humans. Electrophysiological studies that recorded neural activity directly from within the human auditory cortex reported connectivity between posterior Heschl's gyrus (area hA1) and the posterior belt areas (posterior superior temporal gyrus-planum temporale; pSTG-PT), and between anterior Heschl's gyrus (area hR) and the anterior belt areas (anterior superior temporal gyrus; aSTG; Gourévitch et al. 2008; Guéguin et al. 2007). Human studies using diffusion tensor tractography further demonstrated connectivity between the aSTG and the ventrolateral

prefrontal cortex, and connectivity between the pSTG-PT and the dorsolateral prefrontal cortex (Frey et al., 2008; Saur et al. 2008; Turken and Dronkers, 2011). Connectivity was also reported between the posterior auditory cortex and the inferior parietal region, and from there to the dorsolateral prefrontal cortex (Catani et al., 2004).

Functional studies corroborate the dissociation of the auditory cortex into anterior segment (part of the auditory ventral stream) and posterior segment (part of the auditory dorsal stream). Recorded neural activity from the posterior auditory cortex of monkeys showed that the strongest selectivity to changes in sound location occurs in the posterior belt fields, intermediate selectivity in primary area A1, and very weak selectivity in the anterior auditory fields (Benson et al., 1981; Rauschecker et al., 1995; Woods et al., 2006; Miller and Recanzone, 2009). Similarly, functional imaging studies in humans that contrasted sound discrimination and sound localization demonstrated that sound localization is associated with activation in the pSTG and PT, whereas sound discrimination is processed more anteriorly (Ahveninen et al. 2006; Alain et al., 2001; Barrett and Hall, 2006; De Santis et al. 2006; Hart et al. 2004; Maeder et al., 2001; Viceic et al., 2006; Warren et al., 2002; Warren and Griffiths, 2003). Some fMRI studies further reported that the activation in the pSTG and inferior parietal lobule increased when individuals perceived sounds in motion (Baumgart et al. 1999; Krumbholz et al. 2005; Pavani et al., 2002). EEG studies using source-localization also identified the pSTG as the region that processes sound localization (Tata et al., 2005a, 2005b). A combined fMRI and MEG study corroborated the role of the auditory dorsal stream with audio-spatial processing by demonstrating that changes in sound location results in activation spreading from Heschl's gyrus posteriorly along the pSTG and terminates in the inferior parietal lobule (Brunetti et al., 2005).

In humans, in addition to sound localization, the posterior auditory cortex and inferior parietal lobule of the left hemisphere are also involved in the articulation of speech. This has been demonstrated in studies that reported enunciation errors during object naming (phonological paraphasia) when the inferior parietal lobule is damaged (Schwartz et al., 2012) or electro-stimulated (Corina et al. 2010; Duffau et al., 2008). Damage to the left temporo-parietal junction is also associated with a deficit of speech repetition (conduction aphasia; Axer et al. 2001; Buchsbaum et al., 2011). Functional imaging studies also reported that the left temporo-parietal junction is active both during speech perception and speech production (Buchsbaum et al. 2001; Hickok & Poeppel, 2003; Warren et al., 2005; Wise et al. 2001). These findings were interpreted as evidence that the auditory dorsal pathway of the left hemisphere is dedicated for converting perceived speech into articulations (Hickok & Poeppel, 2007; Warren et al., 2005). This role of the auditory dorsal stream was corroborated by intra-cortical recording (Towle et al., 2008) and fMRI studies (Giraud & Price, 2001; Graves et al. 2008; Karbe et al. 1998) that reported activation in this area during speech repetition.

In contrast to the roles of the auditory dorsal stream in audio-spatial processing and speech production, cumulative converging evidence indicates that the auditory ventral stream of both monkeys and humans is responsible for sound recognition. In the primary auditory fields, recordings from monkeys showed higher percentage of neurons selective for learned melodic sequences in area R than area A1 (Yin et al., 2008). In humans, recording directly from within Heschl's gyrus demonstrated that anterior Heschl's gyrus (area hR) is more selective for heard syllables than posterior Heschl's gyrus (area hA1; Steinschneider et al., 2004). In downstream belt auditory fields, studies from both monkeys and humans reported that the border between the anterior and posterior auditory fields (Fig. 3 -area PC in the monkey and mSTG in the human) processes pitch attributes that are necessary for the recognition of sounds (Bendor and Wang, 2006). Functional imaging of monkeys (Joly et al.,

2012; Petkov et al., 2008; Poremba et al., 2004) and studies that recorded neural discharge from the monkey auditory cortex (Rauschecker et al., 1995; Perrodin et al., 2011; Russ et al., 2007) reported that neurons in the anterior auditory cortex are capable of discriminating con-specific vocalizations. One fMRI monkey study further showed that the anterior auditory cortex discriminates between pack members, and thus is capable of voice detection (Petkov et al., 2008). The role of the human anterior auditory cortex in sound recognition was demonstrated in functional imaging studies that showed activation increase in this region during tasks that require recognition of spoken words (Binder et al., 2004; Davis & Johnsrude, 2003; Liebenthal, 2005; Narain, 2003; Obleser et al. 2006a; 2006b; Scott et al. 2000), voices (Belin, 2003), melodies (Leaver and Rauschecker, 2010; Benson et al., 2001) and environmental sounds (Lewis et al., 2006; Maeder et al., 2001; Viceic et al., 2006). Intra-cortical recordings from the left aSTG and pSTG of epileptic patients demonstrated that only the aSTG is more responsive when the patient hears native speech than when listening to unknown foreign spoken words (Lachaux et al., 2007). Electro-stimulation of the aSTG, but not pSTG, resulted in impaired speech comprehension (Lachaux et al., 2007; Matsumoto et al., 2011). In humans, downstream to the anterior auditory cortex, temporal pole damage (e.g., semantic dementia, herpes simplex virus encephalitis, stroke) was associated with audio-visual loss of semantic knowledge (Schwartz et al., 2009; Noppeney et al., 2006; Patterson et al., 2007; Turken and Dronkers, 2011). This region is thought to encode the semantic lexicon, where sounds are matched with their meaning (Gow, 2012).

In the auditory dorsal pathway, speech repetition and production is processed primarily in the left hemisphere. However, studies that isolated the right and left hemispheres with the WADA procedure (i.e., unilateral hemispheric anesthesia) demonstrated that sound recognition occurs in both hemispheres (Hickok et al., 2008). This was also shown in a study that recorded directly from the auditory cortices of epileptic patients, and showed that

the auditory cortices of both hemispheres were responsive to spoken words (Creutzfeldt et al. 1989). Experiments investigating sound recognition in split brain patients showed that sound recognition occurs in both hemispheres, but with the right hemispheres having a smaller vocabulary (Zaidel, 1976). Similar results were also obtained in non-human primates, since monkeys with extensive unilateral lesion to the auditory cortex were shown to lose the ability to recognize sounds only after a second circumscribed lesion to the anterior auditory cortex, but not to the posterior auditory cortex, of the other hemisphere (Harrington and Heffner, 2002). In the majority of AA reports, the agnosic symptoms manifested in patients with bilateral damage to the auditory cortices, or the underlying white matter (Poeppel, 2001, 2012; Ulrich, 1978; Appendix B). This bilateral requirement for AA led researchers to propose that this disorder is the result of bilateral disruption of the auditory ventral streams (Hickok & Poeppel, 2007).

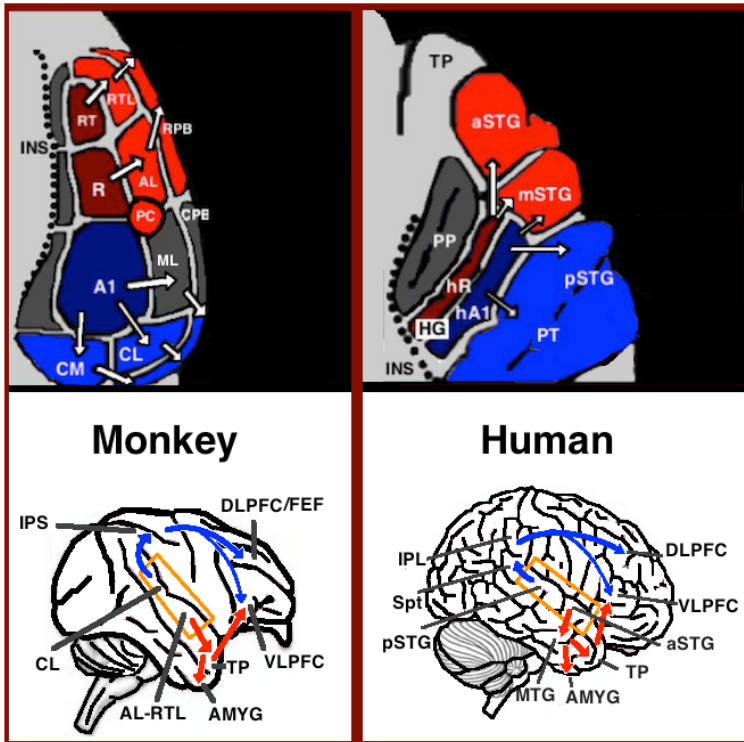


Figure 3. Top: The auditory cortex of the monkey (left) and human (right) is schematically depicted on the supratemporal plane and viewed from above (with the parieto-frontal operculi removed). Bottom: The brains of the monkey (left) and human (right) are schematically depicted and displayed from the side. Orange frames mark the region of the auditory cortex, which is displayed in the top sub-figures. Top and Bottom: Blue colors mark regions affiliated with the auditory dorsal stream and red colors mark regions affiliated with the auditory ventral stream (dark red and blue mark the primary auditory fields). Abbreviations: AMYG-amygdala, HG-Heschl's gyrus, FEF-frontal eye field, INS-insula, IPS-intra parietal sulcus, MTG-middle temporal gyrus, PC-pitch center, PP-planum polare, PT-planum temporale, TP-temporal pole, Spt-sylvian parieto-temporal, DLPFC/VLPFC- dorsolateral/ventrolateral prefrontal cortex, pSTG/mSTG/aSTG-posterior/middle/anterior superior temporal gyrus, CL/ML/AL/RTL-caudo-/middle-/antero-/rostrottemporal-lateral belt area, CPB/RPB-caudal/rostral parabelt fields.

2.1.4 Electrophysiological Recordings in the Human Auditory System:

Processing of sounds in the central auditory system has been assessed with EEG recordings. In this method an electrode net is placed on the scalp. The electrodes record neural discharge from the brain with high temporal accuracy. Processing of sounds at different auditory centers results in a series of electrical peaks (Fig. 4). During the first 10 milliseconds post sound onset, far-field recorded electrical discharge are recorded by volume conduction from the brainstem and thalamus (i.e., brainstem auditory evoked potentials). During the period 10-70 milliseconds post sound onset, the recorded electrical discharge is emitted from the thalamus and primary auditory cortex (i.e., middle latency evoked potentials). Electrical discharge recorded after 70 milliseconds is the result of processing in associative auditory cortical fields and downstream cortical regions (i.e., long latency evoked potentials).

In healthy people, seven peaks (known as waves) are recorded during the first 10 milliseconds post sound onset (i.e., auditory brainstem evoked potentials). Studies of brain damage patients that correlated lesion location with EEG activity suggested that every wave signifies auditory processing in a different auditory center (Allen and Starr, 1978; Stockard et al. 1978, 1986; Moller and Jannetta 1982; Scherg and von Cramon 1985). Waves I and II are generated in the cochlear nerve and cochlear nucleus. Wave III is generated in the ventral acoustic stria (between the cochlear nucleus and superior olivary complex). Wave IV is generated in the bend of axons that emerges from the superior olive, prior to entering the lateral lemniscus. Wave V is generated in the vicinity of IC (Fischer et al., 1994). Waves VI and VII are generated in the thalamus and auditory radiations (Black et al., 1979; Nishioka et al., 1993).

In healthy people, during the period 10 to 70 milliseconds, five positive and negative peaks are observed (middle latency evoked potentials). Peaks begin with 'P' or 'N' referring to a waveform on the scalp with a positive or negative polarity, respectively. A study correlating lesion location and EEG activity suggested that the first two peaks, P0 and Na, are generated in the thalamus, and the latter three peaks, Pa, Nb, P1, are generated in the cortex (Kaseda et al., 2012; Kraus et al., 1982; Shehata-Dieler et al., 1991). This localization is also supported by a study that recorded neural discharge directly from the auditory cortex of epileptic patients, and correlated the middle latency responses with neural discharge from Heschl's gyrus (Liégeois-Chauvel et al., 1994). This study also correlated electrical peaks generated after 70 millisecond (long latency evoked potentials), with neural discharge in the pSTG (other auditory cortical fields were not examined). The long latency evoked potentials refer to three electrical peaks, N1, P2 and N2. It is interesting to note that so far no correlation was found between the severity of auditory impairment in AA patients (as well as related disorders such as cerebral deafness) and the absence or presence of specific middle and long latency evoked potentials (Woods et al., 1987; Tanaka et al., 1991).

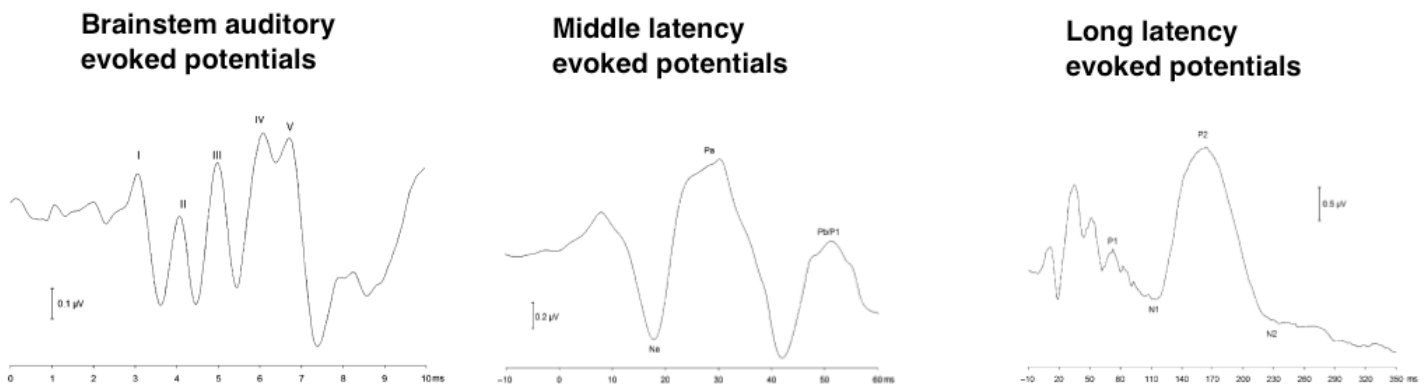


Figure 4. The functionality of the central auditory system examined with EEG. Three types of waves have been recorded to localize lesion of the auditory pathways. 'Far field' (volume conducted) brainstem auditory evoked potentials are recorded in the first 10 milliseconds post sound onset, middle latency evoked potentials between

10-70 milliseconds post sound onset, and long latency evoked potentials between 70-500 milliseconds post sound onset. The brain stem auditory evoked potentials are emitted from brain stem regions. The middle latency evoked potentials are emitted from the thalamus and primary auditory cortex. The long latency evoked potentials are emitted from associative cortical regions, and downstream cortical regions outside the auditory cortex.

2.2 Auditory agnosia - History:

A relationship between hearing and the brain was first documented by Ambroise Paré, a 16th century battlefield doctor, who associated parietal lobe damage with acquired deafness (reported in Henschen, 1918). Systematic research into the manner in which the brain processes sounds, however, only began toward the end of the 19th century. At that time the only tool for studying auditory cortex, was the careful examination of the symptoms of brain-damaged patients with auditory impairments. The focus of these studies was on identifying the connectivity between the right and left primary auditory cortices and an auditory region dedicated for processing spoken words. It was under the context of this early research that AA was discovered and studied.

In his seminal research of brain-damaged patients, Wernicke (1874) was the first to ascribe to a brain region a role in auditory perception. Wernicke proposed that the impaired perception of language in his patients was due to losing the ability to register sound frequencies that are specific to spoken words. Wernicke also suggested that other aphasic symptoms, such as speaking, reading and writing errors occur because these speech specific frequencies are required for feedback. Wernicke localized the perception of spoken words to the posterior half of the left STG. Wernicke also distinguished between patients with this disorder (which he labels as receptive aphasia) with patients who cannot detect sound at any frequency (which he labels as cortical deafness; Wernicke and Friedlander, 1883).

In 1877, Kussamul was the first to report AA in a patient with intact hearing, speaking, and reading-writing abilities. This case-study led Kussamul to propose of distinction between the word perception deficit and Wernicke's sensory aphasia. He coined the former disorder as "word deafness". Kussamul also localized this disorder

der to the left STG. Wernicke interpreted Kussamul's case as an incomplete variant of his sensory aphasia (Wernicke and Freidlander, 1883).

In 1885, Lichtheim also reported of an AA patient. This patient, in addition to word deafness, was impaired at recognizing environmental sounds and melodies. Based on this case study, as well as other aphasic patients, Lichtheim proposed that the language reception center receives afferents from upstream auditory and visual word recognition centers, and that damage to these regions results in word deafness or word blindness (i.e., alexia), respectively (Figure 5). Because the lesion of Lichtheim's AA patient was sub-cortical deep to the posterior STG, Lichtheim renamed AA as "sub-cortical speech deafness".

The language model proposed by Wernicke and Lichtheim wasn't accepted at first. For example, Bastian (1897) argued that, because aphasic patients can repeat single words, their deficit is in the extraction of meaning from words. He attributed both aphasia and AA to damage in Lichtheim's auditory word center. He hypothesized that aphasia is the outcome of partial damage to the left auditory word center, whereas AA is the result of complete damage to the same area. Bastian localized the auditory word center to the posterior MTG.

Other opponents to the Wernicke-Lichtheim model were Sigmund Freud and Carl Freund. Freud (1891) suspected that the auditory deficits in aphasic patients was due to a secondary lesion to cochlea. This assertion was confirmed by Freund (1895), who reported two AA patients with cochlear damage (although in a later autopsy, Freund reported also the presence of a tumor in the left STG in one of these patients). This argument, however, was refuted by Bonvicini, who measured the hearing of an AA patient with tuning forks, and confirmed intact pure tone perception (Bonvicini, 1905). Similarly, Barrett's aphasic patient, who was incapable of comprehend-

ing speech, had intact hearing thresholds when examined with tuning forks and with a Galton whistle (Barrett, 1910).

The most adverse opponent to the model of Wernicke and Lichtheim was Marie (1906), who argued that all aphasic symptoms manifest because of a single lesion to the language reception center, and that other symptoms such as auditory disturbances or paraphasia are expressed because the lesion encompasses also sub-cortical motor or sensory regions.

In the following years, increasing number of clinical reports validated the view that the right and left auditory cortices project to a language reception center located in the posterior half of the left STG, and thus established the Wernicke-Lichtheim model. Liepmann and Storch (Liepmann, 1898; Liepmann and Storch, 1902) reported an AA patient with left sub-cortical damage that appeared to sever both right and left afferents to the left language reception center. A similar lesion was also described in an autopsy of one of Wernicke's patients (Liepmann, 1912). This language processing model, and its understanding for the etiology of word deafness was further corroborated by autopsy reports of aphasic patients with AA symptoms, who were demonstrated to have had extensive unilateral left white matter damage (Van Geuchten and Goris, 1910; Potzl, 1919; Hennenberg, 1926; Henschen, 1920; Schuster and Taterka, 1926; Kleist, 1934) or bilateral cortical superior temporal lobe damage (Giraudeau, 1882; Pick, 1892; Dejerine and Serieux, 1898; Ballet, 1903; Bonvicini, 1905; Barrett, 1910; Henschen, 1918, 1920). This view was also consolidated by Geschwind (1965) who reported that, in humans, the left planum temporale is larger in the left hemisphere than on the right. Geschwind interpreted this asymmetry as anatomical verification for the role of left posterior STG in the perception of language.

The Wernicke-Lichtheim-Geschwind model persisted throughout the 20th century. However, with the advent of MRI and its usage for lesion mapping, it was shown that this model is based on incorrect correlation between symptoms and lesions (Dronkers et al. 1999; Dronkers, 2000; Dronkers et al., 2004; Poeppel et al., 2012; Rauschecker & Scott, 2009 - Supplemental Material). Although this model is considered outdated, it is still widely mentioned in Psychology and medical textbooks, and consequently in medical reports of AA patients. As mentioned earlier, based on cumulative evidence the process of sound recognition was shifted to the left and right anterior auditory cortices, instead of the left posterior auditory cortex.

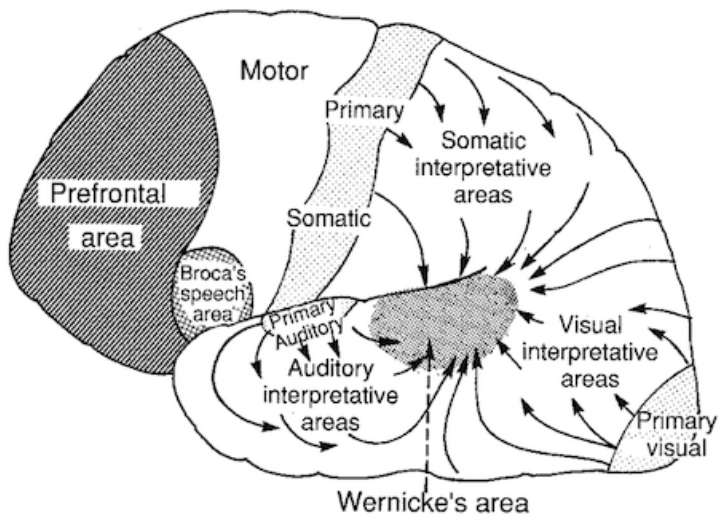


Figure 5 Schematic depiction of the Wernicke-Lichtheim-Geschwind model. The somatosensory, auditory and visual cortices analyze the sensory properties of verbal material (speech, text, Braille). The sensory cortices of both hemispheres project this input to Wernicke's area in the left hemisphere. Wernicke's area then extracts the linguistic properties of this input, and projects it downstream to Broca's area. Broca's area then processes grammatical structure and speech output. In the context of this model, auditory agnosia occurs because of cortical damage to both auditory cortices (bilateral damage), or damage to the fibers that connect the auditory cortices with Wernicke's area (unilateral left damage). Figure taken from <http://www.acbrown.com/neuro/Lectures/Lang/NrLangSpch.htm>.

2.3 Auditory Agnosia and Related Disorders:

After AA was first discovered, subsequent patients were diagnosed with different types of hearing impairments. In some reports, the deficit was restricted to spoken words, environmental sounds or music. In one case study, each of the three sound types (music, environmental sounds, speech) was also shown to recover independently (Mendez and Geehan, 1988-case 2). It is yet unclear whether general AA is a combination of these three disorders, or whether the source of this disorder is at an earlier auditory processing stage. In the coming sections, I will present evidence for the existence of the three AA sub-types, and present two related disorders: word meaning deafness and cerebral deafness.

2.3.1 Cerebral Deafness:

Cerebral deafness (also known as cortical deafness or central deafness) is a disorder characterized by complete deafness that is the result of damage to the central nervous system. The primary distinction between AA and cerebral deafness is the ability to detect pure tones, as measured with pure tone audiometry. Using this test, AA patients were often reported capable of detecting pure tones almost as good as healthy individuals, whereas cerebral deafness patients found this task almost impossible or they required very loud presentations of sounds (above 100dB; Vignolo et al., 1969; Tanaka et al., 1991). This distinction, however, is not always clear as on several occasions AA patients were diagnosed with moderate to severe hearing loss for a range of frequencies, which could be interpreted as partial deafness (low frequency loss: Takahashi et al., 1992; Wang et al., 2000; high frequencies loss: Jerger et al., 1972; Auerbach et al., 1982; Motomura et al., 1986; Tanaka et al., 1987; Yaqub et al., 1988; Praamstra et al., 1991). In all reported cases, cerebral deafness was associated with bilateral

temporal lobe lesions. A study that compared the lesions of two cerebral deafness patients to an AA patient concluded that cerebral deafness is the result of complete de-afferentation of the auditory cortices, whereas in AA some thalamo-cortical fibers are spared (Tanaka et al., 1991). In most cases the disorder is transient and the symptoms mitigate into AA (although chronic cases were reported; Polster and Rose, 1998). Similarly, a monkey study that ablated both auditory cortices of monkeys reported of deafness that lasted 1 week in all cases, and that was gradually mitigated into AA in a period of 3-7 weeks (Heffner and Heffner, 1990).

2.3.1 Pure Word Deafness:

Since the early days of aphasia research, the relationship between AA and speech perception has been debated. Lichtheim (1885), in his language model, proposed that AA is the result of damage to a brain area dedicated to the perception of spoken words. To mark the special role of spoken language in this disorder, Lichtheim re-named this disorder from ‘word deafness’ to ‘pure word deafness’. The description of word deafness as being exclusively for words was adopted by the scientific community despite the patient reported by Lichtheim’s who also had more general auditory deficits. Some researchers who surveyed the literature, however, argued against labeling this disorder as pure word deafness on the account that all patients reported impaired at perceiving spoken words were also noted with other auditory deficits or aphasic symptoms (Head, 1926; Weisenburg and McBride, 1935; Buchman et al., 1986). In one review of the literature, Ulrich (1978) presented evidence for separation of word deafness from more general AA, and suggested naming this disorder “linguistic auditory agnosia” (this name was later rephrased into “verbal auditory agnosia”; Wang et al., 2000). To contrast this disorder with AA in which speech repetition is intact (word meaning deafness), the name “word sound deafness” (Kohn & Friedman, 1986; Franklin, 1989) and “phonemic deafness” (Kleist, 1962) were also proposed.

Although some researchers argued against the purity of word deafness (Head, 1926; Wesenbug and McBride, 1935; Buchman et al., 1986), some anecdotal cases with exclusive impaired perception of speech were documented. Two early cases, that fit closely with the definition of pure word deafness, were reported by Mills (1891) and Ziehl (1896). Mill's patient was unable to comprehend speech or participate in conversations when not allowed to lip-read. Friends and family, however, reported that she was capable of hearing sounds and music of various kinds. In one instance, she was capable of calling attention to a band playing in the street, and in another she would go down from the second or third story of her building when hearing a knock on the door. She was also shown able to identify the sounds of a bell ringing and a clock ticking. Ziehl's patient was also severely impaired in word comprehension and repetition. This patient, however, was capable of identifying musical instruments, as well as identifying individuals by their voices.

Since the reports of Mills and Ziehl, several pure word deafness were documented. Hemphill and Stengel (1940) reported a patient who could not comprehend or repeat words, but could recognize and mimic melodies without hesitation. Klein and Harper (1956) described a patient who wasn't able to understand or repeat speech, but was easily able to identify environmental sounds. This patient was even capable of discriminating three such sounds when presented simultaneously. After a recovery period, he was also capable of recognizing voices and accents. Saffran et al (1976) reported a patient with unilateral left damage who was impaired in speech comprehension and repetition, but was capable of identifying environmental sounds, gender in voice, and whether a spoken language was foreign. Yaqub et al (1988) also reported a patient, who was unable to comprehend speech or discriminate words from nonsense words (although he was capable of writing to dictation 5 out of 10 words), but was able to recognize environmental sounds (e.g., animal sounds, keys, hand clapping, musical instruments). This patient was also found capable of discriminating emotional intonations (happy, sad, angry),

linguistic intonations (question, statement, command), gender (male, female) and accents (Arabic, non-Arabic). He also enjoyed listening to music, although was unable to comprehend the lyrics of songs. In one case, he even identified that a heard segment was from the Quran. Similar account was also presented by Takahashi et al (1992), who reported a patient who could identify environmental sounds melodies and voices without difficulty, and who was capable of matching the environmental sounds with their pictures. Atypically, he was incapable of perceiving emotional prosody. The patient of Tanaka et al (1987) was also incapable of comprehending or repeating spoken words, but easily named environmental sounds, or sorted sounds into categories (noise, speech, music). Finally, the patient of Wolmetz et al (2011) was shown to have an exclusive deficit for the comprehension and repetition of speech. This patient, however, was capable of discriminating other sounds (pure tones and frequency modulated tones).

In addition to the six most classic cases of pure word deafness, other researchers also diagnosed their patients as having this disorder. The diagnosis of pure word deafness in these cases, however, is problematic because the patients were only described in brief clinical reports, which either lack details or systematic testing (Brick et al., 1985; Coslett et al., 1984; Hausler and Levine, 2000-case 3; Hayashi and Hayashi, 2007; Kim et al., 2011; Okada et al., 1963; Mendez and Geehan-case 2; Shindo et al., 1991-case 4; Shivanshankar et al., 2001-2 patients; Wolberg et al., 1990), or, in other cases, the spared perception of environmental sounds was measured via an easier test than speech perception or with a different method (i.e., environmental sounds were measured with sound to picture matching, whereas speech deafness was diagnosed by assessing behavior, speech discrimination tests or other methods; Albert and Bear, 1974; Buchman et al., 1986; Maneta et al., 2001; Praamstra et al., 1991; Hamanaka et al., 1980; Otsuky et al., 1998; Metz-Lutz and Dahl, 1984; Stefanatos et al., 2005). In one

case, pure word deafness was diagnosed without even testing the perception of environmental sounds or music (Wang et al., 2000).

The veracity of pure word deafness has also been supported by reports of patients with impaired perception of non-verbal sounds, but to a different extent than the impaired perception of spoken words. For example, several patients were described with impaired recognition of melodies and speech, whereas the recognition of environmental sounds was either only mildly impaired or at normal levels (Anegawa et al., 1995; Buchman et al., 1986-patient 1; Coslett et al., 1984; Engelen et al., 1995-music perception not tested; Eustace et al., 1990-case 1; Kamei, 1981; Kanshepolky et al., 1973; Shoumaker, 1977; Auerbach, 1982; Kitayama, 1990; Koyama et al., 2007; Shindo et al., 1981; Tanaka et al., 1987; Wolberg et al., 1990). In other cases, the verbal and non-verbal deficits were reported, but where these two kinds of deficit were dissociated by their evolution during the course of illness. For example, Lizuka et al (2007) reported a frontotemporal dementia patient, who transitioned from a selective deficit of speech perception into general AA. Similarly, two patients with subcortical hemorrhages were first diagnosed as pure word deafness which later transitioned into general AA and eventually into cerebral deafness (Szirmai et al., 2002). Pinard et al (2002) reported a patient who suffered from dementia and, over a period of 10 years, transitioned from pure word deafness into general AA. Goldstein et al (1975) followed the convalescence course of an AA patient, and reported gradual improvement in her ability to identify environmental sounds and match them to pictures. After two years, her performance with environmental sounds was intact, yet she remained incapable of repeating spoken words. Zhu et al (2010) reported a patient, who in a period of thirty days, transitioned from deafness to general AA to pure word deafness.

In a review of the AA literature, Phillips and Farmer (1990) noted a dissociation between patients with relative sparing of environmental sounds (pure word deafness), and patients with more extensive deficits of auditory perception. They showed that patients with word deafness are impaired in their ability to discriminate short inter click intervals as long as 15-50 milliseconds, which is consistent with the duration of phonemes. They also showed that patients with general AA are impaired in their ability to discriminate inter click intervals as long as 100-300 milliseconds. The authors further showed that word deafness patients liken their auditory experience to hearing foreign language, whereas general AA described speech as incomprehensible noise. Based on these findings, and because both word deafness and general AA patients were reported to have very similar neuroanatomical damage (bilateral damage to the auditory cortices), the authors concluded that word deafness and general AA is the same disorder, but with a different degree of severity. This view, although consistent with several reports, fails to explain two cases with a severe and general auditory perception deficit, in which click fusion thresholds were almost intact (Chocholle et al., 1975; Kazui et al., 1990).

Pinard et al (2002) also suggested that pure word deafness and general AA represent different degrees of the same disorder. They suggested that environmental sounds are spared in the mild cases because they are easier to perceive than speech parts. They argued that environmental sounds are more distinct than speech sounds because they are more varied in their duration and loudness. They also proposed that environmental sounds are easier to perceive because they are composed of a repetitive pattern (e.g., the bark of a dog or the siren of the ambulance).

Auerbach et al (1982) considered word deafness and general AA as two separate disorders, and labelled general AA as pre-phonemic AA and word deafness as post-phonemic AA. They suggested that pre-phonemic AA mani-

manifests because of general damage to the auditory cortex of both hemispheres, and that post-phonemic AA manifests because of damage to a spoken word recognition center in the left hemisphere. His conclusion, however, is problematic because he based his diagnosis of post-phonemic AA on 2 case studies, in which no brain scan was reported, and therefore it is unknown whether the damage was bilateral or unilateral. Recent evidence, however, possibly verified Auerbach hypothesis, since an epileptic patient who undergone electro-stimulation to the anterior superior temporal gyrus was demonstrated a transient loss of speech comprehension, but with intact perception of environmental sounds and music (Matsumoto et al., 2011).

2.3.2 Auditory Agnosia for Environmental sounds:

The term auditory agnosia was originally coined by Freud (1891) to describe patients with selective impairment of environmental sounds. In a review of the AA literature, Ulrich (1978) re-named this disorder as non-verbal AA (although sound AA and environmental sound AA are also commonly used). This disorder is very rare and only a few cases have been documented (Albert et al., 1972; Baddeley and Wilson, 1993; Clarke et al., 2000; de la Sayette et al., 1994; Eustache et al., 1990-case 2; Habib et al., 1995; Fujii et al., 1990; Johannes et al., 1990; Lambert et al., 1989; Mazzucchi et al., 1992; Motomura et al., 1986; Nielsen and Sult, 1939; Saygin et al., 2010; Spreen, 1965; Tanaka et al., 2002; Taniwaki et al., 2000; Wortis and Pfeffer, 1948; Yamamoto et al., 2004). In contradiction to pure word deafness and general AA, this disorder is likely under-diagnosed because patients are often not aware of their disorder, and thus don't seek medical intervention (Saygin et al., 2010; Vignolo et al., 2003; Yamamoto et al., 2004), or it is tested with sound-picture matching test, which isn't a sensitive test for this disorder (e.g., Eustache et al., 1990-case 2).

Throughout the 20th century, all reported non-verbal AA patients had bilateral or right temporal lobe damage. For this reason, the right hemisphere was traditionally attributed with the perception of environmental sounds. Impaired recognition of environmental sounds, however, was also demonstrated in aphasic patients with unilateral left damage (Vignolo et al., 1982; Vignolo et al., 2003; Saygin et al., 2003; Schnider et al., 1994). Moreover, Tanaka et al (2002) reported 8 patients with non-verbal AA, 4 with right hemisphere lesion and 4 with left hemisphere lesions. Saygin et al (2010) also reported a patient with damage to the left auditory cortex.

The underlying deficit in non-verbal AA appears to be varied. Several patients were characterized by impaired discrimination of pitch (Johannes et al., 1990; Habib et al., 1995; Spreen et al., 1965), timbre (Fujii et al., 1990; Mazzucchi et al., 1992; Eustache et al., 1990-case 2) or rhythm (Fujii et al., 1990; Johannes et al., 1990). Discrimination of pitch was relatively preserved in the patient reported by Fujii et al (1990). The most revealing deficit, however, was documented by Motomora et al (1986). Throughout the course of this patient's recovery, the patient was shown to transition from general AA to non-verbal AA. The auditory temporal resolution of this patient was measured at different stages of his recovery with the click fusion test. The researchers showed that the transition from general AA to non-verbal AA correlated with improvement in the discrimination of inter-click intervals shorter than 80 millisecond, whereas the discrimination of longer inter-click intervals (tested up to 200 millisecond) was still affected. This finding is in contrast to general AA and pure word deafness patients, who were characterized by better discrimination of longer inter-click intervals than shorter ones. Support for this conclusion also comes from the patient of Lambert et al (1989), who was also capable of discriminating 10 millisecond inter click intervals. This deficit is consistent with an fMRI study of healthy participants that reported bilateral activation in the auditory cortices when hearing sounds at duration of 80-300 milliseconds, but only left auditory cortex activation when hearing shorter sounds (Boemio et al., 2005). These findings suggest an auditory duration gradient in the structure of the auditory cortex or underlying white matter, and that non-verbal

AA is the result of circumscribed lesion to the perception of longer sound durations. A possible neuroanatomical structure that relays longer sound duration was suggested by Tanaka et al (1991). By comparing the lesions of two cortically deaf patients with the lesion of a word deafness patient, they proposed the existence of two thalamocortical pathways that inter-connect the MGN with the auditory cortex. They suggested that spoken words are relayed via a direct thalamocortical pathway that passes underneath the putamen, and that environmental sounds are relayed via a separate thalamocortical pathway that passes above the putamen near the parietal white matter.

2.3.3 Amusia:

AA patients are often impaired in the discrimination of all sounds, including music. However, in two such patients music perception was spared (Motomura et al., 1986; Godefroy et al., 1995) and in one patient music perception was enhanced (Mendez, 2001). In rare instances, patients were also diagnosed with an exclusive deficit for the discrimination and recognition of musical segments (i.e., amusia; Ayotte et al., 2000; Chiba et al., 1989; Confavreux et al., 1992; Haguenaer et al., 1979; Henschen, 1920; Michel et al., 1976; Murayama et al., 2004; Peretz et al., 1994, 1998; Piccirilli et al., 2000; Roeser and Daly, 1974; Satoh et al., 2005; Steinke et al., 2001; Terao et al., 2006; Tramo et al., 1990; Wertheim and Botez, 1961; Wilson et al., 2002). The damage in these cases was localized to the right hemisphere or was bilateral. (with the exception of left hemisphere damage in a left handed patient; Piccirilli et al., 2000.) The damage in these cases tended to focus around the temporal pole. Consistently, removal of the anterior temporal lobe was also associated with loss of music perception (Liégeois-Chauvel et al., 1998), and recordings directly from the anterior auditory cortex revealed that in both hemispheres, music is perceived medially to speech (Lachaux et al., 2007). These findings therefore imply that the

loss of music perception in AA is because of damage to the medial aSTG. In contrast to the association of amusia specific to recognition of melodies (amelodia) with the temporal pole, pSTG damage was associated with loss of rhythm perception (arrhythmia). This was demonstrated in three patients with unilateral left or right pSTG damage, in whom music recognition was intact, while perception of rhythm was impaired (Di Pietro et al., 2004; Griffiths et al., 1997b; Mavlov, 1980); and two patients with converse diagnosis, in whom rhythm perception was intact, while recognition/discrimination of musical segments was impaired (Fries & Swihart, 1990; Murayama et al., 2004). Amusia also dissociates in regard to enjoyment from music. In two reports, amusic patients, who weren't able to distinguish musical instruments, reported that they still enjoy listening to music (Lechevalier et al., 1984 ; Zhang et al., 2011). On the other hand, a patient with left hemispheric damage in the amygdala was reported to perceive, but not enjoy, music (Griffiths et al., 2004).

2.3.5 Word Meaning Deafness:

A disorder that is rarely mentioned in aphasia research is word meaning deafness. Patients with this disorder are characterized by impaired speech recognition but intact repetition of speech (Bormann and Weiller, 2012; Ellis, 1984; Franklin et al., 1994, 1996; Hall & Riddoch, 1997; Kleist, 1962; Kohn and Friedman, 1986; Symonds, 1953). Word meaning deafness is often confused with transcortical sensory aphasia, but such patients differ from the latter by their ability to express themselves appropriately orally or in writing. Word meaning deafness patients often repeat words in an attempt to extract its meaning (e.g., "Jar....Jar....what is a jar?"; Bormann and Weiller, 2012). In the first documented case, Bramwell (1897 - translated by Ellis, 1984) reported a patient, who in order to comprehend speech wrote what she heard and then read her own handwriting. Kohn and Friedman (1986), and Symonds (1953) also reported word meaning deafness patients who are able to write to dictation. It

is yet unclear if word meaning deafness is synonymous with the disorder deep dysphasia, in which patients cannot repeat nonsense words and produce semantic paraphasia during repetition of real words (Michel et al., 1983; Dumahel et al., 1986). It is interesting to note that several AA patients were noted with some sparing of speech repetition, and therefore should be diagnosed with word meaning deafness or deep dysphasia (Best and Howard, 1994; Coslett et al., 1984; Jacobs & Schneider, 2003; Eustache et al., 1990; Hamanaka et al., 1980; Okada et al., 1963; Mendez, 2001; Metz-Lutz and Dahl, 1984; Nakakoshi et al., 2001; Stefanatos et al., 2005; Von Stockert, 1982; Wirkowsky et al., 2006).

2.4 Psychological Deficits in Auditory Agnosia:

In the previous sections, I provided evidence that AA is the result of bilateral damage to the auditory ventral stream, which is a pathway dedicated for sound recognition. In the present section, I elaborate on the process of sound recognition that is impaired in AA. In 1928, Kleist suggested that the etiology of word deafness could be due either to impaired perception of the sound (apperceptive AA), or to impaired extraction of meaning from a sound (asemantic AA). This hypothesis was first tested by Vignolo et al (1969), who examined unilateral stroke patients. They reported that patients with left hemisphere damage were impaired in matching environmental sounds with their corresponding pictures, whereas patients with right hemisphere damage were impaired in the discrimination of meaningless noise segments. The researchers then concluded that left hemispheric damage results in asemantic AA, and right hemisphere damage results in apperceptive AA. Given that most documented AA patients have bilateral damage, this interpretation implies that AA patients are impaired in both the bottom-up formation of auditory percepts, and in the matching of these percepts to their meaning. This conclusion, however, is very problematic because it is drawn from patients, who were not suffering from AA (i.e., were capable of performing one of the tasks) and their lesion was not bilateral.

In the following years, cumulative evidence indicated that AA is primarily or solely a perceptual deficit, rather than a disconnection between perception and extraction of meaning. This was first shown by Albert and Bear (1974), who examined an AA patient with the click fusion test. During this test, a patient hears two click sounds with different time interval between them and is instructed to determine if he/she heard one click or two. In their study, the patient was only capable of perceiving the gap between click sounds if its duration was longer than 15 milliseconds, whereas healthy controls were capable of discriminating gaps as short as 2-3 milliseconds. This study was replicated in many later AA cases, and the temporal deficit was consistently reported (Auerbach et al.,

1982; Best & Howard, 1994; Buchtel and Stewart, 1989; Godefroy et al., 1995; Motomura et al., 1986; Otsuki et al., 1998; Tanaka et al., 1987; Wang et al., 2000; Wolmetz et al., 2011; Yaqub et al., 1988). The range of deficits, however, differed between cases with some patients reporting of deficit for gaps as long as 300 milliseconds (Butchel and Stewart, 1989; Tanaka et al., 1987). Studies of patients with Wernicke's aphasia also reported similar auditory temporal deficit (Carmon and Nachshon, 1971; De Renzi et al., 1989; Efron, 1963; Lackner and Teuber, 1973; Stefanatos et al., 2007). Corroborating the relationship between auditory temporal resolution, as measured with click fusion and AA, are longitudinal studies that correlated improvement in this task with amelioration of AA symptoms (Best & Howard, 1994; Godefroy et al., 1995; Motomura et al., 1986).

A resolution for the apperceptive-asemantic dilemma was proposed by Buchtel and Stewart (1989). They reported an AA patient who was better at matching heard words with their corresponding pictures than at identifying them orally or in writing. Because the matching of a spoken word (e.g., 'Gambling') with an associated drawing (e.g., dice) required the patient to internally activate the vocal representation of the word, the authors concluded the patient's internal speech is intact, and therefore there is no disconnection between the acoustic and semantic representations.

A promising candidate for the diagnosis of asemantic AA is the disorder word meaning deafness. This is because these patients are capable of repeating words, without comprehending them. Their ability to repeat a spoken word indicates intact bottom up construction of acoustic representations. Their core deficit is thus in the matching of an acoustic representation to its corresponding semantic representation. Corroborating the view that word meaning deafness is equivalent to asemantic AA are three subjects, who were tested with the click fusion

test and demonstrated to have intact temporal discrimination of sounds (Best and Howard, 1994; Nakakoshi et al., 2001; Stefanatos et al., 2005).

2.3.4 Auditory Agnosia - Open Questions:

Hitherto, I described past research on the physiology and psychology of AA. This field of research did not show significant progression since its discovery, 130 years ago. One of the main reasons for this stagnation was the inability to identify the regions damaged in patients with this disorder, which subsequently rendered it difficult to associate behavior with a cortical location. In the present thesis, I'll attempt to resolve this by examining an AA patient, who suffers from brainstem damage. Because the cortex remained unscathed by the accident, with fMRI I'll provide preliminary evidence that associate AA symptoms with bilateral dysfunction of the anterior auditory cortices, and that spared auditory abilities is due to auditory processing in the posterior auditory cortex. These findings will be then corroborated by EEG and behavioral findings. In this thesis, I also provide evidence that AA patients are capable of segregating sounds into a series of auditory objects (e.g., syllables), and that the primary impairment in this disorder is in the perception of the acoustic details of each auditory object.

3. Case Study:

3.1 History:

LM is a 25 years old female who sustained a severe closed head injury (Glasgow Coma Scale = 3) in a road traffic accident at the age of 17 in 2004. CT scan revealed a hemorrhage in the right basal ganglia and left dorsal midbrain (Fig. 6A). She remained in a vegetative state for almost three months. When she awoke her hearing was severely impaired, but she was able to carry on conversation with her family if they spoke slowly and she could see their faces. By four months after the trauma she was initiating conversations, speaking in full sentences and was oriented to place, time and her circumstances.

Clinical audiological assessment was conducted 8 months after the incident. The testing audiologist reported that responses during pure tone audiometry were 'variable and inconsistent'; and that the patient reported 'being confused about whether she was hearing sounds or not.' Pure tone audiometry suggested severe, asymmetrical hearing loss, especially for low frequencies, that was much worse for sounds presented to the right ear (Figure 7, left). Atypically, detection was much better for narrow-band sounds than for pure tones, especially in the right ear (Figure 7, left). Otoacoustic emissions were intact bilaterally consistent with normal function of outer hair cells in the cochlea. Normal stapedius reflexes indicated intact acoustic reflex arc (undamaged cochlear nucleus, superior olive and facial nucleus). Ringing cochlear microphonics were recorded, which indicates of reduced inhibition of the cochlea due to brainstem damage. Recording of brainstem auditory Evoked potentials indicated of wave I and III with normal latencies and amplitudes. Wave V was absent in the right ear and prolonged in the

left ear, suggesting a problem in the upper brainstem. Five months after the injury, she was ambulatory, independent in daily activities and was able to return home to live with her parents.

Systematic assessment of this patient in our lab began three years after injury. At that time LM was living a full and active life, going out with her friends and taking her dog for walks on the beach by her home. Her main persisting complaint was an inability to hear. She was aware that the sound of her speech had changed. Family and friends had noted no change in her intellect or personality and felt that her memory was good. She worked in the bar of a family-owned resort taking drinks orders. She was organized and responsible and able to effectively manage social events sponsored by the resort. Her parents reported that, except for rare occasions when she would respond to a ringing telephone, she generally did not respond to sounds from locations outside of the room she was in or that were generated by people or objects out of her sight. She did not react to loud sounds (like jets flying close overhead).

Neurological examination revealed intact visual fields. There was no visual or tactile extinction. There was no ptosis or lid retraction and no pupillary abnormality. Macro-square wave jerks were conspicuous. Eye movements were full, but with attempted vertical gaze (downward more than upward), and there was convergence spasm. Speech was dysphonic and slightly dysarthric but intelligible. There was an action tremor in the right arm. There was no weakness of the arms or legs, but she walks with a somewhat spastic gait and tends to circumduct the right leg when walking. The tendon reflexes were increased on the right, especially in the arm. There was no clonus or spasticity, and normal plantar responses. She was unsteady when trying to stand with her eyes closed and her feet together. Her postural reflexes were particularly impaired if perturbed backward.

The lesion was defined using T1 weighted anatomical scans. The scans revealed a cystic cavity in the right putamen at the site of the previous hemorrhage (Fig. 6B; See also Figures 15, 16 in Appendix C for a complete series of axial and coronal sections). There was a small periventricular lesion on the right lower pons, in the region of the inferior cerebellar peduncle, with some hemosiderin staining. There was nearly complete avulsion of the left IC, sparing only its most medial and caudal parts, and destruction of the brachia of the superior and inferior colliculi with the lesion encroaching on the medial aspect of the left medial geniculate nucleus. Probabilistic tractography confirmed preserved thalamic connectivity to auditory cortex bilaterally (Fig. 6C).

Pure tone audiometry repeated in 2015 showed similar performance to that observed in 2005 (Fig. 7, right), with very severe impairment in sound detection (especially in the right ear). Again, performance was variable and unreliable. The patient was asked to raise her hand whenever she heard a click. After several trials, she removed the headphones and said that she didn't hear any clicks – “just sounds...like someone whistling”. She also reported that the detection task was difficult because sound hallucinations interfered with her auditory perception (she described them as ‘tunes in my head’). She could not further characterize this experience, but said that these sounds were not specific musical songs that she could recognize.

3.2 Discussion:

Converging evidence suggests that LM's poor auditory performance is the result of her IC damage, with the damage predominantly affecting the left IC. Examinations of the MRI images didn't indicate any cortical damage, and DTI tractography demonstrated intact thalamo-cortical pathways. Also, no lesions were evident near the ear or in the lower brain stem that could have affected processing in the cochlear nucleus or superior olivary

nucleus. Intact auditory evoked potentials wave I and wave III, intact acoustic reflexes and intact otoacoustic emissions also indicate intact auditory processing in the inner ear and lower brain stem. MRI images show severe circumscribed damage in the left posterior midbrain. Although the MRI images didn't provide evidence of damage to the right IC, the absence of wave V after sound presentation to right ear and the recording of abnormal wave V after sound presentation to the left ear, suggest bilateral damage that affected auditory processing in both the left and right IC. This view is consistent with a study that recorded activity directly from the human brain stem after presenting auditory stimuli to the left or right ear, and reported that wave V is generated from the IC contralateral to the stimulated ear (Møller et al., 1995). Supporting LM's bilateral IC damage as the source of her AA is a survey I conducted of 51 patients with IC damage (appendix A, chapter 9), that showed that patients with unilateral damage don't express AA symptoms (or the symptoms are mild and transient) whereas patients with bilateral IC damage in all cases suffered from deafness or general AA.

LM's poorer ability to detect sounds presented to the right ear than left ear in the audiometry test is consistent with the MRI images and wave V recordings, as it suggests more severe impairment in the left IC than right IC. Associating LM's predominant right ear hearing loss with her predominant left IC lesion is consistent with a study that correlated unilateral ablation of the auditory cortex in monkeys with increased hearing threshold restricted to the contralesional ear (Heffner and Heffner, 1989). Studies of humans with lesions along the central auditory pathways, however, have not previously been associated with such striking asymmetry in hearing thresholds. Previous reports of AA patients with unilateral IC lesions or temporal lobe lesions have only noted mild contralesional hearing loss (IC damage: Durrant et al., 1994; Fischer et al., 1994 - intact pure tone audiometry, mild impairment in speech audiometry; Strauss et al., 2000; Temporal lobe damage: Stefanatos et al., 2005; Saffran et al., 1972). Variability was also shown in the AA population, who suffer bilateral IC or temporal lobe damage, as in some instances no hearing loss was found, whereas other cases were diagnosed with hearing loss

of different degrees (IC damage: Cerrato et al., 2005; Meyer et al., 1996; Pillion et al., 2012; Vitte et al., 2002 - 2 patients; Temporal lobe damage: Auerbach et al., 1982; Motomura et al., 1986; Pillion et al., 2012; Praamstra et al., 1991; Tanaka et al., 1987; Wang et al., 2000; Yaqub et al., 1988). It should also be stressed that her performance in the pure tone audiometry is not a valid indication of her hearing ability. For instance, in a series of behavioral tests that required headphones (detailed in chapter 5), LM was noted to adjust the sound level to a volume that was not obviously different from what the experimenter or control participants would have chosen. In fact in one occasion she commented that the headphones level was too low, and when I checked the headphones' volume it was indeed accidentally set to a very low level. Consistently, if raised hearing thresholds were the source of her deficit, we would expect that she would perform worse, and not better, when instructed to detect narrow band sounds. Her subjective reports of hearing 'tunes in my head' during the pure tone audiometry also suggest that her poor performance in this test may reflect an alteration of signal-noise ratio rather than simply an elevation of amplitude detection threshold.

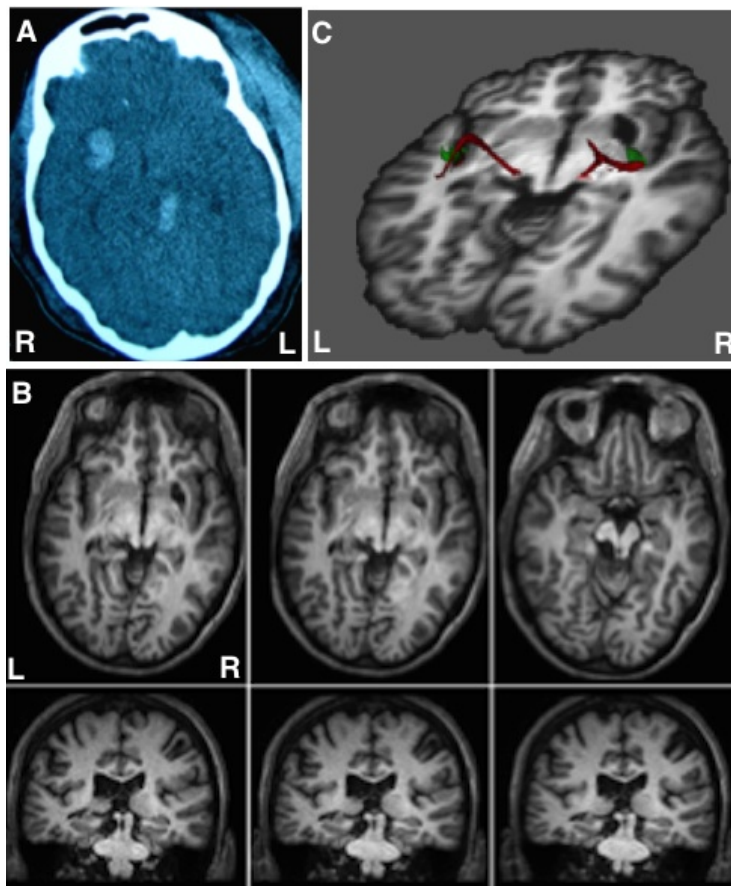


Figure 6. A. CT scan at the time of injury (in radiological orientation) showing hemorrhage in the ventral basal ganglia in the left hemisphere and dorsal midbrain hemorrhage. B. High resolution (0.7 x 0.7x 0.7mm voxels) T1-weighted MRI obtained with a 3T Philips Achieva scanner (Philips Healthcare, Best, The Netherlands) (Voxel size=1 mm³; FOV=240; TR=12; TE1=3.5; delta TE-1.7). Top - axial sections from ventral (right) to dorsal (left) in anatomical orientation; bottom – coronal sections from posterior (right) to anterior (left). C. Probabilistic tractography using FSL FTD Toolbox (Behrens et al., 2003; 2007; <http://fsl.fmrib.ox.ac.uk/fsl/fslwiki/>). Diffusion-weighted echo-planar images were collected at 1.5x1.5x1.5 mm resolution. The imaging parameters consisted of b values = 1 and 1000, 32 isotropically distributed diffusion-encoding directions, TR=2.0 s, TE=35 ms. Seed masks were manually drawn on Heschl’s gyrus (green) and a waypoint masks was manually drawn on the medial geniculate nucleus.

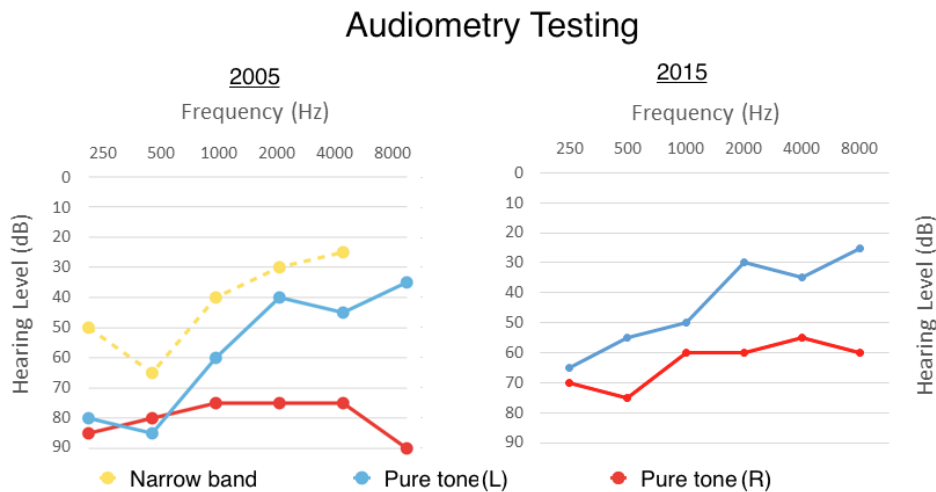


Figure 7. Pure tone and narrow band audiometry from 2005 (left) and 2015 (right). These tests revealed severe hearing loss in the right ear, and moderate to severe hearing loss in the left ear (primarily for low frequencies). LM was also better at detecting narrow band sounds than pure tones.

4. Auditory agnosia and the scientific literature:

4.1 Introduction:

Since AA was first documented more than 130 years ago, there has been surprisingly little progress in understanding its pathophysiology. One of the major contributors to this stagnancy is the lack of consistency in the methods used when investigating AA patients, which rendered comparing patients from different studies difficult. Consequently, most reviews of the literature discussed interesting cases or recurring characteristics but didn't systematically compare cases with one another (Goldstein et al., 1994; Peoppel, 2001; Philips and Farmer, 1990; Polster and Rose, 1998; Vignolo, 1969; Tanaka et al., 1991). Three systematic attempts to sort out the AA literature, however, were conducted and will be summarized below.

Ulrich (1978) surveyed 30 case studies from the AA literature and associated them with hemispheric lesions. His main focus was identifying cases with linguistic AA (i.e., word deafness) and non-linguistic AA (i.e., environmental sound AA), and categorizing patients with general AA into predominantly linguistic AA and non-linguistic AA categories. His primary conclusion was that for general AA and word deafness, unilateral right or left damage is not sufficient for eliciting AA, and that only after the patients suffered additional lesion to the remaining hemisphere, did the AA symptoms emerge. This analysis didn't discuss other possible features of AA patients.

Buchman et al (1986) reported three cases of AA, and further surveyed 34 case studies from the literature. Following Ulrich, this study also showed that AA is dependent on bilateral damage, and that the order of hemispheric lesions is irrelevant to the manifestation of AA symptoms. In this review, when available, the researchers further reported additional characteristics of AA patients. They reported that the most prevalent cause of AA is CVA (cerebrovascular accident), although it was documented with other aetiologies (e.g., encephalitis, epilepsy, traumatic brain injury). Furthermore, the researchers rated each patient for their ability to perceive speech, music and environmental sounds. The researchers also noted that many patients in the AA literature suffer from aphasic symptoms such as writing, reading, naming (including paraphasias) and speech production impairments. Finally, they reported that lip reading was preserved in all the cases.

The most recent comparison of AA patients in the literature was conducted by Griffiths et al (1999). This analysis compared 29 AA patients and 7 cerebral deafness patients, most of which were not examined in the previous reports. Consistent with the analyses of Ulrich (1978) and Buchman et al (1986), the authors reported that bilateral damage affecting the auditory cortex and its vicinity (i.e., the superior temporal gyrus and underlying white matter) is the most common anatomical correlate of AA and cerebral deafness. The authors rated the ability of each AA patient to perceive speech, environmental sounds and music, and concluded that environmental sound comprehension deficit is the result of suffering unilateral right hemispheric damage and speech comprehension deficit is the result of suffering unilateral left hemispheric damage. The authors further argued that, because each case was reported to have a unique set of symptoms, the patients can not be directly compared. This led the authors to conclude that the only common theme uniting all AA cases is deficit in the perception of spectro-temporal features. This study also compared lesion locations and reported that in all cases with bilateral auditory cortex' damage, at least in one side the lesion included Heschl's gyrus or its underlying white matter. This

analysis is consistent with previous researchers who argued that deficit to the primary auditory cortex is mandatory for AA manifestation (Coslett et al., 1984; Phillips and Farmer, 1990). In contrast, in a later review, which was partially based on Griffiths et al (1999) analysis, Poeppel argued against the involvement of the primary auditory cortex in the etiology of AA and suggested that the area most consistently involved in AA is the left pSTG. Poeppel's conclusion, however, is problematic as he doesn't cite any AA patients with spared Heschl's gyrus. The author also argued that his conclusion is based on analyzing 59 cases from the literature, but did not provide a list of the patients that were examined.

Since the publication of the reviews summarized above, many more patients have been reported. In the present chapter I compare the anatomical and psychological characteristics of 278 patients with auditory perception deficits from the literature.

4.2 Methods:

In appendix B (chapter 10), I present a list of patients from the literature, who suffered auditory perception deficits. This list includes any patient diagnosed with general auditory agnosia, pure word deafness, cerebral deafness, word meaning deafness, amusia or environmental sound agnosia. Attempt was made to avoid listing patients who use paraphasia in their speech, such as cases with Wernicke's aphasia and Landau-Kleffner's dysphasia, as these errors indicate impaired inner language. However, because the boundary between intact and impaired inner language isn't always clear, some aphasic/dysphasic cases are included if the auditory deficit was remarkably independent to the aphasia or the aphasia was mild. Due to language or accessibility difficulties, on

some occasions I was not able to examine a case report. In such instances, I collected the missing data from papers that described the case study (these cases are marked with ** in the year column).

In this analysis, each patient was rated for his/her ability to perceive speech (Speech-comp column), repeat speech (Speech-rep column), perceive environmental sounds (E.Sound column) and perceive music (Music column). A caveat should be given in regard to these symptoms. Because every patient was studied independently, and their symptoms were reported in different levels of detail, I used a rather lenient and subjective definition when rating the patients' deficits (3 levels of deficit were used: impaired, partial, intact). Question mark indicates that the symptom was not tested, and blank cells indicates unavailable information. Based on these measurements the patients were divided into four categories: 1. Auditory Agnosia 2. Word Meaning Deafness 3. Amusia-E.Sound Agnosia 4. Cerebral Deafness. The classification of a patient into one of these categories in the present study was independent of the original diagnosis of the patient (the diagnosis presented in the original research paper). Patients characterized by partial or complete impairment of speech recognition and repetition were assigned to the category 'Auditory Agnosia'. Patients characterized by partial or complete impairment of speech recognition but intact speech repetition were assigned to the category 'Word Meaning Deafness'. Patients characterized by intact speech repetition and recognition but with partial or complete impairment of environmental sound comprehension or music comprehension were assigned to the category 'Amusia-E.Sound Agnosia'. Patients characterized by complete deafness at the time of the report were assigned to the category 'Cerebral Deafness'.

In this analysis of the literature I also collected, when available, other relevant information such as the symptoms expressed during the onset of the disorder, and the location of lesions. In the 'Initial Condition' column I

report of any auditory or aphasic symptom that was reported at the acute stage of the disorder (i.e., in the hours/days after the damage occurred). The initial condition was labeled as either Wernicke's aphasia (Wernicke A), global aphasia (Global A), cerebral deafness (Deafness), auditory agnosia (General AA-for cases with milder symptoms than AA), word deafness (Word Deafness-for cases that there was increase in severity of symptoms), or confusion. Some cases were accompanied with mutism (Mutism). Blank cells indicates that the reported symptoms manifested immediately after the damage. Hyphen indicates transition from one disorder to another (e.g., Deafness-General AA - patient transitioned from deafness to general AA to the present condition). In the 'lesion' column I listed whether the patient's damage was either in the right or left hemisphere or both hemispheres (bilateral). (S) indicates diagnosis of hemispheric lesion by symptoms.

4.3 Results and discussion:

In this survey of the literature I examined reports of 203 patients, who were documented with isolated auditory perceptual deficits. From comments in these reports I also extracted partial information on additional 75 patients (278 patients overall). From this patient group, 183 were diagnosed with AA (119 suffered bilateral lesions, 37 suffered left hemispheric lesions, 4 suffered right hemispheric lesions), 34 with cerebral deafness (all suffered bilateral lesions), 51 with amusia-environmental sound agnosia (11 suffered bilateral lesions, 32 suffered right hemispheric lesions, 8 suffered left hemispheric lesions) and 8 word meaning deafness (2 suffered bilateral lesions and 2 suffered left hemispheric lesions; table 1). Patients' age during testing varied from 13 years old to 77 years old, with the number of reported cases steadily increase as patients approach the 60-70 years old age group (Figure 8). These disorders were more commonly reported in males (136 cases) than females (71 cases). The primary cause of these auditory perceptual deficits was cerebral vascular accident (CVA; 166 cases). On

rare occasions, however, this impairment was the result of head trauma (8 cases), dementia (7 cases), brain tumors (6 cases), seizures (5 cases), encephalitis (3 cases), hydrocephalus (2 cases), vascular disease (2 cases), multiple sclerosis (1 case), extrapontine myelolysis (1 case), lithium intoxication (1 case), syphilis (1 case), neurosurgery (1 case) and a bullet wound (1 case). In the AA group, in most cases the auditory perceptual deficit manifested immediately after the trauma. However, in some reports, AA emerged after a short period of deafness (25 cases) or aphasia/dysphasia (31 cases). On 6 occasions this initial short period was also accompanied with mutism. In 13 cases, during the initial short period, the patients were reported to be delirious or confused.

An important objective of surveying the AA literature was to ascertain whether sufficient information was provided in the published record that associates the manifestation of AA symptoms with a lesion to a specific auditory cortical field. In chapter 2, I presented recent models that ascribe sound recognition to the aSTG of both hemispheres. Thus we would expect to find damage to these regions in AA patients. However, researchers in the literature who evaluated autopsy reports, CT scans and MRI images of their patients often concluded that the AA symptoms emerged because of right or left pSTG lesions (Left pSTG: Auerbach, 1982; Caramazza et al., 1983; Doyle and Holland, 1982; Ishii et al., 1995; Kanshepolosky et al., 1973; Leicester et al., 1980; Marshall et al., 1985; Metz-Lutz and Dahl, 1984; Giovanni et al., 1992; Schuster and Taterka, 1926; Slevc et al., 2010; Tanaka et al., 1987; Wolmetz et al., 2011; Right pSTG: Kirshner and Webb, 1982; Giovanni et al., 1982; Tanaka et al., 1987; Engelién et al., 1995). This association of lesion with symptoms, however, appears to be biased by the Wernicke-Lichtheim-Geschwind model, which places the recognition of sounds at the left pSTG. Contradicting this conclusion is the finding that, in all these cases, the researchers reported that the damage was very diffuse and included also Heschl's gyrus. AA in these cases, therefore, could have emerged because either Heschl's gyrus or the anterior auditory fields were also damaged or de-afferented. As mentioned in the introduction

of this chapter, Griffiths et al (1990) argued that AA manifests after bilateral damage that includes at least one of Heschl's gyri, whereas Poeppel (2001) argued that AA manifests after bilateral damage that includes the left pSTG. Based on the reported damage of AA patients in the literature I find no supporting evidence for ascribing a particular role to the left pSTG in the etiology of AA. Moreover, given that in most AA patients the damage tends to be extensive, the prevalent use of scanning methods with low spatial resolution such as CT, and the proximity and small size of the auditory fields in the human auditory cortex (Fullerton and Pandya, 2007), I conclude that the AA literature does not provide sufficient data to associate AA with individual auditory fields.

Table 1: Hemispheric Damage in Auditory Disorders

| | Bilateral | Left | Right | Unknown | Total |
|-------------------------------|-----------|------|-------|---------|-------|
| Auditory Agnosia | 119 | 37 | 4 | 23 | 183 |
| Cerebral Deafness | 34 | 0 | 0 | 0 | 34 |
| Word Meaning Deafness | 2 | 2 | 0 | 4 | 8 |
| Amusia-E.Sound Agnosia | 11 | 7 | 32 | 1 | 51 |

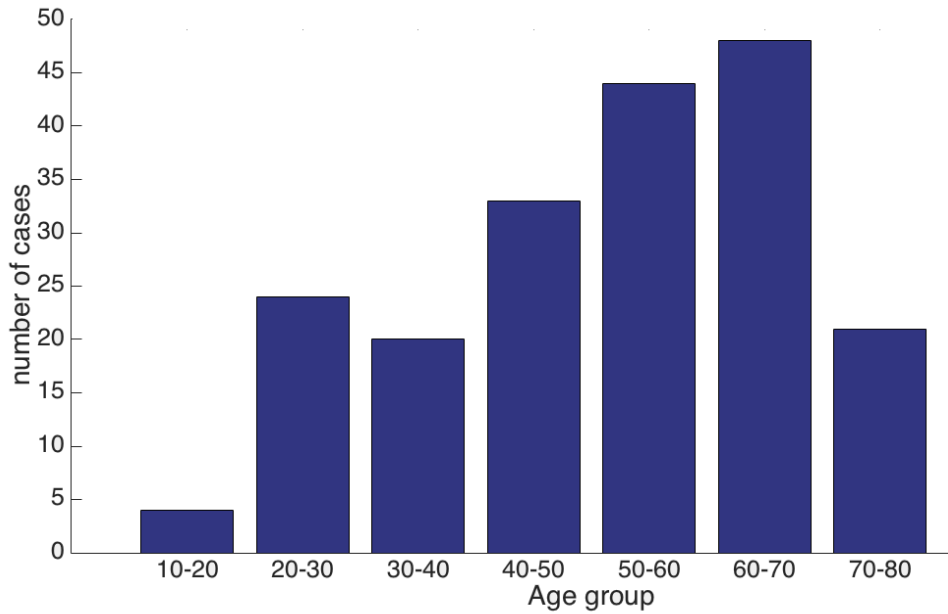


Figure 8. Histogram depicting demographic distribution by age of patients with auditory perceptual deficits.

5. Behavioral experiments:

5.1 Introduction:

In past case studies of AA patients with cerebral damage, the disorder was investigated almost solely using behavioral tests. These tests explored a varied range of auditory faculties, such as identification and recognition of spoken words, environmental sounds and music, discrimination of speech parts, sound localization and more. These tests are critical for the diagnosis of AA as it demonstrates whether the patient is deaf, and if not, what auditory information is processed and experienced by the patient. In the present chapter, I describe a battery of behavioral tests that were administered to LM. These tests shed light on LM's subjective experience of sounds, and help us compare her to other AA patients.

5.2.1 Sound Identification and Recognition:

5.2.1.1 Methods:

Fifteen word sounds and fifteen environmental sounds were randomly presented to the patient via headphones. Prior to the test, the patient was instructed to adjust the volume of the sound to a comfortable level and at which she could consistently detect the sounds. Immediately after hearing each sound, LM was instructed to type the name of each sound that she had just heard. Once she had completed the open ended response question, she was then instructed to choose one of four possible answers presented in multiple choice format on the screen for that same sound. In the word recognition segment of this test, the four possible matches included the correct answer, a phonological distractor (e.g., for the word ‘blue,’ the distractor was ‘glue’), a semantic distractor (e.g., for the word ‘table,’ the distractor was ‘chair’), and a word that that was neither semantically nor phonologically related to the heard word (e.g., for the word ‘train,’ the distractor was ‘hammer’).

5.2.1.2 Results:

By merely listening to the sounds, the patient was accurately able to type to dictation (auditory identification) 2 out of 15 words. Also in this open ended response format, she was able to type the names of 3 of the 15 environmental sounds. (See Tables 2 and 3.)

When given multiple choice selections for the same sounds, the patient’s ability to identify the spoken word (auditory recognition) increased significantly. In these trials, the patient made only 4 errors with spoken words

and 4 errors with environmental sounds. These errors were phonological in nature, as displayed below. On average, when the sound was a word LM required 2 ± 1.8 repetitions and 59 ± 22 seconds to make a response. Environmental sounds required 2 ± 2.1 repetitions and 63 ± 22 seconds for a response.

Table 2: Perceived Spoken Words

| <u>WORD SPOKEN</u> | <u>TYPED RESPONSE</u> | <u>MULTIPLE CHOICE RESPONSE</u> |
|--------------------|-----------------------|---------------------------------|
| Book | Tuckin | Cook |
| Lake | Achoo | Lake |
| Glue | Bee | Blue |
| Table | Sneeze | Table |
| Rope | Bless-you | Rope |
| Shirt | Shout | Shirt |
| Pen | Slam | Pen |
| Lips | Gates | Hips |
| Carpet | Go | Puppet |
| House | Cards | House |
| Soap | Sea | Soap |
| Car | Car | Car |
| Train | Turn | Train |
| Radio | Radio | Radio |
| Stone | Sound | Stone |

* Bold marks a response as correct

Table 3: Perceived Environmental Sounds

| <u>SOUND HEARD</u> | <u>TYPED RESPONSE</u> | <u>MULTIPLE CHOICE</u> |
|--------------------|-----------------------|------------------------|
| Telephone | Telephone | Telephone |
| Fire-truck | Laughing | Machine gun |
| Car-horn | Bell | Car horn |
| Car engine | Saw | Car breaks |
| Trumpet | Smashing | Trumpet |
| Donkey | Singing | Donkey |
| Dog | Barking | Dog |
| Owl | Space | Monkey |
| Rooster | Cockerel | Rooster |
| Toilet | Rustling | Toilet |
| Cat | Beep | Owl |
| Crow | Horn | Crow |
| Horse | Crying | Horse |
| Bird | Chimes | Bird |
| Rifle | Splash | Rifle |

* Bold marks a response as correct

5.2.1.3 Discussion:

The sound identification and recognition test is critical for the diagnosis of AA. This is because failing both tests indicates that the patient suffers from cerebral deafness instead of AA. In the sound identification and recogni-

tion tests I showed that LM is severely impaired when instructed to type the names of heard environmental sounds and spoken words, and that she is much less impaired when instructed to choose the correct answer out of four written alternatives. Like LM, other AA patients were also better at recognizing spoken words when presented with alternative distractors, and made more phonological errors than semantic errors (Best and Howard, 1994; Buchman et al., 1986; Engelien et al., 1995; Eustache et al., 1990; Garde and Cowey, 2000; Goldstein et al., 1975; Kazui et al., 1990; Kirshner and Webb, 1981; Lechevalier et al., 1984; Maneta, 2001; Marshall et al., 1985; Mendez, 2001; Mendez and Geehan, 1988; Miceli, 1982; Michel et al., 1980; Pinard et al., 2002; Saffran et al., 1976; Tessier et al., 2007). These patients were examined in a similar spoken to written word matching tests or sound to picture matching tests. In only a few instances patients were tested for both sound identification and recognition for the same words (Denes and Demenza, 1975; Eustache et al., 1990; Maneta, 2001; Miceli, 1982; Pinard et al., 2002). In these cases, like LM, the patients performed better when tested in multiple choice trials than in open ended trials. Denes and Semenza (1975) labeled this symptom auditory anomia.

5.2.2 Two Click-Fusion Test and Two Box-Fusion Test:

5.2.2.1.1 Two Click-Fusion Test - Methods:

Two 2KHz, 30 ms clicks were presented binaurally to the patient one after the other for a total of 60 trials. In the first 30 trials, gaps of different durations were inserted between the clicks (10-300 ms at 10 ms increments). In the remaining 30 trials, no gap was inserted. The trials were presented randomly. Subjects were asked in each trial to press the left button if there were two sounds or right button if only one sound was heard. The trials were presented in random order.

5.2.2.1.2 Two Box Fusion Test - Methods:

This experiment was used as a control for the two click fusion task to test whether a limitation in temporal resolution was exclusive to auditory stimuli. Two black boxes measuring 5.3 by 5.3 cm were sequentially presented on the monitor in the center of the screen each for 200 ms (60 trials). In half the trials, the stimuli were fused together in time and in the other half the gap varied (17-306 ms at 17 ms increments). The trials were presented in random order.

5.2.2.2.1 Click Fusion Test - Results:

The test was given to 3 control participants (2 females) and to the patient. All the control participants achieved a perfect score by showing no difficulty in recognizing 10 ms gaps or more. The patient, on the other hand, con-

sistently perceived two clicks as a single click for time intervals up to 100 ms, and was inconclusive when the time interval was between 100 to 160 ms. For gaps longer than 160 ms she was able to perceive the two clicks as distinct. Follow-up testing a year later confirmed that an interval > 90 ms was required for her to detect two clicks.

5.2.2.2.2 Box Fusion Test - Results:

The test was given to 3 control participants (2 females) and to the patient. The patient and the healthy participants achieved a perfect score. This study demonstrated that the patient has no difficulty in recognizing temporal gaps in the visual domain as brief as 17 ms.

5.2.2.3 Discussion:

With the click-fusion and box-fusion tests I've shown that LM is impaired at perceiving small inter sound intervals, but is not impaired at comparable temporal gaps interspaced between visual objects. Impairments of auditory temporal resolution of this severity (100-300 ms) have been reported also in other patients with AA (Buchtel and Stewart, 1989; Godefroy et al., 1995; Motomura et al., 1986— stage 1; Otsuki et al., 1998; Tanaka et al., 1987) and fluent aphasia (Carmon and Nachshon, 1971; De Renzi et al., 1989; Efron, 1963; Lackner and Teuber, 1973; Stefanatos et al., 2007). Case studies that followed the recovery course of AA patients further correlated improvements in the click fusion test with improvements in the perception of sounds (Best & Howard, 1994; Godefroy et al., 1995; Motomura et al., 1986). As discussed in chapter 2.4, this temporal deficit is thought to constitute the core deficit in AA.

5.2.3 VOT-POA discrimination task:

5.2.3.1 Methods:

In each trial the patient heard 1 out of 8 possible words pronounced by a female English speaker ['duck', 'tuck', 'puck', 'buck', 'pier', 'beer', 'gear' or 'tear' (pronounced 'teer')]. After the sound presentation, two written alternatives were displayed on the monitor (one above the other) and the patient was instructed to choose the word she had just heard by pressing on its corresponding button. In all trials, one of the two written words was correct whereas the other differed, with equal probability, in either place of articulation (POA; e.g. duck-buck), voice onset time (VOT; e.g. peer-beer) or both (e.g. duck-puck). All sounds lasted for 1.6 seconds and the inter trial interval was 500 ms. This test was conducted in several sessions that spanned over a period of several months. In total the test was repeated 13 times. Each test consists of 36 trials.

5.2.3.2 Results:

LM responded with 62% accuracy when the distractor word differed by VOT only, with 73% accuracy when the distractor word differed by POA only and 78% accuracy when the distractor word differed by both POA and VOT. Accuracy in all three conditions was better than chance according to chi-square tests ($p < 0.05$). A direct comparison of trials in which only VOT differed and trials in which both POA and VOT differed showed that accuracy was significantly higher in the latter condition [chi-square (1,308) = 8.9, $p < 0.005$]. That is, LM performed significantly better when information from POA was available compared to when it was not. In contrast,

there was no significant difference in accuracy between trials that differed only in POA and trials that differed in both POA and VOT [chi-square (1,308)=0.86, $p=0.21$]. This indicates that LM's performance was the same regardless of whether or not VOT information was available. Furthermore, accuracy for trials in which only VOT differed was significantly lower than accuracy for trials in which only POA differed [chi-square (1,308)=4.3, $p<0.05$]. A short version of this test was also given to 4 control participants, who all reached a perfect score (100% correct). Overall, these results demonstrate that LM is significantly impaired at processing speech features such as POA and VOT when compared to healthy control. LM was also significantly more impaired at processing VOT than POA.

5.2.3.3 Discussion:

LM was tested for her ability to discriminate short spoken words that differ by VOT and POA. She was found impaired at discriminating both features, with the deficit much more extensive when the heard words differed by VOT than POA. It is interesting to note that although other AA patients were also reported to have a more severe deficit for VOT discrimination than POA discrimination (Oppenheimer and Newcombe, 1978; Praamstra et al., 1991; Saffran et al., 1976), in other cases, the opposite pattern was reported (Miceli, 1982; Pan et al., 2004— IC damage; Yaqub et al., 1988).

5.2.4 Dichotic Listening Task:

5.2.4.1 Methods:

Two out of six possible words ('money', 'couch', 'radio', 'cigar', 'flute', 'pants') were presented simultaneously to the subject through headphones while all six alternatives were presented visually on screen. The patient was asked to click on all the words that she heard. The six words were presented in all possible combinations. The test was delivered 3 times for a total of 90 trials.

5.2.4.2 Results:

In all trials, the patient insisted that she heard only one word. In 68 trials (75%) the patient correctly identified the word presented to the left ear. In 15 trials (16%) she correctly identified the sound presented to the right ear. In the remaining 7 trials (7.7%) the patient made an incorrect response.

5.2.4.3 Discussion:

In the dichotic listening task of the present study, LM insisted she never heard more than one word, and that the word she heard was perceived as having been presented to the left ear. Accordingly, LM was almost always able to match between the sound from the left ear and its corresponding written word. The phenomena of impaired ability to hear sounds from one ear when different sounds are presented to both ears is known as auditory ex-

inction (hemi-anacusia; Heilman and Valenstein, 1972). Patients diagnosed with this symptom often suffer from unilateral damage, which is contra-lesional to the extinguishing ear (Michel and Peronnet, 1982; de Renzi et al., 1984, 1989; Dumahel, 1986; Lapras et al., 1994 - tectal damage; Clarke et al., 2001 – IC damage; Bellmann et al., 2001, 2003). Auditory extinction, though, independent to auditory comprehension, was also reported in patients with mild auditory agnosia symptoms. For instance, pure word deafness patients with unilateral left hemispheric damage extinguished sounds presented to the right ear (Eustache et al., 1990; Pasquier et al., 1991; Stefanatos et al., 2005; see also the cases of Saffran et al., 1976 and Albert and Bear, 1974 for which the lesion location is unknown). Accordingly, it was shown that patients with auditory agnosia for environmental sounds (Eustache et al., 1990; Fujii et al., 1990) or general auditory agnosia (Mendez, 2001) with right hemispheric damage extinguished sounds presented to the left ear (see also the case of Lambert et al., 1989 for which the lesion location is unknown). These findings imply that it is the right auditory cortex that is responsible for LM's remaining ability to recognize sounds.

5.2.5 Auditory Localization Task:

5.2.5.1 Methods:

The subject was sitting blindfolded in a rectangular room while holding a red laser pointer. The experimenter silently walked in the room to seven pre-defined locations at a distance of 2 meters from the subject and at pre-defined angles (0° , 30° , 60° and 90° in both auditory fields). At each of these locations the experimenter created an identifiable sound with a clicker. The subject was required to point towards the location of the perceived sound. After each trial the experimenter placed a sticky-note at the location that LM had pointed towards. Each sticky-note had the trial number and true stimulus location written on it. The trials were presented in randomized order. The patient decided to end the experiment after conducting 36 trials.

5.2.5.2 Results:

This test was delivered to 3 controls (2 females) and to the patient. All control participants were consistently able to correctly point to the correct azimuth of the sound, with an error range that did not exceed 25 degrees. Note that, as shown in Figure 9, not only did LM mis-localize stimuli on her right to the left hemi-space, localization accuracy for stimuli in the left hemi-space was also poor with compressed localization to a narrow region at 30-60 degrees to the left of the midline.

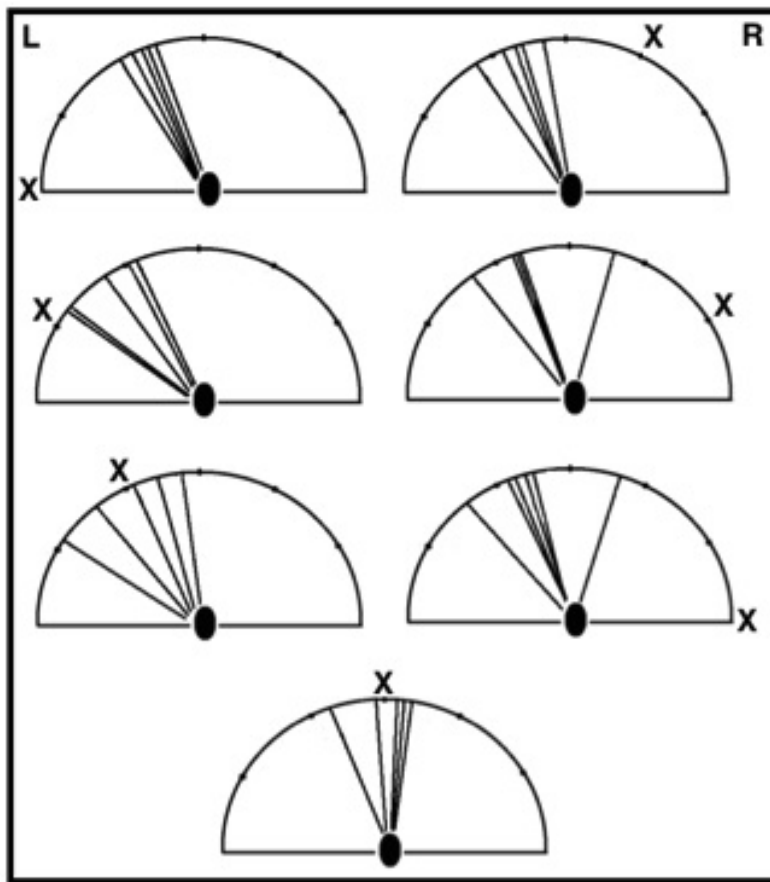


Figure 9. During the auditory localization task the patient was blindfolded and instructed to point toward a sound's source. The sound was presented either in front of the patient (bottom left) or at different degrees to the left (30°, 60°, 90°) or right (30°, 60°, 90°). In each half-circle the black oval represents the patient, the 'X' represents the location of the sound, and the lines represent the perceived azimuth of the sound for each trial.

5.2.5.3 Discussion:

In this test I showed that when LM is instructed to localize sounds in space, she perceives all sounds as coming from the left hemi-field. Similar deficit in sound localization has also been reported in AA patients with bilateral cerebral damage (Jerger et al., 1969; Lhermitte et al., 1971; Albert et al., 1974; Wortis and Pfeifer, 1984; Goldstein et al., 1975; Chochole et al., 1975; Michel & Peronnet, 1980; ; Coslett, Brashear, & Heilmann, 1984; Kazui et al., 1990; Lechevalier et al., 1984; Woods et al., 1984; Tabira et al., 1981; Tanaka et al., 1965). On other accounts, however, sound localization was intact (Fujii, 1990; Gazzaniga, 1973; Spreen, 1965; Jerger et al., 1972; Kanshepolsky et al., 1973; Denes and Semenza, 1975; Okada et al., 1963).

Unilateral shifting of sounds locations is not limited to AA, and was reported also with brain-damaged non agnostic human patients (Sanchez-Longo and Forster, 1958; Matzker, 1959; Neff, 1968; Efron et al., 1983; Haeske-Dewick et al., 1996; Zatorre et al., 1995; Lessard et al., 2000) including two patients who suffer unilateral IC lesions (Litovsky et al., 2001; Champoux et al., 2008). Auditory localization deficits have also been reported in brain-damaged monkeys (Thompson and Cortez, 1983; Heffner et al., 1997; Heffner and Heffner, 2003). In all cases the lesion was restricted to only one hemisphere, and the sounds were perceived as emerging from the hemi-field contralateral to the intact hemisphere.

Unilateral directional loss in brain damaged patients can manifest as a result of impaired bottom-up audio-spatial processing (Bellmann et al., 2001; Bellmann Thiran and Clarke, 2003; Clarke et al., 2004) or impaired top-down auditory attention (i.e., hemi-spatial neglect; Heilman and Valenstein, 1972; Ruff et al., 1981; Bisiach et al., 1984; Hugdahl and Wester, 1994). One might thus assume that the auditory extinction exhibited by LM

might reflect an attention deficit. However, LM's comments during the task suggested that this was not the case. For instance, at one stage during testing, LM removed the blindfold and asked why we were not presenting any 'clicks' from the right side of the room. This comment indicates that she was not neglecting the right auditory space and that she was fully aware of the apparent absence of sounds emanating from locations on her right. It is also important to comment that we were able to demonstrate that her impairment is not due to amodal loss of spatial processing, as in pre-test trials, she showed no difficulty pointing to the sound's source that she was able to see. These findings, thus, indicate that LM's impairment is due to loss of perceptual audio-spatial processing.

5.3. Chapter Discussion:

In this chapter I've examined the patient using a sound identification and recognition task, a phoneme discrimination task, a dichotic listening task, and a sound localization task. LM's performance in these experiments sheds light on the brain regions likely mediating her remaining auditory perception. In the dichotic listening task, when LM heard two different words, she tended to perceive the sound originating from the left ear, thus indicating a role for the right auditory cortex in sound recognition. Similarly, in the sound localization task, LM reported that she perceived sounds as emanating from the left hemi-field, further corroborating the role of her right auditory cortex in her auditory perception. In chapter 2, I also reviewed studies that ascribe sound localization with processing in the posterior auditory cortex, which implies LM's auditory perception is due to processing in this region of the auditory cortex. Arguing that LM's posterior right auditory cortex is responsible for her auditory perception is also congruent with her tendency to comprehend a spoken word/sound better if it is accompanied with its written representation, as the integration of spoken and written words was shown to occur in the posterior auditory cortex (Zubicaray et al., 2001). The possible role of the right posterior auditory cortex in mediating LM's remaining auditory perception is discussed more thoroughly in the general discussion chapter of this thesis (chapter 8.2).

6. Auditory Agnosia - fMRI Study:

6.1 Introduction:

AA is usually the result of bilateral damage to the auditory cortices (Poeppel et al., 2001, 2012; chapter 4); and in most cases, onset only after a second stroke, which sometimes occurs years after the first lesion (Ulrich et al., 1978). Because bilateral lesions tend to be extensive, the cortex is known to reorganize after lesions, and the auditory fields are small, no specific auditory field was hitherto associated with this disorder (Phillips and Farmer, 1990; Poeppel, 2001, 2012). Given the sparing of the cortex (including both auditory cortices) in patient LM, and the acute emergence of her symptoms, LM provides us with a rare opportunity to identify the specific auditory fields that are dysfunctional in this disorder. This can be achieved by contrasting her BOLD activation pattern in the auditory cortices when she hears sounds or not to the BOLD activation pattern of healthy individuals.

6.2 Methods:

6.2.1 Participants:

Participants were patient LM and four neurologically healthy control participants (3 females) of similar age (21-33). For LM, fMRI data was collected in two separate sessions, one year apart.

6.2.2 Design:

A block design paradigm was employed that was based on Belin et al. (2000) “voice localizer” (with the addition of blocks of single words uttered by a variety of speakers). Each participant heard 60 randomized blocks of

sounds (20 blocks of spoken words, 20 blocks of human vocalizations and 20 blocks of environmental sounds) plus 20 blocks of silent events in a single functional run. Each block lasted 8 seconds. All sounds were normalized for energy (RMS) and were semantically meaningful. The participants (patient and healthy control) were instructed to passively listen to the sounds with their eyes closed. Sounds were presented binaurally using the electrostatic NNL headphone system (NordicNeuroLab Inc.) at an intensity of 85dB SPL(C). The patient was scanned twice, with a year apart between the scans.

6.2.3 Imaging protocol:

T2*-weighted imaging scans were acquired with a 3T Philips Achieva scanner (Philips Healthcare, Best, The Netherlands) using an 8-channel head coil. The scans were taken using functional echoplanar imaging with an interleaved ascending sequence consisting of 38 slices of 3 mm thickness (0.3 mm gap) with an in-plane resolution of 2.88 x 2.88 x 3 mm (FOV = 230). The block-design experimental scan (repetition time [TR] = 2 sec, echo time [TE] = 30 ms) consisted of 410 volumes and allowed reliable identification of sound sensitive regions compared to silence. Stimuli presentation wasn't timed in reference to scanner's noise. The functional scan was superimposed on the whole-brain T1 weighted scan (detailed in chapter 3.0), which was collected at the same time.

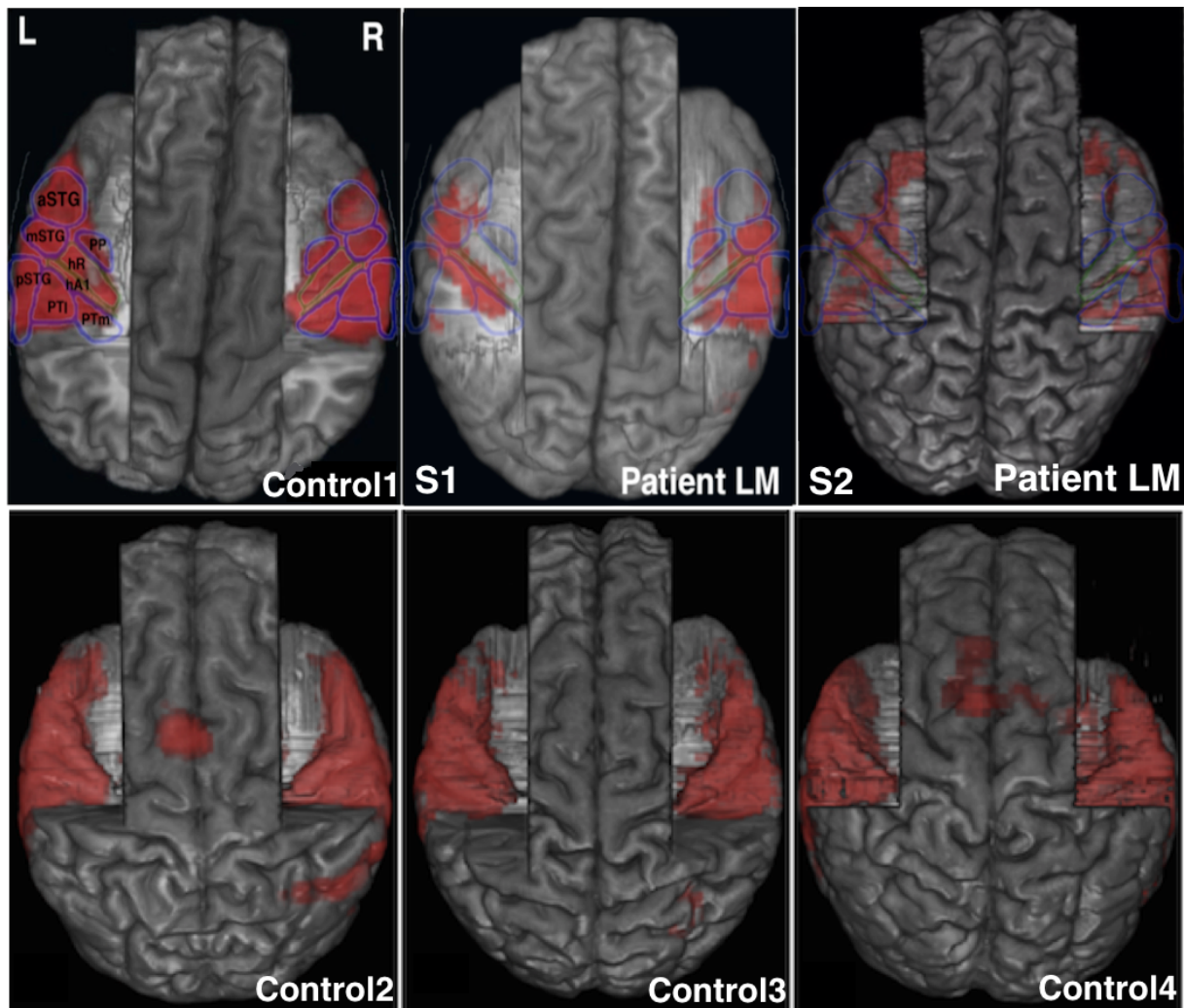


Figure 10. A 3D rendering of the T1-weighted scan of the patient (Sessions 1 and 2) and healthy controls are displayed from above. The parietal and frontal lobes have been manually removed in order to expose the supra-temporal plane. A parametric statistical map of the voxels contrasting BOLD signal changed during presentation of meaningful sounds with scanner noise is superimposed on the T1-weighted brain image. A map of the auditory fields, as identified from a post-mortem cytochrome oxidase staining study (Wallace et al., 2002), is superimposed on top of the statistical parametric map of a representative control (top left). Abbreviations: STG/STG/pSTG- anterior/middle/posterior superior temporal gyrus, PTm/PTI-medial/lateral planum temporale, PP- planum polare, hR- human area R, hA1-human area A1.

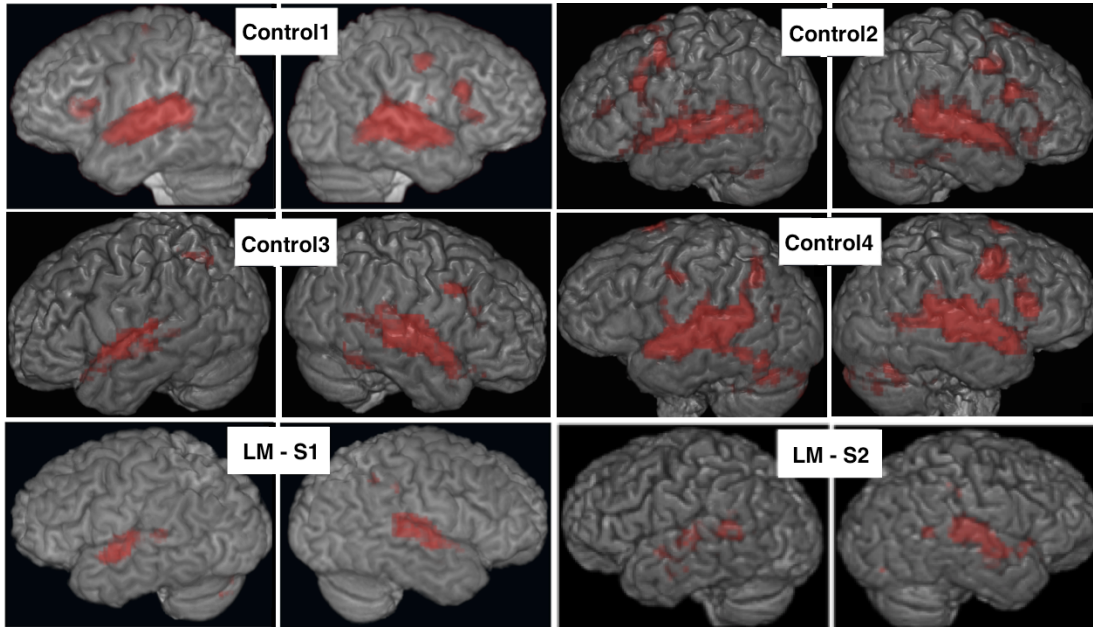


Figure 11. A 3D rendering of the T1-weighted imaging scan, with superimposed BOLD activation of the healthy controls and of the patient in the first (LM-S1) and second (LM-S2) imaging sessions are shown. In all controls, activation included the STG, superior temporal sulcus and frontal lobe. In some controls there was also activation in the parietal lobe (control-3, control-4) and cerebellum (control-2, control-4). LM activation pattern was almost identical in both sessions. Compared with controls, outside of the auditory cortex, small patches of activation were shown in the left temporo-parietal junction, right intra-parietal sulcus and left cerebellum. In the second session, the activation also spread into the superior temporal sulci. In contrast to controls, no activation was shown in the frontal lobes.

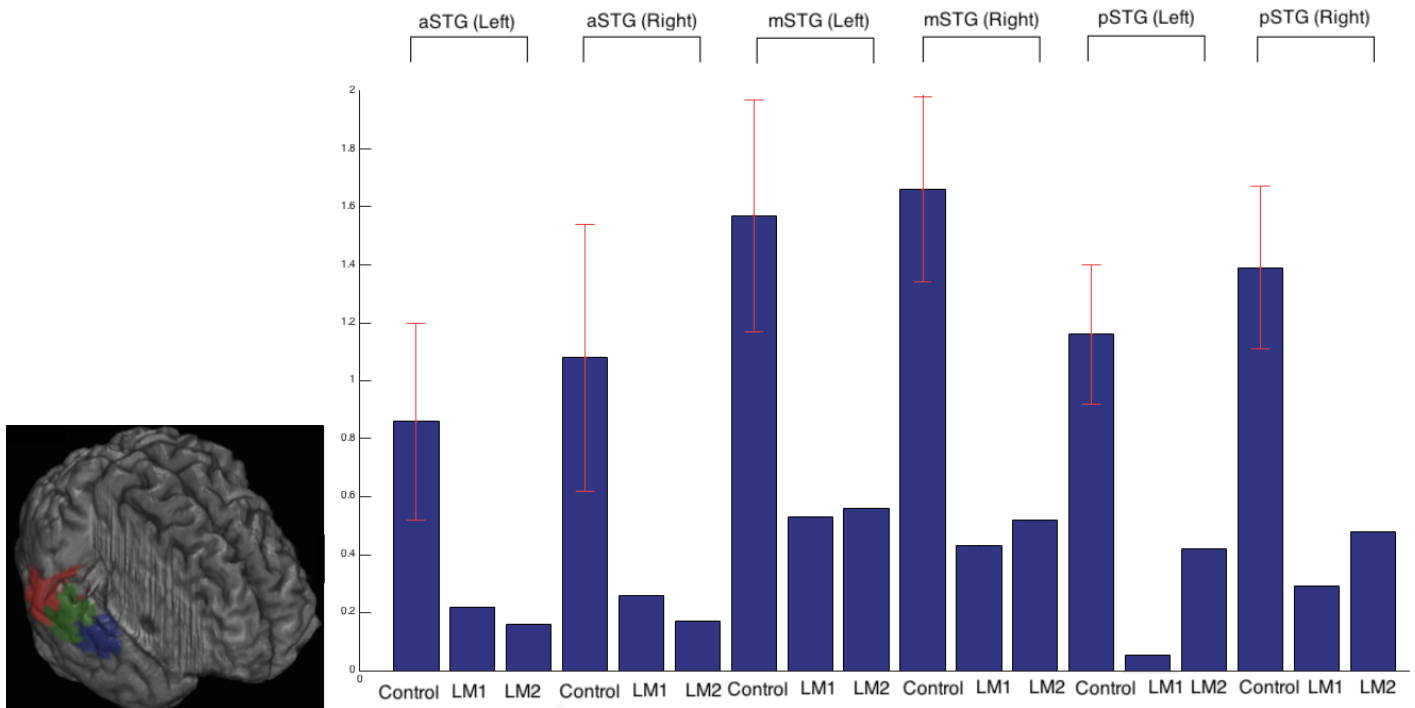


Figure 12. fMRI ROI analysis. Left: Three masks were drawn on each auditory cortex. The area posterior to Heschl's gyrus was designated as the pSTG (red), the area lateral to Heschl's gyrus was designated as the mSTG (green) and area anterior to Heschl's gyrus was designated as the aSTG (blue). Right: Bold signal change was measured for each ROI. 'Control' labelled bars refer to the average signal change of the healthy participants (red whiskers mark standard deviation). 'LM1' and 'LM2' labeled bars refer to LM's signal change in imaging session 1 and 2, respectively.

6.2.4 Analysis and mapping of BOLD activation in auditory fields:

Data were analyzed using the FEAT toolbox of FSL (<http://fsl.fmrib.ox.ac.uk/fsl/fslwiki>). Pre-processing of the data followed a standard analysis pipeline and consisted of AC-PC alignment of the anatomical images (and application of the orientation change to all functional images acquired in the same session). Functional scans were corrected for head motion (trilinear interpolation) by aligning all scans to the first scan of the functional run and a mean image was created. The anatomical scan was co-registered to the mean image. Statistical parametric maps of the t-statistic were generated to identify voxels that were significantly active during all experimental sounds (speech, human vocalizations and environmental sounds) against baseline. Images are depicted at a height threshold $p = 0.05$ (corrected) and an extent threshold of 10 voxels. For the ROI analysis, masks were drawn using the FSLVIEW toolbox of FSL, and percentage BOLD signal change for each region was then calculated using the FEATQUERTY toolbox of FSL.

6.3 Results:

In the current analysis, the auditory stimulated BOLD response for all sounds was contrasted with baseline noise. To visualize the BOLD activation in relation to auditory fields, the parietal and frontal lobes were manually erased using the FSLVIEW toolbox of FSL and rendered into 3D space with MRICroGL (<http://www.cabiatl.com/mricrogl>), thus exposing the supra-temporal planes (temporal operculi). In healthy controls, a map of the auditory fields that was identified in post-mortem brains with cytochrome oxidase staining (Wallace et al., 2002), was superimposed on axial view of the 3D rendering. The matching of the map to the anatomical scan was done by matching two landmarks, Heschl's gyrus and the external contour of the temporal lobe. By apply-

ing the same matching technique to LM's brain, we identified individual auditory fields. This method is similar to the method used by Viceic et al (2006). In Figure 10, I show this map superimposed on the exposed supra-temporal planes of the healthy controls and LM's first imaging session (S1) and second imaging session (S2). Corroborating this method is the finding that LM's BOLD activation patches correspond with the boundaries of the auditory fields in the map, and that the triangular wedge of the BOLD activation in healthy control closely matched with the triangular shape of the map.

Figure 11 shows that in all healthy participants the activation was spread bilaterally across the supra-temporal plane, superior temporal gyrus, superior temporal sulcus and in varying locations in the frontal lobes (primarily Broca's area and dorsal premotor cortex). Two control participants also showed activation in the left parietal lobe (control-3 and control-4) and cerebellum (control-2 and control-4).

In both sessions, the pattern of activation for the auditory cortex of patient LM was more limited than that observed in controls (Figures 10, 11). In the core regions, the activation was restricted to posterior bank of Heschl's gyrus bilaterally (hA1), whereas the remaining Heschl's gyrus (hR) was inactive. In the associative auditory cortices of both hemispheres, there was activation in LM's mSTG, whereas the aSTG were inactive bilaterally. In the right hemisphere, there was activation also in the PT-pSTG. In the second session, activation was also observed in the left PT. In the first imaging session, only the right planum polare was activated, whereas in the second session the activation included both planum polare (this activation was also spread to the medial temporal pole, near the amygdala). Outside the supra temporal plane and STG, when compared to controls, LM showed no significant activation in the superior temporal sulci and frontal lobes of both hemispheres (Figure

10). Small areas of activation are also evident in LM's left temporo-parietal junction, right intra-parietal sulcus and left cerebellum.

In order to confirm LM's weak responsiveness to sounds in the anterior auditory cortices, and to measure possible asymmetry in responsiveness to sounds between the hemispheres, Region of Interest (ROI) analysis was performed. In each brain (LM and controls), three ROI masks were drawn on the basis of an anatomical landmark, Heschl's gyrus. Voxels lateral to Heschl's gyrus were labeled as mSTG and the areas posterior and anterior to this ROI were labeled as pSTG and aSTG, respectively (Figure 12 - left). Because no clear anatomical landmark separates the primary auditory fields and because of their small number of voxels, areas hA1 and hR were excluded from the ROI analysis. BOLD signal change was then calculated for each ROI (Figure 12 - right). Comparison of LM to healthy controls with a Z test showed reduced BOLD activation in all ROIs in both the first and second scanning sessions (all with $p < 0.0001$). Comparing the difference in activation between ROIs from the same hemisphere was performed by subtracting the BOLD signal of one ROI by another (e.g., aSTG_R-mSTG_R) and then normalizing this value by dividing it with the average activation of that cortex (e.g., $(pSTG_R+mSTG_R+aSTG_R)/3$). For asymmetry measurements (e.g., pSTG_R-pSTG_L), normalization was performed by dividing the difference between the two ROIs by the average of cortical activity of the auditory cortices of both hemispheres ($(pSTG_R+pSTG_L+mSTG_R+mSTG_L+aSTG_R+aSTG_L)/6$). This normalization was necessary because LM's overall reduced brain activation resulted with a ceiling effect which biased the results (e.g., for calculating aSTG-mSTG, the reduced activation in the mSTG masked the bigger reduction in the aSTG, and consequently the difference between these ROIs appeared smaller than in the control group). For the healthy group, the subtraction and normalization were calculated for each control participant and only then the values of all participants were averaged. Calculating the difference between LM's areas pSTG

and mSTG, and comparing it to the difference between these regions in the average control, didn't indicate significant signal change in the right hemisphere in the first session ($p=0.15$) and second session ($p=0.33$). In the left hemisphere, LM's area pSTG was significantly lower than mSTG in the first session ($p=0.005$) but not in the second session ($p=0.44$), when compared to the same difference in the average control. More anteriorly, there was significant reduction when calculating the difference between LM's aSTG and mSTG in both hemispheres of both sessions when compared to the average control (Session 1 Left: $p=0.0005$ Right: $p=0.02$, session 2 Left: $p<0.0001$ Right: $p=0.002$). In healthy controls, no asymmetry was shown in BOLD signal between each ROI and its counterpart in the contralateral hemisphere (pSTG: $p=0.258$; mSTG: $p=0.91$; aSTG: $p=0.415$). In both sessions, no difference in BOLD signal change was shown between LM's left and right aSTG (session 1: $p=0.29$, session 2: $p=0.25$) and left and right mSTG (session 1: $p=0.14$, session 2: $p=0.25$), when compared to the same difference in the average control. In the pSTG there was significant reduction in BOLD signal change in the left hemisphere in the first session ($p=0.0001$) but not in the second session ($p=0.44$), when compared to the same difference in the average control. Taken, together, these findings suggest that relative to LM's overall brain activation, in both hemispheres, her anterior auditory field, aSTG, was significantly less responsive to sounds than the mSTG of the same hemisphere when compared to the healthy group. The right pSTG was also significantly more responsive to sounds than the left pSTG when compared to healthy group.

6.4 Discussion:

In this study, I compared the effect of passively listening to sounds on the BOLD activation pattern between healthy controls and our AA patient. The most visible effect of her disorder on processing in her auditory cortices was overall reduced BOLD signal in all regions. This is likely due to her suffering damage to the mid-

brain, resulting with reduced transmission of auditory afferents to the auditory cortices. Comparing activity between ROIs of the same hemisphere showed that, relative to overall activation in the cortex, there was less activation in the aSTG when compared to the mSTG than was found for the healthy participants. This finding is important because recent models ascribed a critical role for areas aSTG in sound recognition (cf. chapter 2). In the general discussion chapter (chapter 8.1), I compare this finding to findings collected from LM's other tests, which confirm impairment in her anterior auditory fields. An hypothesis for the relationship between her brain stem damage and her lack of recruitment of these regions is also presented.

Another interesting observation was that, in the first imaging session, the activation in the pSTG of the left hemisphere was significantly lower than the pSTG of the right hemisphere. In the second imaging session, conducted a year later, although no asymmetry was found in activation between the right and left pSTG, the right pSTG was more active than the left one. This tendency for stronger activation in the right pSTG is interesting as it could suggest that LM's right pSTG takes a predominant role in processing her remaining auditory abilities. In the general discussion section (chapter 8.2) I show that findings collected from LM's other tests supports this hypothesis.

7. Auditory Agnosia and Mis-Match Negativity:

7.1 Introduction:

One of the basic principles that govern hearing is the detection of acoustic change. EEG and MEG studies reported that exposure to infrequent changes of acoustic stimuli correlates with increase in negativity of electrical charge at about 100-250 ms post sound onset (see May and Tiitinen, 2010; Näätänen et al., 2010 for reviews). This negative enhancement is known as the mismatch negativity (MMN). In a typical MMN study, the negative shift is detected after an individual hears several identical stimuli (i.e., standard), which end in a sound that differs in at least one acoustic dimension (i.e., deviant). MMN can be generated via manipulation of simple acoustic dimensions (e.g., intensity, frequency, duration, inter-sound interval; Escera et al., 2002; Giard et al., 1995; Levänen et al., 1996; Liasis et al., 2000; Paavilainen et al., 1991; Rosburg, 2003; Sysoeva et al., 2006a; Yabe et al., 2001) as well as by manipulation of more complex variables (e.g., phoneme regularity, tone pattern; Alho et al., 2003; Näätänen et al., 1997). Studies attempting to localize the MMN generator (Giard et al., 1995; Rosburg, 2003; Sysoeva et al., 2006b) demonstrated that a different population of auditory cortex's neurons mediates the MMN response of each acoustic dimension. More detailed localization of the different MMN generators into specific auditory fields, however, hasn't been established.

In the present study, I attempt to correlate LM's cortical activation pattern (presented in Chapter 6) with her ability to generate frequency-, duration- and intensity MMN responses; and based on these findings to infer for the cortical auditory fields that generate each MMN response.

7.2 Methods:

7.2.1 Participants:

In addition to LM, 10 neurologically intact right-handed females (age range 20-31) participated in this study. All participants provided written informed consent and were paid for their participation. With the exception of patient LM, all participants reported having intact hearing.

7.2.2 EEG Recordings:

Electrophysiological data were recorded in reference to Cz at a rate of 1 kHz from 64 Ag/AgCl electrodes placed according to the extended 10–20 convention (Neuroscan system). Impedances were kept below 7Ω . EEG activity was filtered on-line band pass between 0.1 and 200 Hz and re-filtered off-line with a 30 Hz low pass zero phase shift digital filter. Eye-blinks were detected using the vertical electro-oculogram bipolar channel. Potential variations exceeding a threshold of 20% of maximum EEG amplitude over the duration of a complete individual recording session were automatically registered as artifacts and contributed to the computing of a model blink artifact (derived from approximately 50 individual blink artifacts in each participant). Artifacts were then individually corrected by subtracting point-by-point amplitudes of the model from signals measured at each channel proportionally to local maximum signal amplitude. Eye movements, drifts, and other artifacts were removed by an algorithm that eliminated all events associated with brain waves that were larger than 75 μV or smaller than $-75 \mu\text{V}$.

7.2.3 Experimental Design:

Prior to the experiment, the sound's intensity was adjusted to the comfort level of the participants. The participants were instructed to watch a silent movie with their eyes open and to minimize eye and jaw movements. The participants were seated comfortably in a reclining chair in a dimly lit, electrically and acoustically shielded room. The experiment was prepared using the Presentation Software (www.neurobs.com). All auditory stimuli were prepared using the Cool Edit Pro 2.0 software (www.cooledit.com). Four tones were used in the experiment: T1 (200 ms, 2000 Hz), T2 (200 ms, 2250 Hz), T3 (100 ms, 2000 Hz), T4 (200 ms, 2000 Hz, dB SPL level that is 60% of the participant's comfort level). The sounds were presented binaurally to the participant via pneumatic ear inserts.

During the experiment, 3 variables were modified: frequency, duration, and intensity. Each variable was tested separately. During each variable, the participant heard an MMN inducing sequence that was repeated 100 times. Each sequence began with a series of 4-7 identical sounds (standard) and finished in a sound that differed from the standard on the basis of a single acoustic variable (deviant). Each condition was presented twice, with the sounds serving as standard and deviant in the first presentation, exchanging roles in the second presentation of the same condition (see table 4 for the standard and deviant of each condition). The inter-stimulus interval was 200 ms for all conditions.

7.3 Results:

Consistent with previous research (Scherg et al., 1989), an EEG was recorded from the three fronto-medial electrodes of each hemisphere (FC1, F3 and AF3 for the left hemisphere, and FC2, F4 and AF4 for the right hemisphere). To analyze the MMN response, I first extracted the 400 ms post-sound onset of each standard and deviant tone, and then averaged the recordings from the three electrodes of each hemisphere. I then averaged the two presentations of the same condition to calculate the average standard and average deviant (e.g., for the frequency condition, we averaged T1 and T2 when served as standard, and averaged T1 and T2 when served as deviant). This calculation enabled us to eliminate any contribution to the ERP component that is not due to detection of infrequent acoustic change. To visualize the MMN response, in Figure 13 I display the EEG activation of the standard (blue line) and deviant (red line) of each condition.

I then examined whether LM's MMN response was significantly different than the MMN response of the control sample. The MMN response was calculated by subtracting the EEG activation level of the standard from the deviant at each time point. In Figure 14, LM's MMN response (red line) was then compared to the average (black line) and upper/lower boundaries of the 95% confidence interval range (gray lines) of the control sample. The MMN was determined as absent in LM if her MMN response was below the lower confidence interval boundary of the control sample.

When all healthy participants perceived a deviant sound of any kind (duration, intensity, frequency), this resulted in clear and visible P1, N1 and MMN ERP components (Figure 13). In contrast, recordings from LM's brain showed no generation of any MMN response when the deviant was either of frequency or duration. MMN re-

sponse for intensity was only recorded in the right hemisphere. It is also interesting to note that the N1 component was not visible under any condition, and in the only case in which MMN was recorded (intensity deviant in the right hemisphere), it was the baseline activation level that became more negative instead of N1 (Figure 13-bottom right graph).

7.4 Discussion:

In the present chapter, using EEG recordings, I've shown impairment in LM's ability to detect changes in the sound's frequency and duration in both hemispheres and intensity changes in the left hemisphere. Her ability to detect changes in sound's intensity was relatively intact in the right hemisphere.

As discussed in Chapter 2, the primary auditory cortex is composed of 2 auditory fields denoted as areas hA1 and hR. Measurements of neural selectivity of 'best-frequency' in the auditory cortex of monkeys and comparable fMRI studies in monkeys and humans demonstrated that each primary auditory field has a different cochleotopic organization. Area hA1 is characterized by a posterior to anterior gradient of increase in frequency-selectivity, and area hR by a posterior to anterior gradient of decrease in frequency-selectivity. Because in both auditory cortices area hR in LM's was unresponsive to sounds and she did not generate MMN for frequency and duration deviant sounds in both hemispheres, I propose that area hR generates the frequency- and duration-MMN.

Past studies corroborate the localization of frequency-MMN to area hR. The auditory fields that generate frequency MMN was investigated in healthy participants using fMRI (Opitz et al., 2005). This study presented par-

ticipants with a sequence of sounds that induces MMN (several identical click sounds that end with a sound of different frequency) and contrasted this it with a sequence of sounds that don't produce MMN (every sound in the sequence had different frequency). The hearing of MMN inducing sound changes correlated with activation increase in the anterior bank of Heschl's gyrus (i.e., area hR), and the hearing of sound changes that don't induce MMN correlated with activation increase in the posterior bank of Heschl's gyrus (i.e., area hA1). The researchers proposed that this hA1 activation corresponds with ERP component N1, which is thought to participate in the orienting of attention toward sounds. Similar results were also obtained via intra-cerebral recording from the supra-temporal plane of epileptic patients (Halgren et al., 1995). This study reported that frequency-MMN is generated at much earlier latencies in the anterior supra-temporal plane than in the posterior supra-temporal plane. This study also reported that the MMN generator is located anterior to the generator of N1, which was localized to posterior Heschl's gyrus. EEG (Scherg et al., 1989) and MEG (Hari et al., 1992; Kozryukov et al., 1999) studies also confirmed that frequency MMN is generated slightly anterior to N1, and one study (Tiitinen et al., 1993) further reported mirror image cochleotopic maps for MMN and N1, which are consistent with the topography of the cochleotopic maps in areas hA1 and hR along the curvature of Heschl's gyrus.

When compared to frequency-MMN, very little research was allocated for investigating the characteristics of duration- and intensity-MMN. Consistent with my localization of frequency- and duration-MMN to area hR, MEG studies reported that duration-MMN is located near frequency-MMN in Heschl's gyrus (Giard et al., 1995; Rosburg, 2003). (although see Sysoeva et al., 2006, which localized duration-MMN to the medial planum temporale.) These studies also localized intensity-MMN medial to N1 in area hA1 (Rosburg et al., 2004) or more caudally, in the medial planum temporale (Giard et al., 1995). These findings are consistent with my re-

sults because both hA1 and the planum temporale in LM's right hemisphere were responsive to sounds (chapter 6), and LM was shown to generate intensity-MMN only in the right hemisphere. The localization of intensity-MMN into area hA1 (instead of planum temporale) is consistent with a study that recorded intensity-MMN directly from the primary auditory cortex of monkeys (Javitt et al., 1994).

Table 4: The Deviants and Standard of Each Condition

| Condition | Standard | Deviant |
|------------------|-----------------|----------------|
| Frequency 1 | T1 | T2 |
| Frequency 2 | T2 | T1 |
| Duration 1 | T1 | T3 |
| Duration 2 | T3 | T1 |
| Intensity 1 | T1 | T4 |
| Intensity 2 | T4 | T1 |

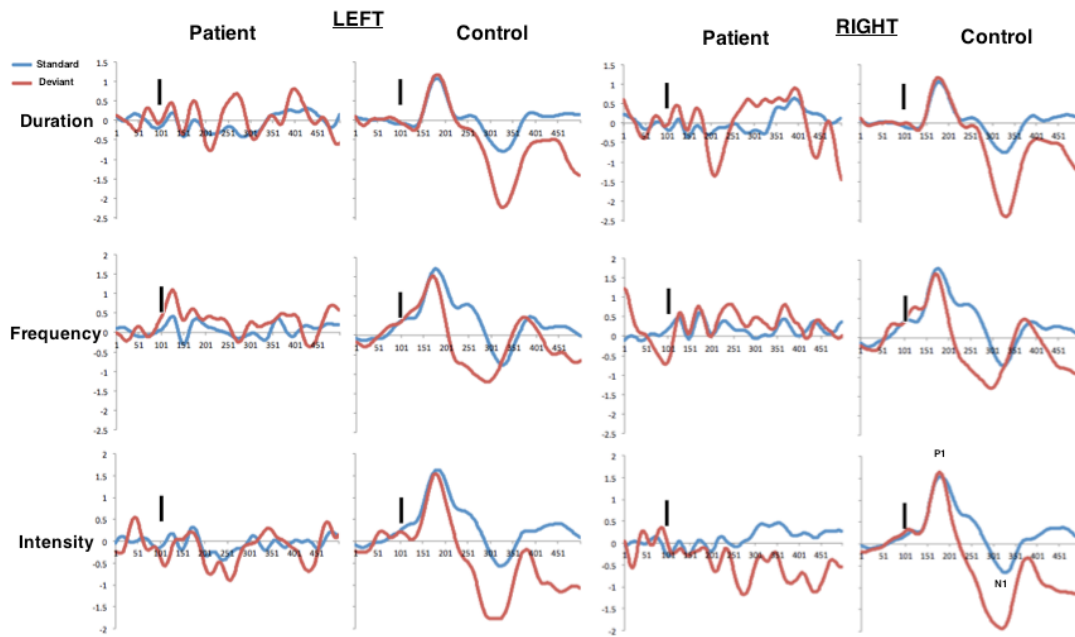


Figure 13. EEG responses of the patient and the average of the control sample to the perception of the standard tone (blue) and deviant tone (red). Under all conditions (duration, frequency, intensity), the control participants were observed to generate MMN, as well as ERP components P1 and N1 (see bottom right). The patient did not generate P1 and N1 ERP components. The only condition in which the patient was observed to generate MMN was when the deviant tone differed from the standard by the intensity level, and only in the right hemisphere. Black vertical rectangle represents sound onset.

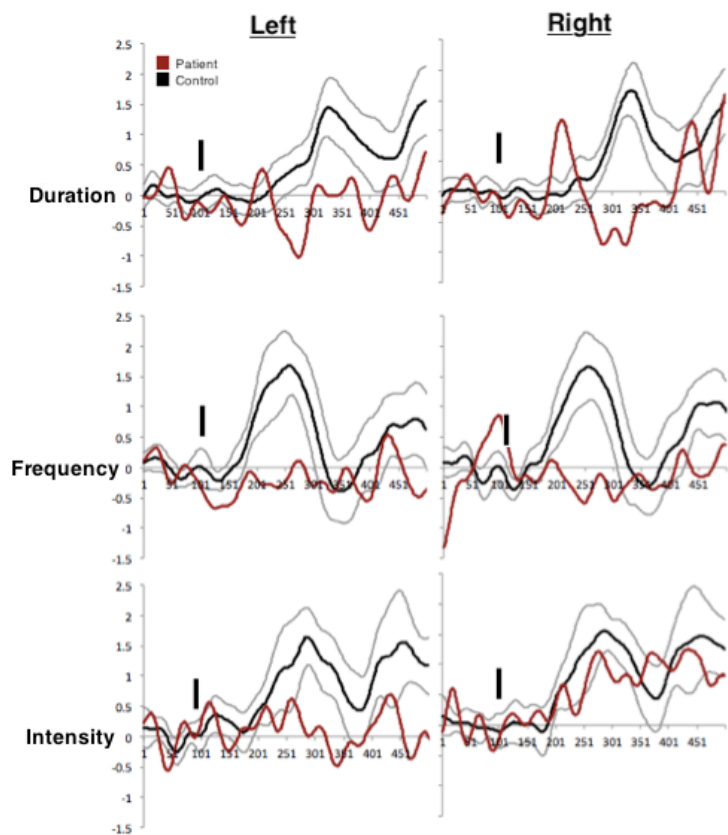


Figure 14. The MMN response (standard – deviant) of the patient (red) was compared to the average (black) and lower- and upper-bound 95% confidence interval (grey) of the control sample. The patient was defined as incapable of generating the MMN if her MMN response was consistently beneath the lower confidence interval of the control sample. Black vertical rectangle represents sound onset.

Chapter 8. General Discussion:

In the last 130 years, despite countless debates concerning AA, very little has changed in our understanding of this disorder (chapter 2). This lack of progress is primarily due to patients developing AA only after suffering two separate neurological insults, affecting the temporal lobes of both hemispheres. Because bilateral damage tends to be extensive, no cortical field was so far associated with this disorder. In the current thesis, I examined a rare case of AA with brainstem damage. Due to the cortex spared in the trauma, this case provides a rare opportunity for examining the involvement of the auditory cortex in this affliction.

In the coming discussion, I present several novel perspectives regarding AA, auditory perception and organization of the human auditory cortex. First, I explore the neuroanatomical correlates of LM's AA disorder. In section 8.1, I present converging evidence that LM's agnosic symptoms are the result of the anterior auditory fields not being recruited for extracting meaning from sounds due to receiving diminished and/or abnormal auditory input. In section 8.2, I provide converging evidence that LM's pSTG (with emphasis on this region in the right hemisphere) is responsible for her spared auditory perceptual abilities, and further suggest that the pSTG mediates the spared auditory perception of other AA patients. In the following sections, I explore the psychological experience of LM and other AA patients. In section 8.3, based on the result of the click fusion test in our patient and in other AA patients, I propose that AA patients are capable of segregating sounds into separate auditory objects, and that their deficit is in the encoding of the acoustic content of each auditory object. In section 8.4, I argue against a model of AA that portrays this disorder as an amodal loss of temporal resolution (i.e., loss of both visual and auditory temporal properties), and provide evidence that AA is exclusive to the auditory modality. In section 8.5, I point out that throughout the literature, there was little consistency in the diagnosis of AA

patients, and based on the present study, suggest a more systematic diagnosis process. In section 8.6, I interpret the results from LM's fMRI study as evidence of parallel processing streams in the human auditory cortex.

8.1 Auditory Agnosia is due to Dysfunctional Processing in the Auditory Ventral Streams:

The source of the auditory impairments experienced by AA patients has so far not been discovered. In this chapter I present findings from the fMRI, EEG and behavioral studies that shed light on the origin of LM's disorder, and potentially also of other AA patients.

The first clue to LM's disorder arrives from her IC lesion. As discussed in chapter 2, the IC is the first auditory center that converges all the auditory input from both ears, and as such was considered the true primary auditory center (i.e., equivalent to the primary visual area; Nelken et al., 2004). It is therefore possible that LM's AA is the result of dysfunctional auditory processing in the IC. If this is the case, I expect IC damage to result in more severe auditory impairment than damage to the auditory cortex. Documented AA patients with IC lesions, however, are remarkably similar in their characteristics to AA patients with temporal lobe damage. Tectal and cortical AA are also similar in their requirement for bilateral damage, as patients with unilateral damage in either the IC or temporal lobe rarely develop in AA (appendix A; Ulrich, 1978). In one case, a patient with IC damage was even diagnosed with pure word deafness (Meyer et al., 1996). This case is revealing because electro-stimulation of the left anterior auditory cortex during surgery resulted with non-agnosic patients transiently developing pure word deafness (Matsumoto et al., 2011). Given the similarity between tectal and cortical AA, a possible aetiology for tectal AA is that IC damage results with reduction in auditory input relayed to the upstream auditory centers (medial geniculate and auditory cortex). This results with weak activation of the auditory cortices, which resembles the effect of direct cortical injury. This explanation is consistent with the results of the fMRI study, in which LM was shown to have overall reduced BOLD activation in the auditory cortices.

Associating LM's AA symptoms with her general diminished sound responsiveness in the auditory cortices doesn't explain some interesting findings such as the weaker responsiveness to sounds of the anterior auditory fields when compared to more posterior auditory fields. This finding can be explained by human and monkey studies that implicate the auditory ventral streams of both hemispheres, the anterior auditory cortices in particular, in sound recognition (cf. chapter 2). In a previous review it was even proposed that, because AA is most commonly reported in patients with bilateral temporal lobe damage, AA is the result of disruption to the anterior auditory cortices of both hemispheres (Hickok and Poeppel¹; 2007). Further supporting this view is a study that removed the auditory cortex of monkeys on one side, and either the anterior or posterior portion of the contralateral auditory cortex. Consistent with the ascribed role of both anterior auditory cortices in sound recognition, only removal of the anterior portion resulted with the monkeys losing the ability to discriminate sounds (Harrington and Heffner, 2002; Harrington et al., 2001; Heffner and Heffner, 1986).

Consistent with the association of LM's AA with her weak responsiveness to sounds in the anterior auditory fields are the results of the EEG study. In this study, I showed that LM is impaired at detecting changes to the duration or frequency of sounds (measured as mis-match negativity difference wave-forms), and that detection of changes to sound intensity is lateralized to the right hemisphere. This bilateral impairment in the detection of spectro-temporal changes could be related to the bilateral weak responsiveness to sounds in the anterior auditory cortices that was shown in the fMRI scan. Assuming that the bilateral deficit in both the fMRI and EEG studies results from the same deficit, these findings indicate that MMN for frequency and duration are generated in

¹ In chapter 4, I presented a study by Poeppel (2001) that associates AA with left pSTG damage, whereas in the study presented here (Hickok and Poeppel, 2007) he associates AA with bilateral aSTG damage. The author doesn't explain this self contradiction.

the anterior auditory cortices, and serve primarily for sound recognition. It also suggests that accurate discrimination of sound intensity is not required for sound recognition. Associating sound duration and frequency, but not intensity, with sound recognition is also intuitively correct because changing the duration or frequency of a sound can alter its meaning, whereas altering its intensity has no effect on the meaning (e.g., when an individual either shouts or whispers a word/sound, its meaning remains the same).

The results of the VOT-POA discrimination study also support the association of the anterior auditory cortices with AA. In that experiment I showed that LM is more impaired at discriminating VOT than POA. Several studies demonstrated that VOT is primarily processed within the auditory ventral streams. For instance, an fMRI study reported activation increase in the aSTG, but not pSTG, when participants heard voiced consonants compared to unvoiced consonants (Obleser et al., 2006b). Another fMRI study presented participants with the sound of a consonant with a VOT of varying durations. The study reported that VOT increase correlated with activation increase in the aSTG and anterior Heschl's gyrus (hR; Hutchison et al., 2008). Given that VOT, but not POA, requires analysis of short durations, this VOT discrimination deficit is also consistent with LM's bilateral lack of MMN for sound duration, which I associated earlier with the lack of activation in the anterior auditory cortices. The role of the anterior auditory cortex in encoding VOT is corroborated by a study that recorded neural discharges directly from Heschl's gyrus of epileptic patients while presenting consonants with VOT of different durations (Steinschneider, 2004). This study reported that neurons located along the anterior bank of Heschl's gyrus (corresponding with hR), but not along the posterior bank of Heschl's gyrus (corresponding with hA1), encode the duration of the VOT sound as a delay in their neural activity.

The fMRI, EEG and behavioral findings suggest that LM's auditory perceptual deficit could be the result of impaired auditory processing in the IC, the result of general diminished responsiveness to sounds in the auditory cortices or is the result of more specific impairment in the sound recognition mechanism of the anterior auditory cortices. A possible explanation of LM's impairment integrates all three hypotheses. I propose that because of her IC lesion, her auditory cortices receive less auditory input than healthy individuals. As a consequence, the auditory cortices don't detect acoustic properties that are required for further processing of auditory objects in the anterior auditory fields. This lack of detection of acoustic properties is evident in the EEG study, as changes in the frequency or duration of sounds did not evoke MMN response. The lack of detection of acoustic properties then resulted in the lack of recruitment of the anterior auditory cortices when attempting to discriminate meaningful sounds. This lack of recruitment is evident in the fMRI study, in which LM's anterior auditory fields responded weakly to sounds.

8.2 Auditory Agnosia Patients Perceive Sounds Via the Auditory Dorsal Stream:

Cerebral deafness is deafness that occurs after bilateral temporal damage (Polster and Rose, 1988). AA patients differ from cerebral deafness patients in that some of their hearing is preserved. They can detect sounds, but discrimination and identification of sounds is impaired. It is not yet known which acoustic properties are spared in AA. In this chapter I argue that LM's remaining auditory perception is processed in the pSTG, which is part of the auditory dorsal stream. I also propose that the auditory dorsal stream is responsible for the remaining auditory perception of other AA patients.

In chapter 2, I presented evidence that the auditory dorsal stream processes a varied range of functions in humans, such as audio-visual integration, sound localization and the analysis of acoustic/phonological properties of spoken words. Below I demonstrate that these functions correspond with LM's spared hearing abilities. Based on the similarity of her symptoms to the symptoms of AA patients who suffer cerebral damage, I further hypothesize that in most AA patients, the pSTG (unilaterally or bilaterally) is spared.

The most prominent evidence that the right auditory dorsal stream is responsible for LM's spared auditory abilities is demonstrated in the dichotic listening task (chapter 5.2.4) and the auditory localization task (chapter 5.2.5). In the dichotic listening task, in which a different sound was presented simultaneously to each ear, LM was shown to extinguish sounds arriving at the right ear. This finding suggests that it is the auditory cortex in the left hemisphere that is dysfunctional and thus it is the auditory cortex of the right hemisphere that mediates

LM's remaining auditory perception. In the auditory localization study, LM was shown to perceive all sounds as emanating from the left auditory hemi-field, which also indicates of spared auditory processing in her right auditory cortex. Using electrophysiological recordings from the auditory cortices of monkeys it was shown that sound localization is processed in the posterior, but not anterior, auditory cortices, with each auditory cortex localizing sounds to the contralateral hemi-field (Benson et al., 1981; Rauschecker and Tian, 1995, 2000; Harrington et al., 2002; Woods et al., 2006; Miller and Recanzone, 2009). Accordingly, functional imaging studies in humans also showed that the contralateral pSTG is the area most active, when participants are instructed to localize sounds (Weeks et al., 1999; Baumgart et al., 1999; Warren et al., 2002; Warren and Griffiths, 2003; Hart et al., 2004; Krumbholtz et al., 2005; Tata et al., 2005; Isenberg et al., 2012). Based on these findings, I suggest that LM's left hemi-field localization is due to processing in her right pSTG.

Evidence that LM's spared auditory perception is lateralized to the right pSTG is also demonstrated in the fMRI study (chapter 6). When LM heard meaningful sounds, although her anterior auditory cortices responded to sounds very weakly, there was strong BOLD activation in the mSTG and pSTG. In the first fMRI scan, the pSTG in the right hemisphere, but not in the left, was activated. In the second scan, a year later, although both pSTG regions were responsive to sounds, the right pSTG was slightly more active. These findings therefore suggest that her right and left pSTG-mSTG are the areas most responsive to sounds, with the right auditory fields showing more consistent activation.

In the spoken word recognition test, LM committed 4 errors. In all cases, LM confused the spoken word with a word that has a similar phonological-acoustic structure (e.g., when heard the word 'lips' she chose the word 'hips' as the correct answer). Accordingly, in the open question section, after listening to the words 'Train' and

‘Shirt’ she typed the words ‘Turn’ and ‘Shout’, which are phonologically similar. In a prior pilot study, after listening to the word ‘donkey’ she typed the word ‘knock’, which is also phonologically similar. Evidence for the association of LM’s ability to match phonologically-acoustically similar spoken and written words, with spared auditory processing in the right posterior auditory areas, is supported by several studies of healthy individuals. Priming studies, in which auditory word presentation interferes with the process of matching an object drawing to its written word, have shown that semantically related auditory words suppress reading while phonologically related spoken words facilitates it (Damian and Bowers, 2009; Damian and Martin, 1999). Following this finding, functional imaging studies using the same protocol showed that this phonological facilitation is associated with BOLD reduction in the pSTG (Zubicaray and MacMahon, 2009; Also Bles and Jansma, 2008 for a similar picture-picture matching experiment). On this account, the authors concluded (Zubicaray and MacMahon, 2009) that this BOLD reduction is due to the sharing of neural resources in the pSTG when phonological matching between visual and auditory words occur. In another study, it was further shown that congruency between the matched orthographic and auditory representations have an effect on the type of activation in this region as well (van Atteveldt et al., 2007). In all these studies, the described pSTG was localized to the left hemisphere. However, in the dichotic listening task, LM was shown to hear predominantly the word presented to the left ear. Together, these findings suggest that in the case of LM, it was her right auditory cortex that facilitated the acoustic-phonological perception of words. This conclusion is consistent with an MEG study of healthy participants that correlated phonological analysis of spoken words with activity in the left and right hemispheres (with the left hemisphere doing so more efficiently; Uusvuori et al., 2007).

Additional evidence that LM’s spared auditory perception is due to processing in the pSTG is demonstrated by her ability to enhance speech comprehension by observing the speaker’s lip movements. Lip reading, when

combined with speech, is known as speech reading, and, in healthy people, enhances intelligibility (Sumbly and Pollack, 1954; Dodd, 1977) by correcting for acoustic errors (Erber, 1969; MacLeod and Summerfield, 1987; Sanders and Goodrich, 1971). Although LM's speech-reading ability was not directly tested, it is evident from her every day interaction with her family, and from her interaction with the research staff. She also reported to use it daily at her job as a tender in a family owned bar. Speech reading was reported to facilitate comprehension also in all other AA patients (chapter 4), and appears as a very consistent characteristic of this disorder (for empirical demonstrations in auditory agnosia and aphasia see: Oppenheimer and Newcombe, 1978; Kirshner and Webb, 1982; Auerbach et al., 1982; Weidner and Jinks, 1983; Metz-Lutz and Dahl, 1984; Shindo et al., 1991; Morris et al., 1996). Cumulative evidence indicates that speech reading is processed in the pSTG (Olson et al., 2002; Wright et al., 2003; Callan et al., 2004; Campanella and Bellin, 2007; Kreifelts et al., 2007; Brefczynski-Lewis et al., 2009; Okada and Hickok, 2009) and the neighboring posterior superior temporal sulcus (Calvert et al., 2001; Sekiyama et al., 2003; Miller and D'Esposito, 2005; Stevenson and James, 2009; Werner and Noppeney, 2009; Beauchamp et al., 2010; McGettigan et al., 2012). LM's processing of speech reading in the right pSTG is consistent with the result of an fMRI study of an aphasic patient with left pSTG damage that was shown to activate her right pSTG more than healthy controls when speech reading (Baum et al., 2012).

8.3 Auditory Agnosia as a Deficit in the Perception of Auditory

Objects:

In their seminal study, Veimeister and Wakefield (1991) presented healthy participants two short pulse sounds with an intermediate silent gap that lasted 5 ms or less. The researchers demonstrated that the longer the sound gap (i.e, closer to 5 ms), the lower is the minimal sound amplitude required for detection. They then showed that for gaps longer than 5-10 ms, there is no further reduction in the threshold level required for sound detection. Based on this finding the researchers inferred that the auditory system fractionate sounds into units of 5-10 ms duration. In a second experiment, the researchers presented healthy participants with two pulses separated by 100 ms gap of wide band noise. On some trials, one of the pulses was omitted. The study showed that the sound level required for detecting two pulses was lower than the sound level when only one of the pulse sounds was presented. This study therefore demonstrated that at the range of 100 ms there is integration of sounds into a unified auditory object. The researchers then concluded that during auditory perception there is segregation of sounds into temporal units with duration of 5-10 ms, and in parallel into temporal units with duration of 100 ms (or more) . The 5-10 ms segments were named 'looks', and the researchers hypothesized that the during the 100 ms period, the 'looks' are encoded in memory and then integrated to form the longer temporal units. This model is known as the multiple look model.

Similar to the auditory integration window of 100 ms reported by Veimeister and Wakefield (1991), the time frame of 100-300 ms also corresponded to observations in other auditory studies. For instance, in a seminal backward masking study, Massaro (1972) showed that a masking noise inserted between two monosyllabic words with similar vowels interfered with their discrimination only if the masking noise was shorter than 270

ms. Similarly, Wallace and Blumstein (2008) showed that speech and non-speech sounds of different durations can prime the identification of a vowel of the same duration and that this priming effect disappears for durations longer than 150 ms. With EEG, it was also shown that sounds differing in frequency elicit a mis-match negativity (MMN) response only if the inter-sound duration is 170 ms or less (Yabe et al., 2001). It is also interesting to note that the time frame of 100-300 ms corresponds to the duration of syllables (Greenberg, 2006; Studdert-Kennedy et al., 1970) and to the minimal required gap for perceiving syllables as separate (Repp, 1980). Taken together, these findings imply that during auditory perception, sounds are segmented into discrete units of 5-10 ms (e.g., phonemes). These units are further integrated into longer 100-300 ms segments, which could be viewed as auditory objects (e.g., syllables).

In the test that measured LM's ability to detect inter-click intervals (chapter 5.4.2), LM was only able to consistently perceive two sounds as distinct if the time gap was longer than 160 ms. Impairments of auditory temporal resolution of this severity (100-300 ms) have been reported in other patients with general AA (Buchtel and Stewart, 1989; Godefroy et al., 1995; Motomura et al., 1986— stage 1; Otsuki et al., 1998; Tanaka et al., 1987) and fluent aphasia (Carmon and Nachshon, 1971; De Renzi et al., 1989; Efron, 1963; Lackner and Teuber, 1973; Stefanatos et al., 2007). Demonstrating the relationship between temporal processing and AA are studies that tracked the recovery of AA patients and correlated improvement in the temporal discrimination of sounds with improvement in the resolution of the agnosic symptoms (Best and Howard, 1994; Godefroy et al., 1995; Motomura et al., 1986). As AA patients were shown to be capable of detecting sounds that are longer than this time frame, I propose that their ability to segregate sounds into 100-300 ms auditory objects is intact. However, as AA patients cannot detect shorter durations, I further propose that the primary deficit in AA is in the integration of short temporal segments (i.e., 'looks') into auditory objects. This conclusion is consistent with an in-

formal test, in which LM showed no difficulty tapping with her finger at the onset of each syllable when heard polysyllabic words. Deficit in the perception of the acoustic content of auditory objects is consistent with my previous association of AA with disruption to the auditory ventral streams, as fMRI studies directly correlated aSTG BOLD activation with the bottom-up construction of auditory objects (Scheich et al., 1998; Zatorre et al., 2004).

Supporting the hypothesis that AA is the result of loss to the temporal integration of segments of auditory objects are AA patients with very mild syndromes, such as patients with pure word deafness and AA for environmental sounds. When tested with the click-fusion test, pure word deafness patients were characterized by a deficit for very short durations (15-50 ms; Albert and Bear, 1974; Auerbach et al., 1982; Wang et al., 2000; Wolmetz et al., 2011; Yaqub et al., 1988), which correspond with the duration of consonants (Rosen, 1992). Similarly, in AA patients with specific impairment for environmental sounds but spared perception of words, discrimination of short durations was spared but impaired for the longer durations (50-200 ms; Motomura et al., 1986— stage 2; The environmental sound AA patient of Lambert et al., 1989 was shown capable of detecting 10 ms gaps). Although, such unique auditory temporal discrimination should be verified in future environmental sound AA patients before considered valid, this finding could suggest that in such patients the integration of sounds into temporal units lasting 5-10 ms is intact and that their deficit is due to impaired integration of these units into 100-300 ms auditory objects.

8.4 Auditory Agnosia as an Auditory Temporal discrimination

Deficit:

In the visual and somato-sensory modalities, the perception of objects is dependent on the analysis of spatial, but not temporal, properties (e.g., a ball can be recognized visually by analyzing the spatial arrangement of its contours in a single time point). The auditory modality differs from the visual and somato-sensory modalities because objects are defined primarily by their pattern of change in time (e.g., changing the presentation order of syllables in a word can alter the word's meaning). As described earlier (chapter 2, chapter 8.3), a common characteristic of AA patients is a deficit in the detection of time gaps between sounds (measured with the click fusion test), which suggests a reduction in auditory temporal resolution (Albert and Bear, 1974). On two accounts AA patients were also characterized by a visual temporal discrimination deficit in addition to auditory temporal discrimination deficit (Best and Howard, 1994; Tanaka et al., 1987). On that account, Best and Howard (1994) hypothesized that AA isn't due to loss of auditory temporal resolution but to a loss of a more general perception in time.

In chapter 5.2.2, I've demonstrated that LM is impaired at the detection of short time intervals when presented in the auditory modality but not in the visual modality. This finding is consistent with the findings of the VOT-POA discrimination. In this study, LM was especially impaired at discriminating VOT, which is a speech feature that is distinguishable only on the basis of temporal analysis. This finding is also consistent with the results of the MMN study because no MMN was observed when the deviant sound differed from the standard by its dura-

tion. LM's spared ability of discriminating visual time gaps, and her impaired ability at discriminating auditory time gaps, is in contradiction to the hypothesis that AA is due to general perception of time, proposed by Best and Howard (1995). Supporting the conclusion that AA isn't due to general loss of time perception is a study of aphasics patients, that demonstrated temporal discrimination deficit in the auditory, but not visual, modality (Ilmberger, 1984).

8.5 Assessment of Auditory Agnosia:

The present study has implications regarding the best approach to assessing future cases of AA. In past case studies, diagnosis of AA was done by either instructing patients to match sounds to their corresponding pictures in a multiple-choice format or to describe (orally or in writing) the meaning of sounds. However, only on rare occasions both tests were administered (Eustache et al., 1990; Maneta, 2001; Miceli, 1982; Pinard et al., 2002). In the current research (section 5.2.1), I directly compared between-sound identification with open-ended response and multiple-choice and showed that the two tests are not interchangeable. Thus, preferring one test to the other could lead to inadequate understanding of the patient's deficit. One noticeable consequence of this inconsistency in the literature is the over-diagnosis of patients with word deafness. This occurred because AA for environmental sounds was almost solely measured using sound-to-picture matching tests (multiple choice), whereas diagnosis for AA for verbal sounds (i.e., word deafness) was based on the patient's inability to participate in conversations. Based on the findings presented herein, I recommend that diagnosis of future AA patients should be conducted with both identification and recognition tests.

8.6 Functional Connectivity in the Auditory Cortex:

In addition to providing insight into the nature of AA, studying LM also has the potential of shedding new light on the organization of the human auditory cortex. In the fMRI study (chapter 6), when control participants passively listened to sounds, all the auditory fields in their auditory cortices became active. In contrast, when LM was passively listening to sounds, there was circumscribed bilateral activation in the primary auditory fields hA1 and associative auditory fields pSTG-mSTG, whereas her auditory fields hR and aSTG were only weakly responsive bilaterally (Figure 10, 11). In Chapter 2, I cite evidence from monkey and humans of connectivity between area A1/hA1 and the posterior auditory cortex, and area R/hR and anterior auditory cortex. I interpret the current BOLD activation pattern as supporting evidence of the connectivity between areas hR-aSTG and hA1-pSTG in humans. Corroborating the dual parallel hA1-pSTG hR-aSTG processing streams in humans are also other auditory fMRI studies that reported contiguous activation along areas hR-aSTG and separate contiguous activation along areas hA1-mSTG/pSTG (Brechmann et al., 2002; Di Salle et al., 2001; Hashimoto et al., 2000; Langers et al., 2007; Patterson et al., 2002; Scheich et al., 1998; Schönwiesner et al., 2002).

8.7 Concluding Notes and Future research:

In this dissertation I examined with fMRI, EEG and behavioral tools an AA patient who suffered damage to the dorsal midbrain and as a result acquired AA. Given the similarity in symptoms between this patient and patients who suffer bilateral temporal lobe damage I've reached several conclusions regarding the etiology and neuroanatomical correlates of this disorder. The primary conclusion of this study is that AA is the result of losing the ability to detect changes in sound duration and frequency, which are critical early stages in sound recognition. This processing occurs in the anterior auditory fields of both hemispheres in healthy people, and I propose that AA manifests when these regions malfunction or are not recruited. I also demonstrate that spared auditory abilities of AA patients correspond with known functions of the pSTG (e.g., speech reading, sound localization), and propose that the pSTG is unilaterally or bilaterally spared or recovered in AA patients. Based on present and past AA patients' deficit in perceiving inter-sound intervals I further propose that AA patients are capable of segregating continuous sounds into 100-300 ms auditory objects, and that their deficit is in the perception of the acoustic details of each auditory object. I also show that this disorder is limited to the auditory modality, thus arguing against an existing model that views AA as a general loss of temporal resolution. Finally, because AA in the past was diagnosed in a very unsystematic manner, I propose a new diagnostic criteria for AA, which include both sound recognition and identification.

The primary weakness of the the present study, is that the data was collected from a single patient, and therefore the findings presented here need to be replicated with future AA patients. An experiment that can help verify the etiology of AA is mis-match negativity. In AA patients, even with cerebral origin, I predict that mis-match negativity for changes in sound duration and frequency will be reported bilaterally, but not sound intensity. In rare

cases of AA patients with no cortical damage, I propose further exploration of the neuroanatomical correlates of AA using functional imaging, and predict reduced activation in the anterior auditory fields of both hemispheres. Studies using trans-magnetic stimulation to different auditory fields can also potentially help demonstrate contribution of the anterior auditory fields for the manifestation of AA symptoms.

Chapter 9

Appendix A

List of patients with Inferior Colliculi Damage

| | Auditory deficit | etiology | Side of lesion | BAEP | Citation |
|---|-------------------------|---|-----------------------|--|--|
| 1 | Word deafness | Surgical removal of tectal plate glioma | bilateral | Intact | Meyer, B., Kral, T., and Zentner, J. (1996). Pure word deafness after resection of a tectal plate glioma with preservation of wave V of brain stem auditory evoked potentials. <i>J. Neurol. Neurosurg. Psychiatr.</i> 61, 423–424. |
| 2 | General AA | Hematoma | bilateral | bilateral reduced and prolonged wave V | Johkura, K., Matsumoto, S., Hasegawa, O., and Kuroiwa, Y. (1998). Defective auditory recognition after small hemorrhage in the inferior colliculi. <i>J. Neurol. Sci.</i> 161, 91–96. |
| 3 | General AA | Lymphoma | bilateral | | Hoistad, D.L., and Hain, T.C. (2003). Central hearing loss with a bilateral inferior colliculus lesion. <i>Audiol. Neurootol.</i> 8, 111–113. |
| 4 | General AA | Hemorrhage | bilateral | Intact | Kimiskidis, V.K., Lalaki, P., Papagiannopoulos, S., Tsitouridis, I., Tolika, T., Serasli, E., Kazis, D., Tsara, V., Tsalighopoulos, M.G., and Kazis, A. (2004). Sensorineural hearing loss and word deafness caused by a mesencephalic lesion: clinicoelectrophysiologic correlations. <i>Otol. Neurotol.</i> 25, 178–182. |

| | | | | | |
|----|----------------|---|-----------|---|--|
| 5 | General AA | Tectal germinoma | bilateral | Wave V attenuated bilaterally. Wave V absent in 2.5 year later follow up | Pan, C.-L., Kuo, M.-F., and Hsieh, S.-T. (2004). Auditory agnosia caused by a tectal germinoma. <i>Neurology</i> 63, 2387–2389. |
| 6 | Deafness | Hemorrahge | bilateral | | Howe, J.R., and Miller, C.A. (1975). Midbrain deafness following head injury. <i>Neurology</i> 25, 286–289. |
| 7 | Deafness | Head trauma | bilateral | Wave V absent bilaterally | Jani, N.N., Laurenno, R., Mark, A.S., and Brewer, C.C. (1991). Deafness after bilateral midbrain contusion: a correlation of magnetic resonance imaging with auditory brain stem evoked responses. <i>Neurosurgery</i> 29, 106–8–discussion108–9. |
| 8 | Deafness | Hemorrahge | bilateral | Intact | Hu, C.J., Chan, K.Y., Lin, T.J., Hsiao, S.H., Chang, Y.M., and Sung, S.M. (1997). Traumatic brainstem deafness with normal brainstem auditory evoked potentials. <i>Neurology</i> 48, 1448–1451. |
| 9 | General AA | venous infarction of the two inferior colliculi | bilateral | Intact | Vitte, E., Tankéré, F., Bernat, I., Zouaoui, A., Lamas, G., and Soudant, J. (2002). Midbrain deafness with normal brainstem auditory evoked potentials. <i>Neurology</i> 58, 970–973. |
| 10 | General AA | Hemorrahge | bilateral | Intact | Vitte, E., Tankéré, F., Bernat, I., Zouaoui, A., Lamas, G., and Soudant, J. (2002). Midbrain deafness with normal brainstem auditory evoked potentials. <i>Neurology</i> 58, 970–973. |
| 11 | Deafness | compression by tumor (glioma) | bilateral | | Sloane P. (1943). Midbrain deafness. Tumor of the midbrain producing sudden and complete deafness. <i>Arch NeurPsych</i> 49, 237–243. |
| 12 | Deafness | Hemorrahge | bilateral | | Musiek, F.E., Charette, L., Morse, D., and Baran, J.A. (2004). Central Deafness Associated with a Midbrain Lesion. |
| 13 | Intact hearing | Surgical removal of tectal plate glioma | Left | Right ear stimulator resulted in reduced and delayed wave V. Interval waves I-V was augmented | Fischer, C., Bognar, L., Turjman, F., and Lapras, C. (1995). Auditory evoked potentials in a patient with a unilateral lesion of the inferior colliculus and medial geniculate body. <i>Electroencephalogr Clin Neurophysiol</i> 96, 261–267. |
| 14 | Intact hearing | Surgical removal after hemorrhage | Left | | Michela, A., Clarke, S., Bellmann, A., Maedert, P., Meulit, R., Thiranl, J.-P., Fornaris, E., and de Tribolet Nicolas (2001). Auditory localisation and recognition of work load on cortical activation patterns (fMRI study). <i>NeuroImage</i> 13. |
| 15 | Intact hearing | Surgical removal of tectal plate glioma | Right | Slight delay of wave V | Bognar, L., Turjman, F., Villanyi, E., Mottoliese, C., Guyotat, J., Fischer, C., Jouvot, A., and Lapras, C. (1994). Tectal plate gliomas. Part II: CT scans and MR imaging of tectal gliomas. <i>Acta Neurochir (Wien)</i> 127, 48–54. |

| | | | | | |
|----|---------------------------------|------------------------------------|---------------------------------|--|---|
| 16 | Intact hearing | Hemorrhage | Right | Delay of Wave V to left ear stimulation | Durrant, J.D., Martin, W.H., Hirsch, B., and Schwegler, J. (1994). 3CLT ABR analyses in a human subject with unilateral extirpation of the inferior colliculus. <i>Hear. Res.</i> 72, 99–107. |
| 17 | Intact hearing | Venous congestion in the caudal IC | Right | Delay of waves III-V | Strauss, C., Naraghi, R., Bischoff, B., Huk, W.J., and Romstöck, J. (2000). Contralateral hearing loss as an effect of venous congestion at the ipsilateral inferior colliculus after microvascular decompression: Report of a case. <i>J. Neurol. Neurosurg. Psychiatr.</i> 69, 679–682. |
| 18 | Intact hearing | Hemorrhage | Right | Reduced wave V for left ear stimulation | Litovsky, R.Y., Fligor, B.J., and Tramo, M.J. (2002). Functional role of the human inferior colliculus in binaural hearing. <i>Hear. Res.</i> 165, 177–188. |
| 19 | Intact hearing | Hemorrhage | Right | | Champoux, F., Paiement, P., Mercier, C., Lepore, F., Lassonde, M., and Gagné, J.P. (2007). Auditory processing in a patient with a unilateral lesion of the inferior colliculus. <i>European Journal of Neuroscience</i> 25, 291–297. |
| 20 | General AA that lasted 3 weeks. | Surgical removal of glial tumor | Right | Delayed wave V for right ear stimulation | Fischer, C., Bognar, L., Turjman, F., Villanyi, E., and Lapras, C. (1994). Auditory early-and middle-latency evoked potentials in patients with quadrigeminal plate tumors. <i>Neurosurgery</i> 35, 45–51. |
| 21 | Intact hearing | Surgical removal of glial tumor | Right | Delayed wave V bilaterally | Fischer, C., Bognar, L., Turjman, F., Villanyi, E., and Lapras, C. (1994). Auditory early-and middle-latency evoked potentials in patients with quadrigeminal plate tumors. <i>Neurosurgery</i> 35, 45–51. |
| 22 | Intact hearing | Surgical removal of glial tumor | Right | I-V interval was bilaterally increased | Fischer, C., Bognar, L., Turjman, F., Villanyi, E., and Lapras, C. (1994). Auditory early-and middle-latency evoked potentials in patients with quadrigeminal plate tumors. <i>Neurosurgery</i> 35, 45–51. |
| 23 | Intact hearing | Surgical removal of glial tumor | Right Brachium of IC damage | Wave V was slightly delayed unilaterally | Fischer, C., Bognar, L., Turjman, F., Villanyi, E., and Lapras, C. (1994). Auditory early-and middle-latency evoked potentials in patients with quadrigeminal plate tumors. <i>Neurosurgery</i> 35, 45–51. |
| 24 | Intact hearing | Surgical removal of glial tumor | Bilateral (partial damage) | | Fischer, C., Bognar, L., Turjman, F., Villanyi, E., and Lapras, C. (1994). Auditory early-and middle-latency evoked potentials in patients with quadrigeminal plate tumors. <i>Neurosurgery</i> 35, 45–51. |
| 25 | Intact hearing | Surgical removal of glial tumor | Right | Delayed and reduced wave V only after left ear stimulation | Fischer, C., Bognar, L., Turjman, F., Villanyi, E., and Lapras, C. (1994). Auditory early-and middle-latency evoked potentials in patients with quadrigeminal plate tumors. <i>Neurosurgery</i> 35, 45–51. |
| 26 | Intact hearing | Surgical removal of glial tumor | Bilateral infiltration by tumor | Wave V intact | Fischer, C., Bognar, L., Turjman, F., Villanyi, E., and Lapras, C. (1994). Auditory early-and middle-latency evoked potentials in patients with quadrigeminal plate tumors. <i>Neurosurgery</i> 35, 45–51. |

| | | | | | |
|----|----------------|--|---------------------------------|--|---|
| 27 | General AA | Partial IC destruction during pineal tumor removal | Bilateral (partial damage) | Reduced amplitude for wave V | Masuda, S., Takeuchi, K., Tsuruoka, H., Ukai, K., and Sakakura, Y. (2000). Word deafness after resection of a pineal body tumor in the presence of normal wave latencies of the auditory brain stem response. <i>Ann. Otol. Rhinol. Laryngol.</i> 109, 1107–1112. |
| 28 | General AA | Hemorrhage | bilateral | Wave V absent bilaterally | Pillion, J.P. (2012). Speech Processing Disorder in Neural Hearing Loss. <i>Case Reports in Medicine</i> 2012, 1–7. |
| 29 | Hearing loss | Ischemia | Right | Increase latency of wave V and interval of waves III-V only after left ear stimulation | Cerrato, P., Lentini, A., Baima, C., Grasso, M., Azzaro, C., Bosco, G., Destefanis, E., Benna, P., Bergui, M., and Bergamasco, B. (2005). Hypogeusia and hearing loss in a patient with an inferior collicular infarction. <i>Neurology</i> 65, 1840–1841. |
| 30 | Deafness | tectal invasion by pineal tumor | Bilateral infiltration by tumor | | Horrax, G., and Bailey, P. (1925). Tumors of the pineal body. <i>Archives of Neurology & Psychiatry</i> 13: 423-467. |
| 31 | Deafness | tectal invasion by pineal tumor | Bilateral infiltration by tumor | | Horrax, G., and Bailey, P. (1925). Tumors of the pineal body. <i>Archives of Neurology & Psychiatry</i> 13: 423-467. |
| 32 | Hearing loss | tectal invasion by pineal tumor | Bilateral infiltration by tumor | | Horrax, G., and Bailey, P. (1925). Tumors of the pineal body. <i>Archives of Neurology & Psychiatry</i> 13: 423-467. |
| 33 | Hearing loss | tectal invasion by pineal tumor | Bilateral infiltration by tumor | | Horrax, G., and Bailey, P. (1925). Tumors of the pineal body. <i>Archives of Neurology & Psychiatry</i> 13: 423-467. |
| 34 | Deafness | tectal invasion by pineal tumor | Bilateral infiltration by tumor | | Horrax, G., and Bailey, P. (1925). Tumors of the pineal body. <i>Archives of Neurology & Psychiatry</i> 13: 423-467. |
| 35 | General AA | tectal invasion by pineal tumor | Bilateral | | DeMonte, F., Zelby, A.S., and al-Mefty, O. (1993). Hearing impairment resulting from a pineal region meningioma. <i>Neurosurgery</i> 32, 665–668. |
| 36 | Hearing loss | tectal invasion by pineal tumor | Bilateral | | Gaspar, N., Verschuur, A., Mercier, G., Couanet, D., Sainte-Rose, C., and Brugières, L. (2003). Reversible hearing loss associated with a malignant pineal germ cell tumor. Case report. <i>Journal of Neurosurgery</i> 99, 587–590. |
| 37 | Intact hearing | tectal invasion by pineal tumor | | | Lapras, C., Bognar, L., Turjman, F., Villanyi, E., Mottolese, C., Fischer, C., Jouvot, A., and Guyotat, J. (1994). Tectal plate gliomas. Part I: Microsurgery of the tectal plate gliomas. <i>Acta Neurochir (Wien)</i> 126, 76–83. |
| 38 | Intact hearing | Surgical removal of tectal plate glioma | | | Lapras, C., Bognar, L., Turjman, F., Villanyi, E., Mottolese, C., Fischer, C., Jouvot, A., and Guyotat, J. (1994). Tectal plate gliomas. Part I: Microsurgery of the tectal plate gliomas. <i>Acta Neurochir (Wien)</i> 126, 76–83. |

| | | | | | |
|----|----------------|---|---|---|---|
| 39 | Intact hearing | Surgical removal of tectal plate glioma | | | Lapras, C., Bogнар, L., Turjman, F., Villanyi, E., Mottolese, C., Fischer, C., Jouvеt, A., and Guyotat, J. (1994). Tectal plate gliomas. Part I: Microsurgery of the tectal plate gliomas. <i>Acta Neurochir (Wien)</i> 126, 76–83. |
| 40 | Intact hearing | Surgical removal of tectal plate glioma | | | Lapras, C., Bogнар, L., Turjman, F., Villanyi, E., Mottolese, C., Fischer, C., Jouvеt, A., and Guyotat, J. (1994). Tectal plate gliomas. Part I: Microsurgery of the tectal plate gliomas. <i>Acta Neurochir (Wien)</i> 126, 76–83. |
| 41 | Intact hearing | Surgical removal of tectal plate glioma | | | Lapras, C., Bogнар, L., Turjman, F., Villanyi, E., Mottolese, C., Fischer, C., Jouvеt, A., and Guyotat, J. (1994). Tectal plate gliomas. Part I: Microsurgery of the tectal plate gliomas. <i>Acta Neurochir (Wien)</i> 126, 76–83. |
| 42 | Intact hearing | Surgical removal of tectal plate glioma | | | Lapras, C., Bogнар, L., Turjman, F., Villanyi, E., Mottolese, C., Fischer, C., Jouvеt, A., and Guyotat, J. (1994). Tectal plate gliomas. Part I: Microsurgery of the tectal plate gliomas. <i>Acta Neurochir (Wien)</i> 126, 76–83. |
| 43 | Intact hearing | Surgical removal of tectal plate glioma | | | Lapras, C., Bogнар, L., Turjman, F., Villanyi, E., Mottolese, C., Fischer, C., Jouvеt, A., and Guyotat, J. (1994). Tectal plate gliomas. Part I: Microsurgery of the tectal plate gliomas. <i>Acta Neurochir (Wien)</i> 126, 76–83. |
| 44 | Intact hearing | Surgical removal of tectal plate glioma | ? | ? | Lapras, C., Bogнар, L., Turjman, F., Villanyi, E., Mottolese, C., Fischer, C., Jouvеt, A., and Guyotat, J. (1994). Tectal plate gliomas. Part I: Microsurgery of the tectal plate gliomas. <i>Acta Neurochir (Wien)</i> 126, 76–83. |
| 45 | Intact hearing | Surgical removal of tectal plate glioma | ? | ? | Lapras, C., Bogнар, L., Turjman, F., Villanyi, E., Mottolese, C., Fischer, C., Jouvеt, A., and Guyotat, J. (1994). Tectal plate gliomas. Part I: Microsurgery of the tectal plate gliomas. <i>Acta Neurochir (Wien)</i> 126, 76–83. |
| 46 | Intact hearing | Surgical removal of tectal plate glioma | ? | ? | Lapras, C., Bogнар, L., Turjman, F., Villanyi, E., Mottolese, C., Fischer, C., Jouvеt, A., and Guyotat, J. (1994). Tectal plate gliomas. Part I: Microsurgery of the tectal plate gliomas. <i>Acta Neurochir (Wien)</i> 126, 76–83. |
| 47 | Intact hearing | Surgical removal of tectal plate glioma | ? | ? | Lapras, C., Bogнар, L., Turjman, F., Villanyi, E., Mottolese, C., Fischer, C., Jouvеt, A., and Guyotat, J. (1994). Tectal plate gliomas. Part I: Microsurgery of the tectal plate gliomas. <i>Acta Neurochir (Wien)</i> 126, 76–83. |
| 48 | Intact hearing | Surgical removal of tectal plate glioma | ? | ? | Lapras, C., Bogнар, L., Turjman, F., Villanyi, E., Mottolese, C., Fischer, C., Jouvеt, A., and Guyotat, J. (1994). Tectal plate gliomas. Part I: Microsurgery of the tectal plate gliomas. <i>Acta Neurochir (Wien)</i> 126, 76–83. |
| 49 | Hearing loss | | | | Missori, P., Delfini, R., and Cantore, G. (1995). Tinnitus and hearing loss in pineal region tumours. <i>Acta Neurochir (Wien)</i> 135, 154–158. |

| | | | | | |
|----|--------------|--|--|-------------|--|
| 50 | Hearing loss | | | BAEP intact | Missori, P., Delfini, R., and Cantore, G. (1995). Tinnitus and hearing loss in pineal region tumours. <i>Acta Neurochir (Wien)</i> 135, 154–158. |
| 51 | Hearing loss | | | | Missori, P., Delfini, R., and Cantore, G. (1995). Tinnitus and hearing loss in pineal region tumours. <i>Acta Neurochir (Wien)</i> 135, 154–158. |

Chapter 10

Appendix B

List of patients with auditory impairment due to temporal lobe damage:

| Year | Age/ Sex | Etiology | Speech- comp | Speech- rep | E.Sound | Music | Initial Cond | Lesion | Citation |
|------|-------------|----------|-----------------|----------------|----------|----------|--------------|-----------|---|
| 2012 | 44F | CVA | Impaired | Partial | ? | ? | Wernicke A | Bilateral | Bormann, T., Weiller, C., 2012. "Are there lexicons?" A study of lexical and semantic processing in word-meaning deafness suggests "yes". <i>Cortex</i> ; 48(3):294–307. |
| 2012 | 55F | CVA | Deafness | Deafness | Deafness | Deafness | | | Cavinato, M., Rigon, J., Volpato, C., Semenza, C., Piccione, F. 2012. Preservation of auditory P300-like potentials in cortical deafness. <i>PLoS one</i> , 7(1), e29909. Semenza, C., Cavinato, M., Rigon, J., Battel, I., Meneghello, F., Venneri, A., 2012. Persistent cortical deafness: A voxel-based morphometry and tractography study. <i>Neuropsychology</i> 26, 675–683. |
| 2012 | 73M | CVA | Impaired | Impaired | Impaired | Impaired | | Left | Suh, H., Shin, Y.-I., Kim, S.Y., Kim, S.H., Chang, J.H., Shin, Y.B., Ko, H.-Y., 2012. A Case of Generalized Auditory Agnosia with Unilateral Subcortical Brain Lesion. <i>Ann Rehabil Med</i> 36, 866. |
| 2012 | 73F | CVA | Partial | Impaired | Impaired | ? | | Bilateral | Robson, H., Davies, S., Lambon Ralph, M.A., Sage, K., 2012. Facilitating and disrupting speech perception in word deafness. <i>Aphasiology</i> 26, 177–198. |

| | | | | | | | | | |
|------------|-----|---------------------------|----------|----------|-----------|-----------|-------------|-----------|---|
| 2012 ** | 64M | ? | Impaired | Impaired | Impaired | Intact | ? | Bilateral | Hasan, H., Mohammed, N., Hodgson, S., Yegappan, C., Noseworthy, M., Silva, J. 2012. Cortical Deafness: A Case of Selective Auditory Agnosia, Amusia and Word Deafness (P07.177). <i>Neurology</i> . |
| 2012 | 42M | CVA | Impaired | Impaired | ? | ? | | Bilateral | Burton, C. Chaudhuri, G. 2012. Management of Cortical Deafness: A Case Study. Presented at the Marianjoy Rehabilitation Hospital Professional Association Conference. |
| 2011 | 7F | Hydrocephalus | Partial | Partial | ? | ? | | Bilateral | Chou Y-T, Liao P-W, Lin MC-H, et al. Medulloblastoma Presenting With Pure Word Deafness: Report of One Case and Review of Literature. <i>Pediatrics and Neonatology</i> . 2011;52(5):290–293. doi:10.1016/j.pedneo.2011.06.009. |
| 2011 | 74M | CVA | Intact | Intact | Impaired | Impaired | | Left | Saygin, A.P., Leech, R., Dick, F., 2010. Nonverbal auditory agnosia with lesion to Wernicke's area. <i>Neuropsychologia</i> 48, 107–113. |
| 2011 | 27F | Hydrocephalus | Impaired | Impaired | Impaired | Partial | | Bilateral | Zhang, Q., Kaga, K., Hayashi, A., 2011. Auditory agnosia due to long-term severe hydrocephalus caused by spina bifida – specific auditory pathway versus nonspecific auditory pathway. <i>Acta Otolaryngol.</i> 131, 787–792. |
| 2011 | 68M | CVA | Impaired | Impaired | Intact | ? | Global A | Left | Wolmetz, M, Poeppel, D, Rapp, B. What does the right hemisphere know about phoneme categories?. <i>Journal of cognitive neuroscience</i> 23.3 (2011): 552-569. |
| 2011 | 59F | Dementia | Impaired | Impaired | Intact | Intact | | Bilateral | Kim, S. H., Suh, M. K., Seo, S. W., Chin, J., Han, S. H., & Na, D. L. 2011. Pure Word Deafness in a Patient with Early-Onset Alzheimer's Disease: An Unusual Presentation. <i>Journal of Clinical Neurology</i> , 7(4), 227-230. |
| 2010 | 19F | Extrapontine Myelinolysis | Impaired | Impaired | Recovered | Recovered | Deafness-AA | Bilateral | Zhu, R.-J., Lv, Z.-S., Shan, C.-L., Xu, M.-W., Luo, B.-Y., 2010. Pure word deafness associated with extrapontine myelinolysis. <i>J. Zhejiang Univ. Sci. B</i> 11, 842–847. |
| 2010 | 66M | CVA | Impaired | Impaired | Partial | Partial | Wernicke A | Left | Slevc, L. Robert, et al. "Speech perception, rapid temporal processing, and the left hemisphere: a case study of unilateral pure word deafness." <i>Neuropsychologia</i> 49.2 (2011): 216-230. |
| 2008 | 71F | Dementia | Partial | Partial | Intact | Intact | | Bilateral | Jörgens, Silke, Katja Biermann-Ruben, Martin W. Kurz, Claudia Flügel, Kathinka Daehli Kurz, Christina Antke, Hans-Peter Hartung, Rüdiger J. Seitz, and Alfons Schnitzler. 2008. Word deafness as a cortical auditory processing deficit: a case report with MEG. <i>Neurocase</i> 14, no. 4: 307-316. |

| | | | | | | | | | |
|------------|-----|------------------|----------|----------|----------|----------|------------|-----------|---|
| 2007 | 65F | Vascular disease | Impaired | Partial | Impaired | Impaired | General AA | Bilateral | Tessier, C., Weill-Chounlamountry, A., Michelot, N., Pradat-Diehl, P. 2007. Rehabilitation of word deafness due to auditory analysis disorder. <i>Brain Injury</i> , 21(11), 1165-1174. |
| 2007 ** | 81F | CVA | Impaired | Impaired | Intact | Intact | | | Koyama, S., Shindou, J., Maruyama, J. 2007. A case of pure word deafness after cerebral hemorrhage. <i>Hokkaido igaku zasshi The Hokkaido journal of medical science</i> , 82(4), 213-216. |
| 2007 | 66M | Dementia | Impaired | Impaired | Intact | ? | | Bilateral | Iizuka, O., Suzuki, K., Endo, K., Fujii, T., Mori, E. 2007. Pure word deafness and pure anarthria in a patient with frontotemporal dementia. <i>European journal of neurology</i> , 14(4), 473-475. |
| 2007 | 59M | CVA | Impaired | Impaired | Intact | ? | | Left | Hayashi, K., Hayashi, R., 2007. Pure word deafness due to left subcortical lesion: neurophysiological studies of two patients. <i>Clin Neurophysiol</i> 118, 863–868. |
| 2007 | 59M | CVA | Impaired | Impaired | Intact | ? | | Bilateral | Hayashi, K., Hayashi, R., 2007. Pure word deafness due to left subcortical lesion: neurophysiological studies of two patients. <i>Clin Neurophysiol</i> 118, 863–868. |
| 2006 | 62F | CVA | Intact | Intact | Intact | Impaired | | Right | Terao Y, Mizuno T, Shindoh M, et al. 2006. Vocal amusia in a professional tango singer due to a right superior temporal cortex infarction. <i>Neuropsychologia</i> , 44(3):479–488. |
| 2006 | 25M | Head trauma | Impaired | Intact | ? | ? | | Bilateral | Wirkowski, E., Echausse, N., Overby, C., Ortiz, O., Radler, L., 2006. I can hear you yet cannot comprehend: A case of pure word deafness. <i>The Journal of Emergency Medicine</i> 30, 53–55. |
| 2006 | 73F | CVA | Impaired | Intact | ? | ? | | Left | Plasencia, P., Dorado, J., Serrano Rodriguez, J., Sellan, C. 2006. Neuropsychological evidence for “word-meaning deafness” in a Spanish-speaking patient. <i>Brain and Language</i> . 97(2):214–218. |
| 2005 | 70F | CVA | Intact | Intact | Intact | Impaired | Wernicke A | Bilateral | Satoh, M., Takeda, K., Murakami, Y., Onouchi, K., Inoue, K., & Kuzuhara, S. 2005. A case of amusia caused by the infarction of anterior portion of bilateral temporal lobes. <i>Cortex</i> , 41(1), 77-83. |
| 2005 | 12M | Head trauma | Impaired | Impaired | Intact | Impaired | Global A | Bilateral | Hattiangadi, N., Pillion, J., Slomine, B., Christensen, J., Trovato, M., Speedie, L. 2005. Characteristics of auditory agnosia in a child with severe traumatic brain injury: A case report. <i>Brain and Language</i> , 92(1):12–25. |

| | | | | | | | | | |
|------------|-----|----------------|----------|----------|----------|----------|---------------|-----------|---|
| 2005 | 53M | CVA | Impaired | Impaired | Impaired | Impaired | General AA | Bilateral | Kaga, K., Kurauchi, T., Nakamura, M., Shindo, M., Ishii, K., 2005. Magnetoencephalography and positron emission tomography studies of a patient with auditory agnosia caused by bilateral lesions confined to the auditory radiations. <i>Acta Otolaryngol.</i> 125, 1351–1355. |
| 2005 | 65M | Lithium intake | Impaired | Impaired | ? | ? | Confusion | ? | Donaldson, J.O., Hale, M.S., Klau, M., 2005. A case of reversible pure-word deafness during lithium toxicity. <i>Am J Psychiatry</i> 138, 242. |
| 2005 | 43F | CVA | Partial | Partial | Intact | Intact | General AA | Left | Stefanatos, G. A., Gershkoff, A., Madigan, S. 2005. On pure word deafness, temporal processing, and the left hemisphere. <i>Journal of the International Neuropsychological Society</i> , 11(04), 456-470. |
| 2004 | 52M | CVA | Intact | Intact | Intact | Partial | | Left | Griffiths, T. D., Warren, J.D., Dean, J.L., Howard, D. 2004. "When the feeling's gone": a selective loss of musical emotion. <i>J Neurol Neurosurg Psychiatr.</i> 75(2):344–345. |
| 2004 | 60M | Dementia | Intact | Intact | Impaired | Partial | | Right | Yamamoto, T., Kikuchi, T., Nagae, J., Ogata, K., Ogawa, M., & Kawai, M. 2004. [Dysprosody associated with environmental auditory sound agnosia in right temporal lobe hypoperfusion--a case report]. <i>Rinsho shinkeigaku Clinical neurology</i> , 44(1), 28-33. |
| 2004 | 48M | CVA | Intact | Intact | Intact | Partial | | Left | Di Pietro, M., Laganaro, M., Leemann, B., Schnider A. 2004. Receptive amusia: temporal auditory processing deficit in a professional musician following a left temporo-parietal lesion. <i>Neuropsychologia</i> . 42(7):868–877. |
| 2004 ** | | CVA | Intact | Intact | | Impaired | | Right | Murayama, J., Kashiwagi, T., Kashiwagi, A., & Mimura, M. 2004. Impaired pitch production and preserved rhythm production in a right brain-damaged patient with amusia. <i>Brain and Cognition</i> , 56(1), 36-42. |
| 2003 | 38M | CVA | Impaired | Impaired | Impaired | ? | General AA | Bilateral | Tanji, K., Suzuki, K., Okuda, J., Shimizu, H., Seki, H., Kimura, I., Endo, K., Hirayama, K., Fujii, T., Yamadori, A., 2003. Formant Interaction as a Cue to Vowel Perception: A Case Report. <i>Neurocase</i> 9, 350–355. |
| 2003 | 51M | CVA | Impaired | Impaired | Impaired | ? | Word deafness | Bilateral | Szirmai, I., Farsang, M., Csúri, M. 2003. Cortical auditory disorder caused by bilateral strategic cerebral bleedings. Analysis of two cases. <i>Brain and language</i> , 85(2), 159-165. |
| 2003 | 58M | CVA | Deafness | Deafness | Deafness | Deafness | Word deafness | Bilateral | Szirmai, I., Farsang, M., Csúri, M. 2003. Cortical auditory disorder caused by bilateral strategic cerebral bleedings. Analysis of two cases. <i>Brain and language</i> , 85(2), 159-165. |

| | | | | | | | | | |
|------------|-----|-----|----------|----------|----------|----------|-----------|-------|---|
| 2003 | 42M | CVA | Partial | Partial | ? | ? | - | Left | Jacobs, B., Schneider, S. 2003. Analysis of lexical-semantic processing and extensive neurological, electrophysiological, speech perception, and language evaluation following a unilateral left hemisphere lesion: Pure word deafness?. <i>Aphasiology</i> , 17(2), 123-141. |
| 2003 | 79M | CVA | Impaired | Impaired | Intact | ? | Dysphasia | Left | Maneta, Jane Marshall, Jayne Lindsay, A. 2001. Direct and indirect therapy for word sound deafness. <i>International Journal of Language & Communication Disorders</i> , 36(1), 91-106. |
| 2002 | 67M | CVA | Intact | Intact | Intact | Partial | | Right | Wilson, S. J., Pressing, J. L., & Wales, R. J. 2002. Modelling rhythmic function in a musician post-stroke. <i>Neuropsychologia</i> , 40(8), 1494-1505. |
| 2002 | 57M | CVA | Intact | ? | Impaired | ? | | Right | Tanaka, Y., Nakano, I., & Obayashi, T. (2002). Environmental sound recognition after unilateral subcortical lesions. <i>Cortex</i> , 38(1), 69-76. |
| 2002 | 58M | CVA | Intact | ? | Impaired | ? | | Right | Tanaka, Y., Nakano, I., & Obayashi, T. (2002). Environmental sound recognition after unilateral subcortical lesions. <i>Cortex</i> , 38(1), 69-76. |
| 2002 | 64M | CVA | Intact | ? | Impaired | ? | | Right | Tanaka, Y., Nakano, I., & Obayashi, T. (2002). Environmental sound recognition after unilateral subcortical lesions. <i>Cortex</i> , 38(1), 69-76. |
| 2002 | 59F | CVA | Intact | ? | Impaired | ? | | Right | Tanaka, Y., Nakano, I., & Obayashi, T. (2002). Environmental sound recognition after unilateral subcortical lesions. <i>Cortex</i> , 38(1), 69-76. |
| 2002 | 65F | CVA | Intact | ? | Impaired | ? | | Left | Tanaka, Y., Nakano, I., & Obayashi, T. (2002). Environmental sound recognition after unilateral subcortical lesions. <i>Cortex</i> , 38(1), 69-76. |
| 2002 | 62M | CVA | Intact | ? | Impaired | ? | | Left | Tanaka, Y., Nakano, I., & Obayashi, T. (2002). Environmental sound recognition after unilateral subcortical lesions. <i>Cortex</i> , 38(1), 69-76. |
| 2002 | 59F | CVA | Intact | ? | Impaired | ? | | Left | Tanaka, Y., Nakano, I., & Obayashi, T. (2002). Environmental sound recognition after unilateral subcortical lesions. <i>Cortex</i> , 38(1), 69-76. |
| 2002 | 47M | CVA | Intact | ? | Impaired | ? | | Left | Tanaka, Y., Nakano, I., & Obayashi, T. (2002). Environmental sound recognition after unilateral subcortical lesions. <i>Cortex</i> , 38(1), 69-76. |
| 2001 ** | | CVA | Intact | Intact | | Impaired | | Right | Steinke WR, Cuddy LL, Jakobson LS. Dissociations among functional subsystems governing melody recognition after right-hemisphere damage. <i>Cognitive neuropsychology</i> , 2001;18(5), 411-437. |

| | | | | | | | | | |
|------|-----|----------|----------|----------|----------|----------|-------------|-----------|--|
| 2001 | 42M | CVA | Partial | Partial | Intact | Intact | Wernicke A | | Nakakoshi, S., Kashino, M., Mizobuchi, A., Fukada, Y., & Katori, H. 2001. Disorder in sequential speech perception: A case study on pure word deafness. <i>Brain and language</i> , 76(2), 119-129. |
| 2001 | 50M | Tumor | Impaired | ? | Intact | ? | - | Bilateral | Shivashankar, N., Shashikala, H. R., Nagaraja, D., Jayakumar, P. N., Ratnavalli, E. 2001. Pure word deafness in two patients with subcortical lesions. <i>Clinical neurology and neurosurgery</i> , 103(4), 201-205. |
| 2001 | 24M | Tumor | Impaired | ? | Intact | ? | - | Bilateral | Shivashankar, N., Shashikala, H. R., Nagaraja, D., Jayakumar, P. N., Ratnavalli, E. 2001. Pure word deafness in two patients with subcortical lesions. <i>Clinical neurology and neurosurgery</i> , 103(4), 201-205. |
| 2001 | 68M | CVA | Partial | Partial | Partial | Intact | - | Right | Mendez, M.F. 2001. Generalized auditory agnosia with spared music recognition in a left-hander. Analysis of a case with a right temporal stroke. <i>Cortex</i> , 37(1), 139-150. |
| 2000 | 51F | CVA | Intact | Intact | Intact | Impaired | | Right | Ayotte, J., Peretz, I., Rousseau, I., Bard, C., Bojanowski, M. 2000. Patterns of music agnosia associated with middle cerebral artery infarcts. <i>Brain</i> , 123(9):1926–1938. |
| 2000 | 44M | CVA | Intact | Intact | Partial | Impaired | | Right | Ayotte, J., Peretz, I., Rousseau, I., Bard, C., Bojanowski, M. 2000. Patterns of music agnosia associated with middle cerebral artery infarcts. <i>Brain</i> , 123(9):1926–1938. |
| 2000 | 73F | Tumor | Impaired | Impaired | ? | ? | - | Bilateral | Karibe, H., T. Yonemori, F. Matsuno, O. Honmou, Y. Minamida, T. Uede, S. Tanabe, K. Hashi. 2000. A case of tentorial meningioma presented with pure word deafness. <i>No to shinkei Brain and nerve</i> 52, no. 11: 997-1001. |
| 2000 | 48M | Seizures | Impaired | ? | Partial | ? | | ? | Fung, V.S., Sue, C.M., Somerville, E.R. 2000. Paroxysmal word deafness secondary to focal epilepsy. <i>Neurology</i> , 54, 533–534. |
| 2000 | 26F | CVA | Deafness | Deafness | Deafness | Deafness | | | Garde, M., Cowey, A., 2000. "Deaf Hearing": Unacknowledged Detection of Auditory Stimuli in a Patient with Cerebral Deafness. <i>Cortex</i> 36, 71–79. |
| 2000 | 46F | CVA | Intact | Intact | Impaired | ? | Deafness-AA | Bilateral | Taniwaki, T., Tagawa, K., Sato, F., Iino, K. 2000. Auditory agnosia restricted to environmental sounds following cortical deafness and generalized auditory agnosia. <i>Clinical neurology and neurosurgery</i> , 102(3), 156-162. |
| 2000 | 37M | CVA | Impaired | Impaired | Impaired | Impaired | | Bilateral | Kaga, K., Shindo, M., Tanaka, Y., Haebara, H. 2000. Neuropathology of auditory agnosia following bilateral temporal lobe lesions: a case study. <i>Acta oto-laryngologica</i> , 120(2), 259-262. |

| | | | | | | | | | |
|------|-----|-------------|----------|----------|----------|----------|------------|-----------|---|
| 2000 | 31M | CVA | Impaired | Impaired | ? | ? | Confusion | Left | Wang, E., Peach, R. K., Xu, Y., Schneck, M., Manry II, C. 2000. Perception of dynamic acoustic patterns by an individual with unilateral verbal auditory agnosia. <i>Brain and language</i> , 73(3), 442-455. |
| 2000 | 54M | CVA | Partial | Partial | Impaired | ? | Wernicke A | Bilateral | Clarke, S., Bellmann, A., Meuli, R. A., Assal, G., Steck, A. J. 2000. Auditory agnosia and auditory spatial deficits following left hemispheric lesions: evidence for distinct processing pathways. <i>Neuropsychologia</i> , 38(6), 797-807. |
| 2000 | 62F | CVA | Intact | Intact | Impaired | ? | Wernicke A | Left | Clarke, S., Bellmann, A., Meuli, R. A., Assal, G., Steck, A. J. 2000. Auditory agnosia and auditory spatial deficits following left hemispheric lesions: evidence for distinct processing pathways. <i>Neuropsychologia</i> , 38(6), 797-807. |
| 2000 | 64F | CVA | Partial | Partial | Partial | ? | Wernicke A | Left | Clarke, S., Bellmann, A., Meuli, R. A., Assal, G., Steck, A. J. 2000. Auditory agnosia and auditory spatial deficits following left hemispheric lesions: evidence for distinct processing pathways. <i>Neuropsychologia</i> , 38(6), 797-807. |
| 2000 | 20M | | Intact | Intact | Intact | Impaired | Wernicke A | Left (S) | Piccirilli, M., Sciarma, T., Luzzi, S. 2000. Modularity of music: evidence from a case of pure amusia. <i>J Neurol Neurosurg Psychiatr.</i> 69(4):541-545. |
| 2000 | 22M | CVA | Deafness | Deafness | Deafness | Deafness | | Bilateral | Engelien, A., Huber, W., Silbersweig, D., Stern, E., Frith, C.D., Döring, W., Thron, A., Frackowiak, R.S., 2000. The neural correlates of "deaf-hearing" in man: conscious sensory awareness enabled by attentional modulation. <i>Brain</i> 123 Pt 3, 532-545. |
| 1999 | 46F | CVA | Impaired | Impaired | ? | Impaired | Wernicke A | Bilateral | Wee, J., Menard, M.R., 1999. "Pure word deafness": Implications for assessment and management in communication disorder—A report of two cases. <i>Archives of physical medicine and rehabilitation</i> 80, 1106-1109. |
| 1999 | 58M | CVA | Impaired | ? | ? | ? | Deafness | Bilateral | Verhagen W. I. M. , de Jong T. H. R. , Prick M. J. J. , de Bijl M. A.O. , van Dijk R. 1999. Word deafness - Case report. <i>Čes. a slov. Neurol. Neurochir.</i> , 62/95,, No. 5, p. 284-286. |
| 1999 | 71F | Head trauma | Impaired | ? | Partial | Impaired | - | Bilateral | Wee, J., Menard, M.R., 1999. "Pure word deafness": Implications for assessment and management in communication disorder—A report of two cases. <i>Archives of physical medicine and rehabilitation</i> 80, 1106-1109. |

| | | | | | | | | | |
|------|-----|-----|----------|----------|----------|----------|----------|-----------|--|
| 1999 | 51M | CVA | Deafness | Deafness | Deafness | Deafness | | Bilateral | Wakabayashi, Y., Nakano, T., Isono, M., Hori, S. 1999. Cortical deafness due to bilateral temporal subcortical hemorrhages associated with moyamoya disease: report of a case. <i>No shinkei geka. Neurological surgery</i> , 27(10), 915-919. |
| 1998 | 38F | CVA | Intact | Intact | Intact | Impaired | | Bilateral | Peretz, I., Gagnon, L., Bouchard, B. 1998. Music and emotion: perceptual determinants, immediacy, and isolation after brain damage. <i>Cognition</i> , 68(2): 111–141. |
| 1998 | 78M | CVA | Impaired | Impaired | Impaired | Impaired | Global A | Bilateral | Nové-Josserand, A., Fischer, C., Nighoghossian, N., Trouillas, P. 1998. Troubles perceptifs auditifs par lésion corticale bilatérale: Etude électrophysiologique. <i>Revue neurologique</i> , 154(4), 318-321. |
| 1998 | 63M | CVA | Intact | Intact | Impaired | Impaired | | Right | Johannes, S., Jöbges, M. E., Dengler, R., Münte, T. F. 1998. Cortical auditory disorders: a case of non-verbal disturbances assessed with event-related brain potentials. <i>Behav Neurol</i> , 11(1):55–73. |
| 1997 | 75M | CVA | Intact | Intact | Intact | Impaired | | Right | Griffiths, T. D., Rees, A., Witton, C., Cross, P. M., Shakir, R. A., Green, G. G. 1997 Spatial and temporal auditory processing deficits following right hemisphere infarction. A psychophysical study. <i>Brain</i> , 120 (Pt 5):785–794. |
| 1997 | 24F | CVA | Impaired | ? | Impaired | ? | ? | Bilateral | Kaga, K., Shindo, M., Tanaka, Y. 1997. Central auditory information processing in patients with bilateral auditory cortex lesions. <i>Acta Oto-Laryngologica</i> , 117(S532), 77-82. |
| 1997 | 53F | CVA | Impaired | ? | Impaired | ? | ? | Bilateral | Kaga, K., Shindo, M., Tanaka, Y. 1997. Central auditory information processing in patients with bilateral auditory cortex lesions. <i>Acta Oto-Laryngologica</i> , 117(S532), 77-82. |
| 1997 | 65M | CVA | Impaired | ? | Impaired | ? | ? | Bilateral | Kaga, K., Shindo, M., Tanaka, Y. 1997. Central auditory information processing in patients with bilateral auditory cortex lesions. <i>Acta Oto-Laryngologica</i> , 117(S532), 77-82. |
| 1997 | 75M | - | Impaired | ? | Impaired | ? | ? | Bilateral | Kaga, K., Shindo, M., Tanaka, Y. 1997. Central auditory information processing in patients with bilateral auditory cortex lesions. <i>Acta Oto-Laryngologica</i> , 117(S532), 77-82. |
| 1997 | 70M | - | Impaired | ? | Impaired | ? | ? | Bilateral | Kaga, K., Shindo, M., Tanaka, Y. 1997. Central auditory information processing in patients with bilateral auditory cortex lesions. <i>Acta Oto-Laryngologica</i> , 117(S532), 77-82. |

| | | | | | | | | | |
|------------|-----|----------|----------|----------|----------|----------|------------|-----------|--|
| 1997 | 25M | Tumor | Impaired | ? | Impaired | ? | ? | Bilateral | Kaga, K., Shindo, M., Tanaka, Y. 1997. Central auditory information processing in patients with bilateral auditory cortex lesions. <i>Acta Oto-Laryngologica</i> , 117(S532), 77-82. |
| 1997 ** | 66F | Dementia | Impaired | Impaired | | | | ? | Gold, M., Rojiani, A., Murtaugh, R. 1997. A 66-year-old woman with a rapidly progressing dementia and basal ganglia involvement. <i>Journal of neuroimaging: official journal of the American Society of Neuroimaging</i> , 7(3), 171-175. |
| 1997 | 64M | - | Impaired | ? | Impaired | ? | ? | Bilateral | Kaga, K., Shindo, M., Tanaka, Y. 1997. Central auditory information processing in patients with bilateral auditory cortex lesions. <i>Acta Oto-Laryngologica</i> , 117(S532), 77-82. |
| 1997 | 22M | Tumor | Impaired | ? | Impaired | ? | ? | Bilateral | Kaga, K., Shindo, M., Tanaka, Y. 1997. Central auditory information processing in patients with bilateral auditory cortex lesions. <i>Acta Oto-Laryngologica</i> , 117(S532), 77-82. |
| 1997 | 48F | | Impaired | ? | Impaired | ? | ? | Bilateral | Kaga, K., Shindo, M., Tanaka, Y. 1997. Central auditory information processing in patients with bilateral auditory cortex lesions. <i>Acta Oto-Laryngologica</i> , 117(S532), 77-82. |
| 1997 | 67M | CVA | Impaired | Intact | Intact | ? | ? | Left | Hall, D.A., Riddoch M.J. 1997. Word meaning deafness: Spelling words that are not understood. <i>Cognitive Neuropsychology</i> 14(8),1131–1164. Francis D.R., Riddoch M.J., Humphreys GW. 2001. Cognitive rehabilitation of word meaning deafness. <i>Aphasiology</i> 15(8),749–766. |
| 1997 | ? | | Impaired | ? | Impaired | ? | ? | Bilateral | Kaga, K., Shindo, M., Tanaka, Y. 1997. Central auditory information processing in patients with bilateral auditory cortex lesions. <i>Acta Oto-Laryngologica</i> , 117(S532), 77-82. |
| 1996 | 60M | CVA | Impaired | Intact | ? | ? | Wernicke A | Left | Franklin, S., Turner, J., Ralph, M. A. L., Morris, J., Bailey, P. J. 1996. A distinctive case of word meaning deafness? <i>Cognitive Neuropsychology</i> , 13(8):1139–1162. |
| 1995 | 63M | CVA | Impaired | Impaired | Intact | ? | - | Left | Anegawa, T., Hara, K., Yamamoto, K., Matsuda, M. 1995. Unilateral auditory hallucinations due to left temporal lobe ischemia: a case report. <i>Rinsho shinkeigaku Clinical neurology</i> , 35(10), 1137-1141. |
| 1995 | 55M | CVA | Partial | ? | Partial | Impaired | - | Bilateral | Ishii, K., Ueda, Y., Ohkoshi, N., Mizusawa, H., Shoji, S. I. 1995. Cortical auditory disorder caused by bilateral temporal infarctions. <i>Internal medicine (Tokyo, Japan)</i> , 34(8), 801-805. |

| | | | | | | | | | |
|------------|-----|----------------------------|----------|----------|----------|----------|-----------------------|-----------|---|
| 1995 | 44F | CVA | Intact | Intact | Impaired | Impaired | Mutism +General AA | Bilateral | Habib, M., Daquin, G., Milandre, L., Royere, M., Rey, M., Lanteri, A., Salamon, G., Khalil, R., 1995. Mutism and auditory agnosia due to bilateral insular damage--role of the insula in human communication. <i>Neuropsychologia</i> 33, 327–339. |
| 1995 | 58F | CVA | Impaired | Impaired | Impaired | Impaired | Deafness | Bilateral | Godefroy, O., Leys, D., Furby, A., De Reuck, J., Daems, C., Rondepierre, P., Debachy, B., Deleume, J.F., Desaulty, A., 1995. Psychoacoustical deficits related to bilateral subcortical hemorrhages. A case with apperceptive auditory agnosia. <i>Cortex</i> 31, 149–159. |
| 1995 | 52M | CVA | Impaired | Impaired | Partial | ? | General AA | Bilateral | Engelien, A., Silbersweig, D., Stern, E., Huber, W., Döring, W., Frith, C., Frackowiak, R.S., 1995. The functional anatomy of recovery from auditory agnosia. A PET study of sound categorization in a neurological patient and normal controls. <i>Brain</i> 118 (Pt 6), 1395–1409. |
| 1995 | 40F | CVA | Impaired | Impaired | Intact | | - | Bilateral | Carmona C, Casado I, Fernandez-Rojas J, Garin J, Rayo JI. 1995. Verbal auditory agnosia: SPECT study of the brain. <i>Rev Neurol</i> ; 23: 1047–50. |
| 1995 | 17F | Prelingual Encephalitis | Impaired | Impaired | Intact | | | Bilateral | Arias, M., Requena, I., Ventura, M., Pereiro, I., Castro, A., Alvarez, A. 1995. A case of deaf–mutism as an expression of pure word deafness: neuroimaging and electrophysiological data. <i>European Journal of Neurology</i> , 2(6), 583-585. |
| 1995 ** | ?M | CVA | Impaired | Impaired | ? | Impaired | | Left | Ohnaka, K., Sakurai, Y., Fuse, S., Shimpo, T., Kaga, K. 1995. Pure word deafness after cerebral hemorrhage in the left temporal lobe: a case report. <i>Rinsho shinkeigaku Clinical neurology</i> , 35(3), 290-295. |
| 1994 | 51F | CVA | Partial | Partial | Partial | ? | | Bilateral | Best, W., Howard, D., 1994. Word sound deafness resolved? <i>Aphasiology</i> 8, 223–256. |
| 1994 | | CVA | Deafness | Deafness | Deafness | Deafness | | Bilateral | Hood, L. J., Berlin, C. I., Allen, P. 1994. Cortical deafness: a longitudinal study. <i>Journal of the American Academy of Audiology</i> , 5(5), 330-342. |
| 1994 | 75F | CVA | Intact | Intact | Impaired | | General AA | | De La Sayette, V., Dupuy, B., Eustache, F., Morin, I., Viader, F., Morin, P., Lechevalier, B. 1993. Multimodal or multisensorial agnosia?. <i>Revue neurologique</i> , 150(5), 346-353. |
| 1994 | 35F | CVA | Intact | Intact | Intact | Impaired | | Bilateral | Peretz, I., Kolinsky, R., Tramo, M., et al. 1994. Functional dissociations following bilateral lesions of auditory cortex. <i>Brain</i> , 117(6):1283–1301. |
| 1994 | 61M | CVA | Intact | Intact | Intact | Impaired | | Bilateral | Peretz, I., Kolinsky, R., Tramo, M., et al. 1994. Functional dissociations following bilateral lesions of auditory cortex. <i>Brain</i> , 117(6):1283–1301. |

| | | | | | | | | | |
|------------|-----|----------|-----------------------|----------|-----------------------|----------|----------------------|-----------|--|
| 1994 | 54M | CVA | Partial | Partial | ? | ? | | Left | Franklin, S., Howard, D. 1994. Patterson K. Abstract word meaning deafness. <i>Cognitive Neuropsychology</i> , 11(1):1–34. |
| 1993 | | CVA | Deafness | Deafness | Deafness | Deafness | Wernicke A+ mutism | Bilateral | De Bijl M., De Jong, J.R.H., Verhagen, W.I.M., Prick, M.J.J., Van Dijk, R. 1993. Pure word-deafness in a patient with bilateral cerebral organization for language. <i>Journal of Clinical and Experimental Neuropsychology</i> , 15, 395. |
| 1993 ** | 56F | CVA | Impaired | Impaired | | | Deafness | Bilateral | Nishioka, H., Takeda, Y., Koba, T., Yano, J., Ohiwa, Y., Haraoka, J., & Ito, H. 1993. A case of cortical deafness with bilateral putaminal hemorrhage. <i>No shinkei geka. Neurological surgery</i> , 21(3), 269-272. |
| 1993 | | | Intact | Intact | Impaired | ? | | | Baddeley, A., Wilson, B. A. 1993. A case of word deafness with preserved span: Implications for the structure and function of short-term memory. <i>Cortex</i> , 29(4), 741-748. |
| 1992 | 55M | CVA | Impaired | Impaired | Intact | Intact | - | Left | Takahashi, N., Kawamura, M., Shinotou, H., Hirayama, K., Kaga, K., Shindo, M., 1992. Pure word deafness due to left hemisphere damage. <i>Cortex</i> 28, 295–303. |
| 1992 | 61M | CVA | Impaired | Impaired | ? | ? | | Bilateral | Di Giovanni, M., D'Alessandro, G., Baldini, S., Cantalupi, D., Bottacchi, E. 1992. Clinical and neuroradiological findings in a case of pure word deafness. <i>The Italian Journal of Neurological Sciences</i> , 13(6), 507-510. |
| 1992 ** | ?F | Dementia | Intact | Intact | | Impaired | | Right | Confavreux, C., Croisile, B., Garassus, P., Aimard, G., Trillet, M. 1992. Progressive amusia and aprosody. <i>Archives of Neurology</i> , 49(9), 971-976. |
| 1991 | 77F | CVA | Intact | Intact | Impaired | ? | - | Right | Fujii, T., Fukatsu, R., Watabe, S., Ohnuma, A., Teramura, K., Kimura, I., Saso, S., Kogure, K., 1990. Auditory sound agnosia without aphasia following a right temporal lobe lesion. <i>Cortex</i> 26, 263–268. |
| 1991 | 65F | CVA | Impaired | ? | ? | | | Left (S) | Mendez, M. F., Rosenberg, S. 1991. Word deafness mistaken for Alzheimer's disease: Differential characteristics. <i>Journal of the American Geriatrics Society</i> . |
| 1991 | 61M | CVA | Impaired | ? | ? | ? | - | Bilateral | Di Giovanni, M., D'Alessandro, G., Baldini, S., Cantalupi, D., Bottacchi, E., 1992. Clinical and neuroradiological findings in a case of pure word deafness. <i>Ital J Neurol Sci</i> 13, 507–510. |
| 1991 | 33M | CVA | Impaired in right ear | ? | Impaired in right ear | ? | Right ear extinction | Left | Pasquier, F., Leys, D., Steinling, M., Guieu, J.D., Petit, H., Cambier, J., 1991. Right unilateral auditory agnosia following left lenticular hemorrhage. <i>Rev. Neurol. (Paris)</i> 147, 129–137. |

| | | | | | | | | | |
|--------|-----|-------------|----------|----------|----------|----------|------------|-----------|---|
| 1991 | 48M | CVA | Deafness | Deafness | Deafness | Deafness | - | Bilateral | Tanaka, Y., Kamo, T., Yoshida, M., Yamadori, A. 1991. 'So-called cortical deafness, Clinical, Neuropsychological and Radiological observations. <i>Brain</i> , 114(6), 2385-2401. |
| 1991 | 38M | CVA | Deafness | Deafness | Deafness | Deafness | Wernicke A | Bilateral | Tanaka, Y., Kamo, T., Yoshida, M., Yamadori, A. 1991. 'So-called cortical deafness, Clinical, Neuropsychological and Radiological observations. <i>Brain</i> , 114(6), 2385-2401. |
| 1991 | 24F | CVA | Impaired | ? | ? | ? | - | Bilateral | Shindo, M., Kaga, K., Tanaka, Y. 1991. Speech discrimination and lip reading in patients with word deafness or auditory agnosia. <i>Brain and language</i> , 40(2), 153-161. |
| 1991 | 53F | CVA | Impaired | ? | ? | ? | - | Left | Shindo, M., Kaga, K., Tanaka, Y. 1991. Speech discrimination and lip reading in patients with word deafness or auditory agnosia. <i>Brain and language</i> , 40(2), 153-161. |
| 1991 | 65M | CVA | Impaired | ? | ? | ? | - | Bilateral | Shindo, M., Kaga, K., Tanaka, Y. 1991. Speech discrimination and lip reading in patients with word deafness or auditory agnosia. <i>Brain and language</i> , 40(2), 153-161. |
| 1991 | 55M | CVA | Impaired | ? | ? | ? | - | Left | Shindo, M., Kaga, K., Tanaka, Y. 1991. Speech discrimination and lip reading in patients with word deafness or auditory agnosia. <i>Brain and language</i> , 40(2), 153-161. |
| 1991 | 30M | ? | Impaired | ? | ? | ? | - | ? | Seliger, G.M., Lefever, F., Lukas, R., Chen, J., Schwartz, S., Codeghini, L., Abrams, G. 1991. Word deafness in head injury: implications for coma assessment and rehabilitation. <i>Brain Injury</i> , 5, 53-56. |
| 1991 | 38M | Head trauma | Impaired | ? | ? | ? | - | Bilateral | Seliger, G.M., Lefever, F., Lukas, R., Chen, J., Schwartz, S., Codeghini, L., Abrams, G. 1991. Word deafness in head injury: implications for coma assessment and rehabilitation. <i>Brain Injury</i> , 5, 53-56. |
| 1991 | 57M | CVA | Impaired | Impaired | Impaired | | Wernicke A | Bilateral | Praamstra, P., Hagoort, P., Maassen, B., Crul, T. 1991. Word deafness and auditory cortical function a case history and hypothesis. <i>Brain</i> , 114(3), 1197-1225. |
| 1990** | | | Impaired | | | | | Bilateral | Mark, V. W., and K. L. Chobor. 1990. Influences on the speech comprehension deficit in cortical auditory disorder. <i>Aphasiology</i> 4.6: 587-598. |
| 1990 | 41M | CVA | Impaired | Impaired | Impaired | ? | | Bilateral | Fechtelpeter, A., Göddenhenrich, S., Huber, W., Springer, L. 1990. Ansätze zur Therapie von auditiver Agnosie. <i>Folia Phoniatica et Logopaedica</i> , 42(2), 83-97. |
| 1990 | 65M | CVA | Impaired | ? | Intact | ? | | Bilateral | Wolberg, S. C., Temlett, J. A., Fritz, V. U. 1990. Pure word deafness. <i>South African Medical Journal</i> , 78, 668-670. |

| | | | | | | | | | |
|------------|-----|-----|----------|----------|----------|----------|-------------|-----------|---|
| 1990 | 28F | CVA | Impaired | ? | Intact | ? | | Bilateral | Wolberg, S. C., Temlett, J. A., Fritz, V. U. 1990. Pure word deafness. <i>South African Medical Journal</i> , 78, 668-670. |
| 1990 | 55M | CVA | Impaired | Impaired | Intact | Impaired | | Bilateral | Kitayama, I., Yamazaki, K., Shibahara, K., & Nomura, J. 1990. Pure word deafness with possible transfer of language dominance. <i>Psychiatry and Clinical Neurosciences</i> , 44(3), 577-584. |
| 1990 | 31M | CVA | Impaired | Impaired | Intact | Impaired | | Left | Eustache, F., Lechevalier, B., Viader, F., Lambert, J., 1990. Identification and discrimination disorders in auditory perception: a report on two cases. <i>Neuropsychologia</i> 28, 257-270. |
| 1990 | 64M | CVA | Intact | Intact | Impaired | Impaired | | Right | Eustache, F., Lechevalier, B., Viader, F., Lambert, J., 1990. Identification and discrimination disorders in auditory perception: a report on two cases. <i>Neuropsychologia</i> 28, 257-270. |
| 1990 | 66M | CVA | Partial | Impaired | Partial | Impaired | | Bilateral | Kazui, S., Naritomi, H., Sawada, T., Inoue, N., Okuda, J.I., 1990. Subcortical auditory agnosia. <i>Brain and Language</i> 38, 476-487. |
| 1990 ** | | | Intact | Intact | | Partial | | Right | Fries, W., & Swihart, A. A. 1990. Disturbance of rhythm sense following right hemisphere damage. <i>Neuropsychologia</i> , 28(12), 1317-1323. |
| 1989 | 53M | CVA | Impaired | Impaired | Impaired | Impaired | Deafness | Bilateral | Hasegawa, M., Bando, M., Iwata, M., Mannen, T., and Kaga, K. 1989. A case of auditory agnosia with the lesion of bilateral auditory radiation. <i>Rinsho Shinkeigaku</i> , 29: 180-185,. |
| 1989 ** | | | Intact | Intact | | Impaired | | Right | Chiba, A, Obi, T., Takeda, K., Sakuta, M., & Bandou, M. 1989. A case presenting with amusia after hemorrhage in the right putamen. <i>Rinshou Shinkeigaku</i> , 29, 536 |
| 1989 | 51M | CVA | Impaired | Impaired | Impaired | ? | Deafness | Bilateral | Buchtel, H. A., Stewart, J. D. 1989. Auditory agnosia: apperceptive or associative disorder?. <i>Brain and Language</i> , 37(1), 12-25. |
| 1989 | 28F | ? | Intact | Intact | Impaired | Impaired | General AA | ? | Lambert, J., Eustache, F., Lechevalier, B., Rossa, Y., Viader, F. 1989. Auditory agnosia with relative sparing of speech perception. <i>Cortex</i> , 25(1), 71-82. |
| 1988 | 60M | CVA | Impaired | Impaired | Impaired | Impaired | Deafness | Bilateral | Mendez, M. F., Geehan, G. R. 1988. Cortical auditory disorders: clinical and psychoacoustic features. <i>Journal of Neurology, Neurosurgery & Psychiatry</i> , 51(1), 1-9. |
| 1988 | 23M | CVA | Impaired | Impaired | Partial | Impaired | Deafness-AA | Bilateral | Mendez, M. F., Geehan, G. R. 1988. Cortical auditory disorders: clinical and psychoacoustic features. <i>Journal of Neurology, Neurosurgery & Psychiatry</i> , 51(1), 1-9. |

| | | | | | | | | | |
|------------|-----|---------|----------|----------|----------|----------|------------------------|-----------|--|
| 1988 | 38M | CVA | Impaired | Impaired | Intact | Intact | | Bilateral | Yaqub, B.A., Gascon, G.G., Al-Nosha, M., Whitaker, H., 1988. Pure word deafness (acquired verbal auditory agnosia) in an Arabic speaking patient. <i>Brain</i> 111 (Pt 2), 457–466. |
| 1988 | 61M | CVA | Deafness | Deafness | Deafness | Deafness | | Bilateral | Bahs, F. H., Chatrian, G. E., Mesher, R. A., Sumi, S. M., Ruff, R. L. 1988. A case of persistent cortical deafness. Clinical, neuro-physiologic, and neuropathologic observations. <i>Neurology</i> , 38(9), 1490-1490. |
| 1987 | 67F | CVA | Impaired | Impaired | Impaired | Impaired | Deafness | Bilateral | Ho, K. J., Kileny, P., Paccioretti, D., McLean, D. R. 1987. Neurologic, audiologic, and electrophysiologic sequelae of bilateral temporal lobe lesions. <i>Archives of neurology</i> , 44(9), 982-987. |
| 1987 | 61M | CVA | Impaired | Partial | Partial | Impaired | General AA | Right | Roberts, M., Sandercock, P., Ghadiali, E. 1987. Pure word deafness and unilateral right temporo-parietal lesions: a case report. <i>Journal of neurology, neurosurgery, and psychiatry</i> , 50(12), 1708. |
| 1987 ** | 67F | CVA | Impaired | Impaired | ? | ? | Deafness | Bilateral | Ho, K. J., Kileny, P., Paccioretti, D., McLean, D. R. 1987. Neurologic, audiologic, and electrophysiologic sequelae of bilateral temporal lobe lesions. <i>Archives of neurology</i> , 44(9), 982. |
| 1987 | 26F | CVA | Impaired | Impaired | Intact | ? | Wernicke A | Bilateral | Tanaka, Y., Yamadori, A., Mori, E., 1987. Pure word deafness following bilateral lesions. A psychophysical analysis. <i>Brain</i> 110, 381–403. |
| 1986 | 68M | CVA | Impaired | ? | Intact | ? | - | Left | Kanter, S.L., Day, A.L., Heilman, K.M., Gonzalez Rothi, L.J., 1986. Pure word deafness: a possible explanation of transient deteriorations after extracranial-intracranial bypass grafting. <i>Neurosurgery</i> 18, 186. |
| 1986 | 53M | CVA | Impaired | ? | ? | ? | - | Left | Kanter, S.L., Day, A.L., Heilman, K.M., Gonzalez Rothi, L.J., 1986. Pure word deafness: a possible explanation of transient deteriorations after extracranial-intracranial bypass grafting. <i>Neurosurgery</i> 18, 186. |
| 1986 | 64M | Seizure | Impaired | ? | ? | ? | Confusion | Left | Kanter, S.L., Day, A.L., Heilman, K.M., Gonzalez Rothi, L.J., 1986. Pure word deafness: a possible explanation of transient deteriorations after extracranial-intracranial bypass grafting. <i>Neurosurgery</i> 18, 186. |
| 1986 | 69M | CVA | Deafness | Deafness | Deafness | Deafness | Right ear hearing loss | Bilateral | Nakayama, T., Nobuoka, H., Wada, S., Matsukado, Y. 1986. [Cortical deafness following bilateral hypertensive putaminal hemorrhage]. <i>No to shinkei= Brain and nerve</i> , 38(6), 565-570. |

| | | | | | | | | | |
|------|-----|--------------|----------|----------|----------|----------|------------------------|-----------|--|
| 1986 | 75F | CVA | Partial | Partial | Intact | Intact | Confusion | Bilateral | Buchman, A. S., Garron, D. C., Trost-Cardamone, J. E., Wichter, M. D., Schwartz, M. 1986. Word deafness: one hundred years later. <i>Journal of Neurology, Neurosurgery & Psychiatry</i> , 49(5), 489-499. |
| 1986 | 62F | CVA | Partial | Partial | Partial | ? | | Bilateral | Buchman, A. S., Garron, D. C., Trost-Cardamone, J. E., Wichter, M. D., Schwartz, M. 1986. Word deafness: one hundred years later. <i>Journal of Neurology, Neurosurgery & Psychiatry</i> , 49(5), 489-499. |
| 1986 | 50F | Encephalitis | Impaired | Impaired | Impaired | ? | | Bilateral | Buchman, A. S., Garron, D. C., Trost-Cardamone, J. E., Wichter, M. D., Schwartz, M. 1986. Word deafness: one hundred years later. <i>Journal of Neurology, Neurosurgery & Psychiatry</i> , 49(5), 489-499. |
| 1986 | 69M | CVA | Intact | Intact | Impaired | ? | General AA | Bilateral | Motomura, N., Yamadori, A., Mori, E., Tamaru, F. 1986. Auditory agnosia analysis of a case with bilateral subcortical lesions. <i>Brain</i> , 109(3), 379-391. |
| 1986 | 53M | CVA | Partial | Partial | ? | ? | Wernicke A+mutism | Left | Kohn, S. E., Friedman, R. B. 1986. Word-meaning deafness: A phonological-semantic dissociation. <i>Cognitive Neuropsychology</i> , 3(3): 291-308. |
| 1986 | 64M | CVA | Impaired | Partial | ? | ? | Deafness +Mutism | Left | Kohn, S. E., Friedman, R. B. 1986. Word-meaning deafness: A phonological-semantic dissociation. <i>Cognitive Neuropsychology</i> , 3(3): 291-308. |
| 1985 | 49M | CVA | Impaired | Impaired | Intact | ? | Confusion | Bilateral | Brick, J. F., Frost, J. L., Schochet, S. S., Gutmann, L., Crosby, T. W. 1985. Pure word deafness CT localization of the pathology. <i>Neurology</i> , 35(3), 441-441. |
| 1985 | 62F | CVA | Impaired | Impaired | Impaired | ? | Wernicke A +General AA | Bilateral | Marshall, R. C., Rappaport, B. Z., Garcia-Bunuel, L. 1985. Self-monitoring behavior in a case of severe auditory agnosia with aphasia. <i>Brain and Language</i> , 24(2), 297-313. |
| 1984 | 33F | CVA | Impaired | Impaired | Impaired | Impaired | Deafness | Bilateral | Lechevalier, B., Rossa, Y., Eustache, F., Schupp, C., Boner, L., Bazin, C. (1984). Un cas de surdit  corticale  pargnant en partie la musique. <i>Revue neurologique</i> , 140(3), 190-201. |
| 1984 | 48M | CVA | Impaired | Partial | Intact | Partial | Confusion | Bilateral | Coslett, H. B., Brashear, H. R., Heilman, K. M. 1984. Pure word deafness after bilateral primary auditory cortex infarcts. <i>Neurology</i> , 34(3), 347-347. |
| 1984 | 24F | CVA | Impaired | Impaired | Intact | Intact | Wernicke A | Left | Metz-Lutz, M. N., Dahl, E. 1984. Analysis of word comprehension in a case of pure word deafness. <i>Brain and language</i> , 23(1), 13-25. |

| | | | | | | | | | |
|------------------|---------|----------|----------|----------|----------|----------|-------------------|-----------|--|
| 1984 | 82F | CVA | Impaired | Impaired | Impaired | ? | | Bilateral | Woods, D.L., Knight, R.T., Neville, H.J., 1984. Bitemporal lesions dissociate auditory evoked potentials and perception. <i>Electroencephalogr Clin Neurophysiol</i> 57, 208–220. |
| 1983 | 29F | CVA | Deafness | Deafness | Deafness | Deafness | | Bilateral | Rousseaux, M., Devos, P. 1983. Surdit , mutisme et troubles du comportement par l sions c r brales bitemporales. <i>Cortex</i> , 19(4), 557-568. |
| 1983 | 32F | CVA | Deafness | Deafness | Deafness | Deafness | | Bilateral | Nishikawa T, Taabushi K, Okuda J, Tanabe H, Shiraish JI. 1983. A case study of cortical deafness with reference to the active process in auditory perception. <i>Higher Brain Function Research. Tokyo</i> , 3, 24-37. |
| 1983 | 66M | CVA | Impaired | Impaired | Impaired | Impaired | Deafness | Bilateral | Burger, L.H., Wertz, R.T., Woods, D., 1983. A response to treatment in a case of cortical deafness. In <i>Clinical Aphasiology</i> . R.H. Brookshire (ed.): Conference proceedings, Minneapolis: BRK publishers. pp127-136. |
| 1983 (also 2002) | 23/38 F | Dementia | Impaired | Impaired | Impaired | Impaired | Word deafness | Diffuse | Pinard, M., Chertkow, H., Black, S., Peretz, I., 2002. A case study of pure word deafness: modularity in auditory processing? <i>Neurocase</i> 8, 40–55. Mesulam, M.M. 1982. Slowly progressive aphasia without generalized dementia. <i>Annals of Neurology</i> , 11, 592–598. sulam, M.M. 1982. Slowly progressive aphasia without generalized dementia. <i>Annals of Neurology</i> , 11, 592–598. |
| 1982 | 58M | CVA | Intact | Intact | Impaired | Impaired | | Right | Mazzucchi, A., Marchini, C., Budai, R., Parma, M. 1928. A case of receptive amusia with prominent timbre perception defect. <i>J Neurol Neurosurg Psychiatr</i> . 45(7):644–647. |
| 1982 ** | | | Impaired | Impaired | Intact | ? | | Bilateral | Doyle, PJ. and Holland, AL. Clinical Management of a Patient With Pure Word Deafness. In <i>Clinical Aphasiology Conference: Clinical Aphasiology Conference (1982 : 12th: Oshkosh, WI : June 6-10, 1982): BRK Publishers(1982)</i> , pages 138-146. |
| 1982 | 39F | CVA | Impaired | Impaired | ? | ? | Confusion+ mutism | Bilateral | Kirshner, H. S., Webb, W. G., Duncan, G. W. 1981. Word deafness in Wernicke's aphasia. <i>Journal of Neurology, Neurosurgery & Psychiatry</i> , 44(3), 197-201. |
| 1982 | 36F | CVA | Impaired | Impaired | Impaired | ? | Deafness | Bilateral |  zdamar,  ., Kraus, N., Curry, F. 1982. Auditory brain stem and middle latency responses in a patient with cortical deafness. <i>Electroencephalography and clinical neurophysiology</i> , 53(2), 224-230. |
| 1982 | ? | ? | ? | ? | Impaired | ? | | Bilateral | Vignolo, L. A. 1982. Auditory agnosia. <i>Philosophical Transactions of the Royal Society of London. B, Biological Sciences</i> , 298(1089), 49-57. |

| | | | | | | | | | |
|------------|-----|--------------------|----------|----------|----------|----------|-------------|-----------|--|
| 1982 | ? | ? | ? | ? | Impaired | ? | | Bilateral | Vignolo, L. A. 1982. Auditory agnosia. <i>Philosophical Transactions of the Royal Society of London. B, Biological Sciences</i> , 298(1089), 49-57. |
| 1982 | ? | ? | ? | ? | Impaired | ? | | Bilateral | Vignolo, L. A. 1982. Auditory agnosia. <i>Philosophical Transactions of the Royal Society of London. B, Biological Sciences</i> , 298(1089), 49-57. |
| 1982 | 49F | CVA | Impaired | Impaired | Impaired | Impaired | | Bilateral | Sato, M., Yasui, I., Isobe, I., Koboyashi, T. 1982. A case of pure word deafness and auditory agnosia associated with bilateral temporo-parietal lesions. <i>Brain and Nerve (Tokyo)</i> , 34, pp. 939-945. |
| 1982 | 49M | CVA | Impaired | Impaired | Impaired | Impaired | Wernicke A | Bilateral | Rosati, G., De Bastiani, P., Paolino, E., Prosser, S., Arslan, E., Artioli, M. 1982. Clinical and audiological findings in a case of auditory agnosia. <i>Journal of neurology</i> , 227(1), 21-27. |
| 1982 | 56F | CVA | Impaired | Impaired | Impaired | Impaired | | Bilateral | Miceli, G. 1982. The processing of speech sounds in a patient with cortical auditory disorder. <i>Neuropsychologia</i> , 20(1), 5-20. |
| 1982 | 23M | Bullet penetration | Partial | Partial | Partial | Partial | Wernicke A | Bilateral | von Stockert, T. R. 1982. On the structure of word deafness and mechanisms underlying the fluctuation of disturbances of higher cortical functions. <i>Brain and Language</i> , 16(1), 133-146. |
| 1982 | 58M | CVA | Impaired | Impaired | Impaired | Impaired | | Bilateral | Auerbach, S. H., Allard, T., Naeser, M., Alexander, M. P., Albert, M. L. 1982. Pure word deafness. Analysis of a case with bilateral lesions and a defect at the prephonemic level. <i>Brain: a journal of neurology</i> , 105(Pt 2), 271-300. |
| 1981 ** | | CVA | Impaired | Impaired | Intact | Impaired | | Bilateral | Shindo, M., Kaga, K., & Tanaka, Y. 1981. Auditory agnosia following bilateral temporal lobe lesions-report of a case (author's transl). <i>Nō to shinkei Brain and nerve</i> , 33(2), 139. |
| 1981 ** | | CVA | Deafness | Deafness | Deafness | Deafness | | Bilateral | Ueda S, Tsudat T, Matsumoto K, Obayashi M, Koyama Y. 1981. A moyamoya disease with cortical deafness. In: Proceedings of the 10th Japanese Conference on Surgery of cerebral Stroke. Tokyo, pp. 105-109. |
| 1981 ** | | | Impaired | Impaired | Intact | Intact | | Left | Kamei, H., Nakane, K., Nishimaru, K., Shiraishi, K., Matuo, M. 1981. Pure Word Deafness after cerebrovascular disease: a case report. <i>Clinical Neurology</i> , 21, 402-408. |
| 1981 ** | 70M | CVA | Impaired | ? | ? | Impaired | Deafness | Bilateral | Kneebone, C. S., Burns, R. J. 1980. A case of cortical deafness. <i>Clinical and experimental neurology</i> , 18, 91-97. |
| 1981 | 29M | Multiple Sclerosis | Impaired | Impaired | Intact | Intact | Deafness-AA | Bilateral | Tabira, T., Tsuji, S., Nagashima, T., Nakajima, T., Kuroiwa, Y., 1981. Cortical deafness in multiple sclerosis. <i>J. Neurol. Neurosurg. Psychiatr.</i> 44, 433-436. |

| | | | | | | | | | |
|--------------------------|-----|---------|----------|----------|----------|----------|------------|-----------|--|
| 1980 ** | | | Impaired | Impaired | Impaired | Impaired | | Bilateral | Guard, O., Couailler, J. F., Dumas, R., Romanet, P., Richard, D., Mauguiere, F. 1980. Agnosie auditive. <i>Lyon Medical</i> , 243, 311-317. |
| 1980 | 48F | Seizure | Deafness | Deafness | Deafness | Deafness | Dysphasia | Bilateral | Graham, J., Greenwood, R., Lecky, B. 1980. Cortical deafness: a case report and review of the literature. <i>Journal of the neurological sciences</i> , 48(1), 35-49. |
| 1980 | 62M | CVA | Deafness | Deafness | Deafness | Deafness | | Bilateral | Leicester, J. 1980. Central deafness and subcortical motor aphasia. <i>Brain and language</i> , 10(2), 224-242. |
| 1980 | 51M | CVA | Partial | Partial | Intact | ? | | Left | Hamanaka, T., Asano, K., Morimune, S., & Seko, K. 1980. Ein Fall von reiner Worttaubheit ohne akustische Agnosie. 音声科学研究 = <i>Studia phonologica</i> , 14, 16-24. |
| 1980 ** | ?F | CVA | Impaired | Impaired | Impaired | ? | | Bilateral | Traugott, N. N., Beskadarov, A. V., Vasserman, L. I., Galunov, V. I., Dorofeeva, S. A. 1979. Clinico-experimental study of auditory-speech agnosia (case with anatomic-histologic verification). <i>Zhurnal nevropatologii i psikiatrii imeni SS Korsakova (Moscow, Russia: 1952)</i> , 80(12), 1790-1798. |
| 1980 | 76M | CVA | Impaired | Impaired | Impaired | Impaired | | Bilateral | Parving, A., Salomon, G., Elberling, C., Larsen, B., Lassen, N. A. 1980. Middle components of the auditory evoked response in bilateral temporal lobe lesions: Report on a patient with auditory agnosia. <i>Scandinavian audiology</i> , 9(3), 161-167. |
| 1980 ** | 61M | CVA | Intact | Intact | Intact | Partial | Wernicke A | Left | Mavlov, L. 1980. Amusia due to rhythm agnosia in a musician with left hemisphere damage: a non-auditory supramodal defect. <i>Cortex</i> , 16(2), 331-338. |
| 1980 | 40M | CVA | Impaired | Impaired | Impaired | Impaired | | Bilateral | Michel, F. Peronnet, F., and Schott, B. A case of cortical deafness: Clinical and electrophysiological |
| 1979 | 46M | CVA | Deafness | Deafness | Deafness | Deafness | | Bilateral | Kitahara T, Hatakawa I, Kanda T, Tazaki Y. 1979. A case of subcortical deafness due to cerebral hemorrhage. <i>Japanese Journal of Stroke</i> , Tokyo, 1, 360-364 (in Japanese). |
| 1979 ** | | CVA | Impaired | Impaired | ? | ? | | Bilateral | Haguenaer, J. P., Schott, B., Michel, F., Dubreuil, C., & Romanet, P. 1979, March. Trois observations d'atteinte cortico-sous-corticale de l'audition. Confrontations audiologiques et tomodensimétriques. <i>Ann Otolaryngol. Chir. Cervicofac</i> , 96(3); 185-196. |

| | | | | | | | | | |
|------------|-----|---------|----------|----------|----------|----------|---------------|-----------|--|
| 1979 ** | 55M | CVA | Intact | Intact | Intact | Partial | General AA | Right | Haguenauer, J. P., Schott, B., Michel, F., Dubreuil, C., & Romanet, P. 1979, March. Trois observations d'atteinte cortico-sous-corticale de l'audition. Confrontations audiologiques et tomodynamiques. <i>Ann Otolaryngol. Chir. Cervicofac</i> , 96(3); 185-196. |
| 1979 ** | | | Intact | Intact | Impaired | Intact | | Left | Haguenauer, J. P., Schott, B., Michel, F., Dubreuil, C., & Romanet, P. 1979, March. Trois observations d'atteinte cortico-sous-corticale de l'audition. Confrontations audiologiques et tomodynamiques. <i>Ann Otolaryngol. Chir. Cervicofac</i> , 96(3); 185-196. |
| 1979 ** | 68M | CVA | Deafness | Deafness | Deafness | Deafness | | Bilateral | Barraquer-Bordas, L., Peña-Casanova, J., Pons-Irazábal, L. 1979. Central deafness without aphasic disorders due to bilateral temporal lesion. <i>Acta neurologica latinoamericana</i> , 26(3), 165-174. |
| 1978 ** | | | Impaired | Impaired | | | | Bilateral | Dalla Pria, M., Spinnler, H., Vallar, G. 1978. Pure word deafness and bilateral posterior perisylvian softenings: report of a case with neuropsychological-CAT correlation. <i>Schweizer Archiv für Neurologie, Neurochirurgie und Psychiatrie Archives suisses de neurologie, neurochirurgie et de psychiatrie</i> , 125(1), 47-58. |
| 1978 | 71M | CVA | Impaired | Impaired | Impaired | ? | Non-verbal AA | Bilateral | Oppenheimer, D. R., & Newcombe, F. 1978. Clinical and anatomic findings in a case of auditory agnosia. <i>Archives of Neurology</i> , 35(11), 712-719. |
| 1977 | 49M | CVA | Deafness | Deafness | Deafness | Deafness | | Bilateral | Adams, A. E., Rosenberger, K., Winter, H., Zöllner, C. 1977. A case of cortical deafness. <i>Archiv für Psychiatrie und Nervenkrankheiten</i> , 224(3), 213-220. |
| 1977 ** | | CVA | Impaired | Impaired | Impaired | Impaired | | Bilateral | Ulrich, G.: 1977. Manifestationsbedingungen der akustischen Agnosie und ihre funktionsdynamischen Aspekte. Ein Beitrag zur Frage des interhemisphären Funktionswandels. <i>Nervenarzt</i> 48, 298-304. |
| 1977 | 44M | Seizure | Impaired | Impaired | Intact | Impaired | | Bilateral | Shoumaker, R. D., Ajax, E. T., Schenkenberg, T. 1977. Pure word deafness (auditory verbal agnosia). <i>Diseases of the nervous system</i> . |
| 1977 ** | 50? | CVA? | Deafness | Deafness | Deafness | Deafness | Wernicke A | Bilateral | Zöllner, Ch., Karnahl Th., Pedersen P. 1977. ERA-Befunde bei "kortikaler Schwerhörigkeit", <i>Arch. Oto-Rhino-Lar.</i> , 217: 451461. |
| 1977 | 27M | CVA | Deafness | Deafness | Deafness | Deafness | | Bilateral | Earnest M.P., Monroe P.A., Yarnell P.R. 1977. Cortical deafness: demonstration of the pathologic anatomy by CT scan. <i>Neurology</i> 27: 1172-5. |

| | | | | | | | | | |
|------------|-----|------------------|----------|----------|----------|----------|------------|-------------------|---|
| 1977 ** | | | Deafness | Deafness | Deafness | Deafness | | Bilateral | Koboyashi I, Sugishita M, Tohgi H, Kaga K, Kameyama. 1977. A case of cortical deafness. <i>Clinical Neurology</i> , Tokyo, 17, 361 -367 (in Japanese). |
| 1976 | 47M | CVA | Intact | Intact | Intact | Impaired | General AA | Right | Michel, F., Peronnet, F., Schott, B. 1976. A propos d'un cas de surdit  de l'h miph re gauche (h mianacousie droite). <i>Lyon Medical</i> .(236):691-698. |
| 1976 | 37M | Seizure/ CVA? | Impaired | Impaired | Intact | ? | | Left (S) | Saffran, E.M., Marin, O.S., Yeni-Komshian, G.H., 1976. An analysis of speech perception in word deafness. <i>Brain and Language</i> 3, 209-228. |
| 1975 | 42M | CVA | Impaired | Impaired | Impaired | Impaired | Wernicke A | Bilateral (S) | Chocholle, R., Chedru, F., Botte, M.C., Chain, F., Lhermitte, F., 1975. Etude psychoacoustique d'un cas de 'surdite corticale'. <i>Neuropsychologia</i> 13, 163-172. |
| 1975 | 49M | Seizure | Impaired | Impaired | Impaired | Partial | | Left (S) | Denes, G., Semenza, C., 1975. Auditory modality-specific anomia: evidence from a case of pure word deafness. <i>Cortex</i> 11, 401-411. |
| 1975 | 31F | Encephalitis | Impaired | Impaired | Impaired | Impaired | Confusion | Bilateral | Goldstein, M.N., Brown, M., Hollander, J., 1975. Auditory agnosia and cortical deafness: analysis of a case with three-year followup. <i>Brain and Language</i> 2, 324-332. |
| 1974 ** | | | Intact | Intact | Intact | Impaired | | Right | Roeser, R. J., & Daly, D. D. 1974. Auditory cortex disconnection associated with thalamic tumor A case report. <i>Neurology</i> , 24(6), 555-555. |
| 1974 | 52M | Seizure | Impaired | Impaired | Intact | ? | | Left or Bilateral | Albert, M.L., Bear, D., 1974. Time to understand. A case study of word deafness with reference to the role of time in auditory comprehension. <i>Brain</i> 97, 373-384. |
| 1973 | 13M | Neurosurgery | Impaired | ? | ? | Impaired | | ? | Nagafuchi, M. Suzuki, J. 1973. Auditory agnosia due to incision of splenium corporis callosi. <i>Acta Oto-Laryngologica</i> , 76, 109-113. |
| 1973 ** | | | Impaired | Impaired | Impaired | Impaired | | Bilateral (S) | Assal, G. Despland, P. A. 1973. Presentation d'un cas d'agnosie auditive. <i>Oto-Neuro-Ophtalmologie</i> , 45, 353-355. |
| 1973 ** | | Head trauma | Impaired | | | Intact | | ? | Horenstein, S., & Bealmeair, K. 1973. Concerning the nature of word deafness. <i>Transactions of the American Neurology Association</i> , 98, 264-267. |
| 1973 | 62M | CVA | Impaired | Impaired | Partial | Partial | | Bilateral | Kanshepolsky, J., Kelley, J., Waggener, J., 1973. A cortical auditory disorder. <i>Neurology</i> 23, 699-705. |
| 1973 | 65M | ? | Impaired | Impaired | Partial | ? | | Left (S) | Gazzaniga, M.S., Glass, A.V., Sarno, M.T., Posner, J.B., 1973. Pure word deafness and hemispheric dynamics: a case history. <i>Cortex</i> 9, 136-143. |

| | | | | | | | | | |
|------------|-----|------------------|----------|----------|----------|----------|------------------|---------------|--|
| 1972 ** | | | Impaired | Impaired | ? | ? | Deafness | Bilateral | Jerger, J., Lovering, L., & Wertz, M. 1972. Auditory disorder following bilateral temporal lobe insult: Report of a case. <i>Journal of Speech and Hearing Disorders</i> , 37, 523. |
| 1972 ** | | | Partial | Partial | Impaired | Intact | | Bilateral | Albert, M. L., Sparks, R., von Stockert, T. and Sex, D. 1972. A case study of auditory agnosia: linguistic and non-linguistic processing. <i>Cortex</i> 8, 427~443. |
| 1971 ** | | | Impaired | Impaired | Impaired | Impaired | | Bilateral (S) | Lhermitte F, Chain F, Escourolle R, et al. 1972. Etude des troubles perceptifs auditifs dans les lésions temporales bilatérales. <i>Rev Neurol (Paris)</i> 24:327-351. |
| 1971 ** | | | Impaired | Impaired | Impaired | Impaired | | Bilateral | Lhermitte F, Chain F, Escourolle R, et al. 1972. Etude des troubles perceptifs auditifs dans les lésions temporales bilatérales. <i>Rev Neurol (Paris)</i> 24:327-351. |
| 1971 ** | | | Impaired | Impaired | Impaired | Impaired | | Bilateral | Lhermitte F, Chain F, Escourolle R, et al. 1972. Etude des troubles perceptifs auditifs dans les lésions temporales bilatérales. <i>Rev Neurol (Paris)</i> 24:327-351. |
| 1969 ** | | | Impaired | Impaired | ? | ? | Deafness | Bilateral | Jerger, J., Weikers, N.J., Sharbrough, F.W., and Jerger, S. Bilateral lesions of the temporal lobe. <i>Acta Otolaryngology, Supplement</i> 258: 7-51, 1969. |
| 1965 | 65M | CVA | Intact | Intact | Impaired | ? | | Right | Spreen, O., Benton, A.L., Fincham, R.W., 1965. Auditory agnosia without aphasia. <i>Arch. Neurol.</i> |
| 1964 | 57M | ? | Impaired | Impaired | Impaired | Impaired | | Bilateral (S) | Tanaka, Y., Taguchi, K., Sakabe, N., & Igarashi, E. 1964. Pure auditory agnosia associated with alteration of voice and personal character, <i>Folia phoniatrica</i> , 17, 185-194 |
| 1963 ** | | Tumor | Impaired | Impaired | | | | | Hansen, C.C. and E. Reske-Nielsen. 1963. Cortical hearing loss in a patient with glioblastoma - Neuropathological analysis of a case, <i>Arch. Otolaryng.</i> , 77:461-473. |
| 1963 | 18F | | Impaired | Impaired | Intact | Intact | | ? | Okada, S., Hanada, M., Hattori, H., Shoyama, T., 1963. A Case of Pure Word-Deafness: About the relation between auditory perception and recognition of speech-sound. <i>Studia phonologica</i> 3, 58-65. |
| 1962 | 60F | CVA | Impaired | ? | ? | ? | Deafness +Mutism | Left | Kleist, K. 1962. Sensory aphasia and amusia-The Myeloarchitectonic basis. Pregamon press. pp 1-27. |
| 1962 | 72M | Vascular disease | Deafness | Deafness | ? | ? | | Left | Kleist, K. 1962. Sensory aphasia and amusia-The Myeloarchitectonic basis. Pregamon press. pp 1-27. |
| 1962 | 68 | CVA | Deafness | Deafness | ? | ? | | Bilateral | Kleist, K. 1962. Sensory aphasia and amusia-The Myeloarchitectonic basis. Pregamon press. pp 1-27.. |

| | | | | | | | | | | |
|------------|-----|----------------|----------|----------|----------|----------|---------------------|----------------------|--|--|
| 1962 | 74M | CVA | Deafness | Deafness | ? | ? | | | | Kleist, K. 1962. Sensory aphasia and amusia-The Myeloarchitectonic basis. Pregamon press. pp 1-27.. |
| 1962 | 54M | CVA | Impaired | Intact | ? | ? | | | | Kleist, K. 1962. Sensory aphasia and amusia-The Myeloarchitectonic basis. Pregamon press. pp 60-66.. |
| 1961 ** | 40M | | Intact | Intact | Intact | Impaired | Wernicke A | Left | | Wertheim, N., & Botez, M. I. 1961. Receptive amusia: a clinical analysis. <i>Brain</i> , 84(1), 19-30. |
| 1958 ** | | | Impaired | Impaired | Intact | | Deafness | Bilateral | | Lemoine, J. Mahoudeau, D. 1958. Case of pure auditory agnosia with cortical deafness associated with functional dysphonia; anatomico-clinical observation. In <i>Les Annales d'oto-laryngologie</i> (Vol. 76, No. 4-5, pp. 293-310). |
| 1956 | 45M | CVA | Impaired | Impaired | Intact | ? | Deafness +Mutism | ? | | Klein, R., & Harper, J. 1956. The problem of agnosia in the light of a case of pure word deafness. <i>Journal of Mental Science</i> , 102, 112- 120. |
| 1956 ** | | | Impaired | Impaired | | | | Bilateral (S) | | Krausland-Steinbereithner, F., & Weingarten, K. 1956. Beitrag zur Klinik der reinen Worttaubheit Wiener. <i>Zeitschrift für Nervenheilkunde</i> , 12, 452. |
| 1953 | 50M | CVA | Impaired | Intact | ? | ? | | ? | | Symonds, C., 1953. Aphasia. <i>J. Neurol. Neurosurg. Psychiatr.</i> 16, 1-6. |
| 1953 ** | | | Intact | Intact | | Impaired | | | | Kohl, G. F., Tschabitscher, H. 1953. Über einen Fall von Amusie. <i>Wiener Zeitschrift für Nervenheilkunde und deren Grenzgebiete</i> , 6, pp. 219-230. |
| 1952 | 55M | CVA | Impaired | Impaired | ? | ? | | Bilateral (S) | | Jones, J. Dinolt, R. 1952. Pure word deafness. <i>The Laryngoscope</i> , 62(2), 194-203. |
| 1952 | 45M | ? | Impaired | Impaired | Impaired | Impaired | Deafness | Left or Bilateral | | Ziegler, D.K. 1952. Word deafness and Wernicke's aphasia: Report of cases and discussion of the syndrome. <i>Archives of Neurology and Psychiatry</i> , 67, 323-33 1. |
| 1952 | 50M | CVA | Impaired | Impaired | Impaired | Impaired | | Bilateral | | Wohlfart, G., Lindgren, A., & Jernelius, B. 1952. Clinical picture and morbid anatomy in a case of "pure word deafness." <i>Journal of Mental Disease</i> , 116, 818-827. |
| 1950 | 34F | | Impaired | Impaired | ? | Impaired | Wernicke A +AA | | | Reinhold, D.M. 1950. A case of auditory agnosia. <i>Brain</i> , 73,203-223. |
| 1948 | 58M | Head trauma | Intact | Intact | Impaired | ? | Confusion | Right (S) | | Wortis, B. S., Pfeffer, A. Z. 1948. Unilateral Auditory-Spatial Agnosia. <i>The Journal of nervous and mental disease</i> , 108(3), 181-186. |
| 1945 ** | 52F | | Deafness | Deafness | Deafness | Deafness | Dysphasia | Bilateral (S) | | Chavany, J.A. (1945). Un cas de surdité d'origine corticale. <i>Presse méd.</i> , 53: 472. |

| | | | | | | | | | |
|--------------------------|-----|-------------|----------|----------|----------|----------|-------------------|---------------|--|
| 1944 ** | 50F | | Deafness | Deafness | Deafness | Deafness | | ? | Thiébaud, F., J. Lemoine and E. Wolinetz. (1944). Surdit  verbale avec hypoacousie bilat rale  tudi e par l'audiom tre, Rev. Neurol., 76:93-94. |
| 1940 | 34M | Head trauma | Impaired | Impaired | Impaired | Intact | | ? | Hemphill, R.E & Stengel, E. 1940. A study on pure word-deafness. Journal of Neurology and Psychiatry, 3, 25 1-262. |
| 1938 | 52M | CVA | Intact | Intact | Impaired | ? | Confusion | Bilateral | Nielsen J.M & Sult C.W. 1939. Agnosias and the body scheme. Bull Los Angeles Neurol Soc(4):69. |
| 1938 | 44F | CVA | Deafness | Deafness | Deafness | Deafness | Confusion+ mutism | Bilateral (S) | Le Gros Clark WE, Russell WR. 1938. Cortical deafness without aphasia. Brain; 61: 375-83 |
| 1928 ** | 29M | CVA | Deafness | Deafness | Deafness | Deafness | | Bilateral | Misch, W. 1928. Uber corticale Taubheit, Z. ges. Neurol. Psychiat. 115: 567-573, |
| 1927 | 62F | CVA | Deafness | Deafness | Deafness | Deafness | | Bilateral | Bramwell E: A case of cortical deafness. Brain 50:579-580, 1927 |
| 1926 ** | | | Impaired | Impaired | | | | Left | Hennenberg, R. 1926. Hirnbefund bei reiner worttaubheit. Zenralb. f. Neurol. 43, 251-252. |
| 1926 ** | | | Impaired | Impaired | | | | Left | Schuster,P., & Taterka, H. 1926. Beitrag zur Anatomie und Klinik der reinen Worttaubheit. Zeitschrift fur Neurologie und Psychiatric, 105, 494-538. |
| 1923 ** | 34M | Head trauma | Impaired | Impaired | | Impaired | Deafness | Right | Quensel, F., & Pfeifer, R. A. 1923. Ein Fall von reiner sensorischer Amusie. <i>Journal of Neurology</i> , 77(1), 156-163. |
| 1921 ** | | | Impaired | Impaired | Impaired | Intact | | Right | Laignel-Lavastine M, Alajouanine T. 1921. Un cas d'agnosie auditive. Rev Neurol (Paris) 28: 194-198. |
| 1921 ** | | | Impaired | Impaired | | | | | Kopeczinski, S., Zilberlast-Zand, N. 1921. Un cas de surdit  verbale pure. Rev. Neurol., 29, 1338-1344. |
| 1919 ** | | | Impaired | Impaired | | | | Bilateral | Potzl, O. 1919. Zur klinik und anatomie der reinen worttaubheit. Berlin, Krager. |
| 1918 | 54F | Syphilis | Impaired | Partial | Intact | ? | Confusion | Bilateral | Henschen SE. On the hearing sphere. Acta Otolaryngol. 1918;1(1):423-485. |
| 1907 | 47F | CVA | Impaired | Impaired | Impaired | ? | | Bilateral | Hennenberg, R. 1907. Total aphasia bei erhaltenem leserverstandnis. Berl. Klin. Wschr. 44, 260. Jolly, F. 1902. Demonstration eines Falles von Aphasia mit Worttaubheit. Berl. Klin. Wschr. 39, 269. |
| 1915 ** | | | Impaired | Impaired | | | | Bilateral | Bonhoeffer, P. 1915. Doppelseitige symmetrische Schl fen-und Parietallappenherde als Ursache vollst ndiger dauernder Worttaubheit bei erhaltener Tonskala, verbunden mit taktiler und optischer Agnosie. <i>European Neurology</i> , 37(1), 17-38. |

| | | | | | | | | | |
|------------|-----|-----|----------|----------|----------|----------|---------------------------|-----------|--|
| 1913 ** | | | Intact | Intact | Impaired | | | ? | Kehrer, FA. 1913. Beitrage zur Aphasielehre mit besonderer Beriicksichtigung der amnestischen Aphasie. Archiv für Psychiatric und Nervenkrankheiten, 52, 103. |
| 1912 ** | | | Impaired | Impaired | | | | Bilateral | Stertz, P. 1912. Ueber subkortikale sensorische Aphasie nebst einigen allgemeinen Bemerkungen zur Auffassung aphasischer Symptome. pp. 327–345. <i>European Neurology</i> , 32(4), 327-345. |
| 1912 ** | | | Impaired | Impaired | | | | Bilateral | Blosen, M. 1912. Der Sektionbefund in Serienschritten bei einem Fall von Worttaubheit. Deut. Zeitschr. Nervenheilk., 43; 98, |
| 1910 ** | | | Impaired | Impaired | | | | | Maillard, G., & Hébrard, S. 1910. Un case de surdit  verbale pure. <i>Enc phale</i> , 5(2): 501-503. |
| 1910 | 45M | CVA | Impaired | Impaired | Impaired | Impaired | Confusion | Bilateral | Barrett, A. 1910. A case of pure word-deafness with autopsy. <i>Journal of Nervous and Mental Disease</i> , 37, 73-92. |
| 1907 | 25F | CVA | Deafness | Deafness | Deafness | Deafness | Wernicke A +General AA | Bilateral | Mott F.W. 1907. Bilateral lesions of the auditory cortical centre: Complete deafness and aphasia. <i>Br Med J</i> 2:310-315. |
| 1905 ** | | | Impaired | Impaired | | | | Bilateral | Bonvicini, G. 1905. Uber subcortical sensorische Aphasie. <i>Jahrbucher fur Psychiatrie</i> , 26. 126-229. |
| 1904 ** | | | Deafness | Deafness | Deafness | Deafness | | Bilateral | Marchand, L. 1904. Surditimit  par l sion symetrique des lobes temporaux. <i>Bull Mem Soc Anat</i> , 6, 473-475. |
| 1903 ** | | | Impaired | Impaired | | | | Bilateral | Ballet, G. 1903. Un cas de surdit  verbale par l sions sus-nucl aire (sous corticale) avec atrophie secondaire de l' corce de la premi re temporale. <i>Rev Neurol (Paris)</i> , 9, 111-114. |
| 1902 ** | | | Impaired | Impaired | | | | Left | Liepmann, H., Storch, E. 1902. Der mikroskopische Gehirnbefund bei dem Fall Gorstelle. <i>Monatsschrift fur Psychiatrie and Neurologie</i> , 11, 115-120. |
| 1901 ** | | | Impaired | Impaired | | | | Left | Van Gehuchten, A., & Goris, C. 1901. Un cas de surdit  verbale pure par abcs du lobe temporal gauche; trepanation, guerison. <i>Le Nevruxe</i> , 3, 65-82. |
| 1901 ** | | | Impaired | Impaired | | | | ? | Van Gehuchten, A., & Goris, C. 1901. Un cas de surdit  verbale pure par abcs du lobe temporal gauche; trepanation, guerison. <i>Le Nevruxe</i> , 3, 65-82. |
| 1900 ** | | | Impaired | Impaired | | | | Bilateral | Strohmayer, W. 1900. Zur Kritik der "subcorticalen" sensorischen Aphasie. <i>D.Zeitschr. Nervenheik.</i> , 21:371-385. |

| | | | | | | | | | | |
|-------------------|-----|-----|----------|----------|----------|----------|----------|--|-------------------|---|
| 1900 ** | | | Impaired | Impaired | | | | | | Kast, A. 1900. Zur Kenntnis der Beziehungen zwischen Schweiherigkeit und Worttaubheit. Deutsche Zeitschrift für Nervenheilkunde, 8, 178-197. |
| 1898 ** | | | Impaired | Impaired | | | | | Bilateral | Dejerine, J., & Serieux, P. 1898. Un cas de surdité verbale pure term&e par aphasie sensorielle. Revue de Psychiatric, 2, 7- 11. |
| 1897 | 26F | ? | Impaired | Intact | ? | Impaired | Deafness | | Bilateral (S) | Ellis, A. W. 1984. Introduction to Byrom Bramwell's (1897) case of word meaning deafness. <i>Cognitive Neuropsychology</i> , 1(3), 245-258. |
| 1897 ** | | | Deafness | Deafness | Deafness | Deafness | | | Bilateral | Heilbronner K. 1897. Ober Asymbolie. Psychiatrische Abhandlungen. Breslau, Poland, 1 Fasc, Heit 314. |
| 1896 ** | | | Impaired | Intact | Intact | Intact | | | | Ziehl F. 1896. U" ber einen Fall von Worttaubheit und das Lichtheim'sche Krankheitsbild der subcorticalen sensorischen Aphasie. Deutsche Zeitschrift für Nervenheilkunde, 8: 259e307. |
| 1895 ** | | | Impaired | Impaired | | | | | Left | Freund, C. S. 1895. Labyrinthtaubheit und Sprachtaubheit. Wiesbaden: Bergmann. |
| 1895 ** | | | Intact | Intact | | Impaired | | | | Edgren, J. G. 1895. Amusi (musikalische Aphasie), <i>Deutsche Zeitschrift für Nervenheilkunde</i> 6, 1–64. |
| 1893 | | | Impaired | Impaired | | | | | Left | Shaw, E.A. 1893. The Sensory Side of Aphasia. <i>Brain</i> 16.4: 492-514. Case 6. |
| 1893 | | | Impaired | Impaired | | | | | Left | Shaw, E.A. 1893. The Sensory Side of Aphasia. <i>Brain</i> 16.4: 492-514. Case 7. |
| 1893 | | | Impaired | Impaired | | | | | Left | Shaw, E.A. 1893. The Sensory Side of Aphasia. <i>Brain</i> 16.4: 492-514. Case 8. |
| 1892 ** | 24M | CVA | Deafness | Deafness | Deafness | Deafness | | | Bilateral | Pick, A. 1892. Beitrage zur Lehre von der Storungen der Sprache. Archiv für Psychiatric und Nervenkrankheit, 23, 896-9 18. |
| 1891 | 46F | CVA | Impaired | Impaired | Intact | Intact | ? | | Bilateral | Mills, C.K. 1891. On the localisation of the auditory centre. <i>Brain</i> , 14, 464-472. |
| 1885 ** | | | Impaired | Impaired | Impaired | Impaired | | | Bilateral or Left | Lichtheim L, 1885; On aphasia. <i>Brain</i> , 7 |
| 1882 ** | | | Impaired | Impaired | | | | | Bilateral | Giraudeau D. 1882. Note sur un cas de surdit  cerebrale. Revue de Medicine, 2, pp. 448–452. |
| 1877 ** | | | Impaired | Impaired | | | | | ? | Kussmaul A. 1877. Disturbances of speech. In: von Ziemssen H, ed. Encyclopedia of the Practice of Medicine. New York: William Wood: 581-875. |

11. Appendix C: T1 weighted images

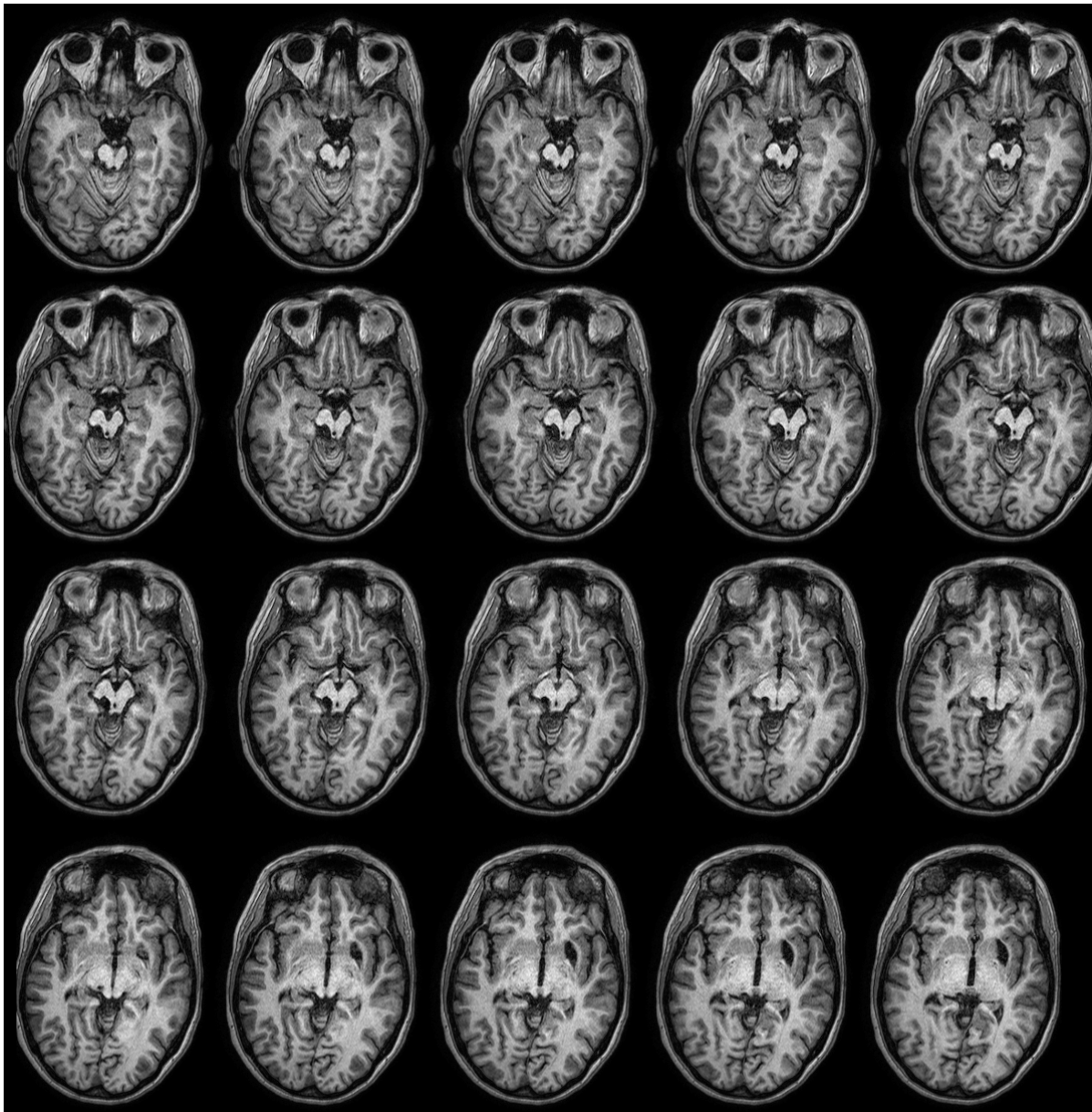


Figure 15. A series of axial MRI T1 sections of LM are shown from lower (upper left) to top (bottom right). The upper two rows display the left IC lesion, and lower row displays the left medial geniculate lesion and the right putamen damage.

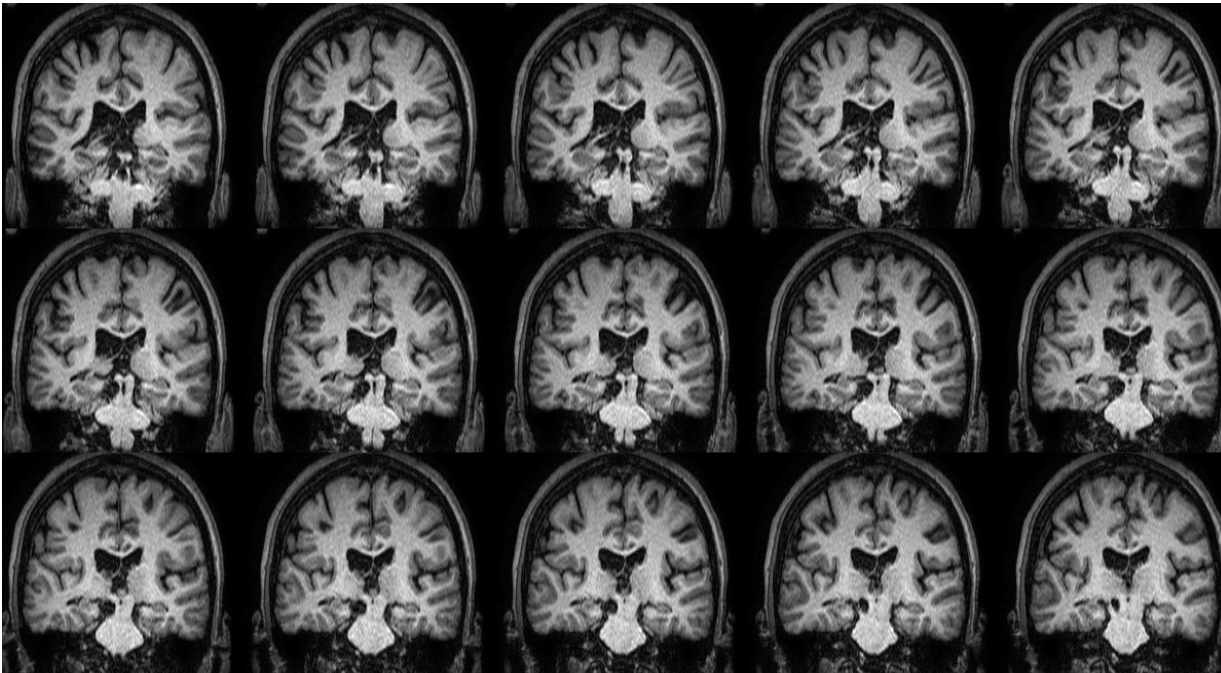

Figure 16. A series of MRI T1 coronal sections of LM are shown from posterior (top left) to anterior (bottom right). These scan display the extent of the IC lesion.

12. References:

- Adams JC. Neuronal morphology of the human cochlear nucleus. *Arch Otol Head Neck Surg* 1986;112:1253–1261.
- Adams, JC. Ascending projections to the inferior colliculus. *J. Comp. Neurol.* 1979;183, 519–538.
- Ahveninen J, Jaaskelainen IP, Raij T, et al. Task-modulated “what” and ‘where’ pathways in human auditory cortex. *Proc Natl Acad Sci USA.* 2006;103(39):14608–14613.
- Alain C, Arnott SR, Hevenor S, Graham S, Grady CL. “What” and ‘where’ in the human auditory system. *Proc Natl Acad Sci USA.* 2001;98(21):12301.
- Albert ML, Sparks R, von Stockert T. Sex D. A case study of auditory agnosia: linguistic and non-linguistic processing. *Cortex* 1972;8, 427~443.
- Albert ML, Bear D. Time to understand. A case study of word deafness with reference to the role of time in auditory comprehension. *Brain.* 1974;97(2):373–384.
- Alho K, Tervaniemi M, Huotilainen M, et al. Processing of complex sounds in the human auditory cortex as revealed by magnetic brain responses. *Psychophysiology.* 2003;33(4):369–375.
- Arias M, Requena I, Ventura M, Pereiro I, Castro A, Alvarez A. A case of deaf–mutism as an expression of pure word deafness: neuroimaging and electrophysiological data. *European Journal of Neurology* 1995;2(6), 583-585.
- Auerbach SH, Allard T, Naeser M, Alexander MP, Albert ML. Pure word deafness. Analysis of a case with bilateral lesions and a defect at the prephonemic level. *Brain.* 1982;105(Pt 2):271–300.
- Ayala YA, Malmierca MS. Stimulus-specific adaptation and deviance detection in the inferior colliculus. *fron-*

tiers in neural circuits. 2012;6:89.

Aharonson V, Furst M, Levine RA, Chaigne M, Korczyn AD. Lateralization and binaural discrimination of patients with pontine lesions. *The Journal of the Acoustical Society of America*, 1998;103(5), 2624-2633.

Anegawa T, Hara K, Yamamoto K, Matsuda M. Unilateral auditory hallucinations due to left temporal lobe ischemia: a case report. *Rinsho shinkeigaku Clinical neurology*, 1995;35(10), 1137-1141.

Axer H, Keyserlingk von AG, Berks G, Keyserlingk von DG. Supra- and Infrasyllvian Conduction Aphasia. *Brain and Language*. 2001;76(3):317–331.

Ayotte J, Peretz I, Rousseau I, Bard C, Bojanowski M. Patterns of music agnosia associated with middle cerebral artery infarcts. *Brain*. 2000;123(9):1926–1938.

Baddeley A, Wilson BA. A case of word deafness with preserved span: Implications for the structure and function of short-term memory. *Cortex*, 29(4), 1993;741-748.

Ballet G. Un cas de surdit  verbale par l sions sus-nucl aire (sous corticale) avec atrophie secondaire de l' corce de la premi re temporale. *Rev Neurol (Paris)*, 1903; 9, 111-114.

Barrett DJK, Hall DA. Response preferences for "what" and 'where' in human non-primary auditory cortex. *NeuroImage*. 2006;32(2):968–977.

Barrett AM. A case of pure word-deafness with autopsy. *J Nerv Ment Dis*. 1910;37:73.

Bastian HC. Some problems in connexion with aphasia and other speech defects. *Lancet* 1897; 1.

Bazana PG, Stelmack RM. Intelligence and information processing during an auditory discrimination task with backward masking: An event-related potential analysis. *Journal of Personality and Social Psychology*. 2002;83(4):998–1008.

- Baum, S. H., Martin, R. C., Hamilton, A. C., & Beauchamp, M. S. (2012). Multisensory speech perception without the left superior temporal sulcus. *NeuroImage*, 62(3), 1825–1832. doi:10.1016/j.neuroimage.2012.05.034
- Baumgart F, Gaschler-Markefski B, Woldorff MG, Heinze HJ, Scheich H. A movement-sensitive area in auditory cortex. *Nature*. 1999;400(6746):724–726.
- Beauchamp MS, Nath AR, Pasalar S. fMRI-Guided Transcranial Magnetic Stimulation Reveals That the Superior Temporal Sulcus Is a Cortical Locus of the McGurk Effect. *Journal of Neuroscience*. 2010; 30(7), 2414–2417. doi:10.1523/JNEUROSCI.4865-09.2010
- Behrens TEJ, Woolrich MW, Jenkinson M, et al. Characterization and propagation of uncertainty in diffusion-weighted MR imaging. *Magn Reson Med*. 2003;50(5):1077–1088.
- Behrens TEJ, Berg HJ, Jbabdi S, Rushworth MFS, Woolrich MW. Probabilistic diffusion tractography with multiple fibre orientations: What can we gain? *NeuroImage*. 2007;34(1):144–155.
- Belin P, Zatorre RJ, Lafaille P, Ahad P, Pike B. Voice-selective areas in human auditory cortex. *Nature*. 2000;403(6767):309–312.
- Belin P, Zatorre RJ. Adaptation to speaker's voice in right anterior temporal lobe. *NeuroReport*. 2003;14(16):2105–2109.
- Bellmann A, Meuli R, Clarke S. Two types of auditory neglect. *Brain*. 2001; 124(Pt 4), 676–687.
- Bendor D, Wang X. Cortical representations of pitch in monkeys and humans. *Current Opinion in Neurobiology*. 2006;16(4):391–399.
- Bendor D, Wang X. Neural Response Properties of Primary, Rostral, and Rostrotemporal Core Fields in the Auditory Cortex of Marmoset Monkeys. *J Neurophysiol*. 2008;100(2):888–906.

- Benson DA, Hienz RD, Goldstein MH. Single-unit activity in the auditory cortex of monkeys actively localizing sound sources: spatial tuning and behavioral dependency. *Brain Res.* 1981;219(2):249–267.
- Benson RR, Whalen DH, Richardson M, et al. Parametrically Dissociating Speech and Nonspeech Perception in the Brain Using fMRI. *Brain and Language.* 2001;78(3):364–396.
- Best W, Howard D. Word sound deafness resolved? *Aphasiology.* 1994;8(3):223–256.
- Bisiach E, Cornacchia L, Sterzi R, Vallar G. Disorders of perceived auditory lateralization after lesions of the right hemisphere. *Brain.* 1984; 107 (Pt 1), 37–52.
- Bieser A, Müller-Preuss P. Auditory responsive cortex in the squirrel monkey: neural responses to amplitude-modulated sounds. *Exp Brain Res.* 1996;108(2):273–284.
- Binder JR, Liebenthal E, Possing ET, Medler DA, Ward BD. Neural correlates of sensory and decision processes in auditory object identification. *Nat Neurosci.* 2004;7(3):295–301.
- Black JA, Fariello RG, Chun, RW. Brainstem auditory evoked response in adrenoleukodystrophy. *Annals of neurology,* 1979;6(3), 269-270.
- Bles M, Jansma BM. Phonological processing of ignored distractor pictures, an fMRI investigation. *BMC Neuroscience.*2008; 9(1), 20. doi:10.1186/1471-2202-9-20
- Boemio A, Fromm S, Braun A, Poeppel D. Hierarchical and asymmetric temporal sensitivity in human auditory cortices. *Nat Neurosci.* 2005;8(3):389–395.
- Boller F, Vignolo LA. Latent sensory aphasia in hemisphere-damaged patients: an experimental study with the Token Test. *Brain.* 1966;89(4):815–830.
- Bonvicini, G. Uber subcorticale sensorische Aphasie. *Jahrbucher fur Psychiatrie* 1995;26. 126-229.
- Bormann T, Weiller C. "Are there lexicons?" A study of lexical and semantic processing in word-meaning deafness suggests "yes". *Cortex.* 2012;48(3):294–307.

- Brechmann A, Baumgart F, Scheich H. Sound-level-dependent representation of frequency modulations in human auditory cortex: a low-noise fMRI study. *J Neurophysiol.* 2002;87(1):423–433.
- Brefczynski-Lewis J, Lowitzsch S, Parsons M, Lemieux S, Puce A. Audiovisual Non-Verbal Dynamic Faces Elicit Converging fMRI and ERP Responses. *Brain Topography.* 2009; 21(3-4), 193–206. doi:10.1007/s10548-009-0093-6
- Brick JF, Frost JA, Schochet SS, Gutman L, Crosby TW. Pure word deafness: CT localization of the pathology. *Neurology.* 1985;35(3):441–442.
- Brodmann, K. Vergleichende Lokalisationslehre der Grosshirnrinde in ihren Prinzipien dargestellt auf Grund des Zellenbaues. 1909; Barth.
- Brunetti M, Belardinelli P, Caulo M, et al. Human brain activation during passive listening to sounds from different locations: An fMRI and MEG study. *Hum Brain Mapp.* 2005;26(4):251–261.
- Brunso-Bechtold, J, Thompson GC, Masterton RB. HRP Study of the organization of auditory afferents ascending to the central nucleus of the inferior colliculus in the cat. *J. Comp. Neurol.* 1981;197, 705–722.
- Buchman AS, Garron DC, Trost-Cardamone JE, Wichter MD, Schwartz M. Word deafness: one hundred years later. *J Neurol Neurosurg Psychiatr.* 1986;49(5):489–499.
- Buchsbaum BR, Hickok G, Humphries C. Role of left posterior superior temporal gyrus in phonological processing for speech perception and production. *Cognitive Science.* 2001;25(5):663–678.
- Buchsbaum BR, Baldo J, Okada K, et al. Conduction aphasia, sensory-motor integration, and phonological short-term memory - An aggregate analysis of lesion and fMRI data. *Brain and Language.* 2011;119(3): 119–128.
- Buchtel HA, Stewart JD. Auditory agnosia: Apperceptive or associative disorder? *Brain and Language.* 1989;37(1):12–25.

- Calford MB. The parcellation of the medial geniculate body of the cat defined by the auditory response properties of single units. *The Journal of neuroscience*, 1983;3(11), 2350-2364.
- Callan DE, Jones JA, Munhall K, Kroos C, Callan AM, Vatikiotis-Bateson E. Multisensory integration sites identified by perception of spatial wavelet filtered visual speech gesture information. *Journal of Cognitive Neuroscience*. 2004; 16(5), 805–816. doi:10.1162/089892904970771
- Calvert GA, Hansen PC, Iversen SD, Brammer MJ. Detection of Audio-Visual Integration Sites in Humans by Application of Electrophysiological Criteria to the BOLD Effect. *NeuroImage*. 2001; 14(2), 427–438. doi: 10.1006/nimg.2001.0812
- Campanella S, Belin P. Integrating face and voice in person perception. *Trends in Cognitive Sciences*. 2007; 11(12), 535–543. doi:10.1016/j.tics.2007.10.001
- Campbell R. The processing of audio-visual speech: empirical and neural bases. *Philosophical Transactions of the Royal Society B: Biological Sciences*. 2008;363(1493):1001–1010.
- Caramazza, A., Berndt, R. S., & Basili, A. G. The selective impairment of phonological processing: a case study. *Brain and Language*. 1983; 18(1), 128–174.
- Carmon A, Nachshon I. Effect of Unilateral Brain Damage on Perception of Temporal Order. *Cortex*. 1971;7(4): 410–418.
- Casseday JH, Neff WD. Auditory localization: Role of auditory pathways in brain stem of the cat. *J. Neurophysiol*. 1975;38, 842–858.
- Catani M, Jones DK, ffytche DH. Perisylvian language networks of the human brain. *Ann Neurol*. 2004;57(1): 8–16.

- Champoux F, Tremblay C, Mercier C, Lassonde M, Lepore F, Gagné J.-P, Théoret H. A role for the inferior colliculus in multisensory speech integration. *NeuroReport*. 2006; 17(15), 1607–1610. doi:10.1097/01.wnr.0000236856.93586.94
- Chesher EC. From affections of the brain (a) organic factors. Acquired word–deafness. *Laryngoscope*. 1937;47(8):520–526.
- Chiba A, Obi T, Takeda K, Sakuta M, Bandou M. A case presenting with amusia after hemorrhage in the right putamen. *Rinshou Shinkeigaku*, 1989;29, 536
- Chiry O, Tardif E, Magistretti PJ, Clarke S. Patterns of calcium-binding proteins support parallel and hierarchical organization of human auditory areas. *European Journal of Neuroscience*. 2003;17(2):397–410.
- Chocholle R, Chedru F, Botte MC, Chain F, Lhermitte F. Etude psychoacoustique d'un cas de 'surdite corticale'. *Neuropsychologia*. 1975;13(2):163–172.
- Chou Y-T, Liao P-W, Lin MC-H, et al. Medulloblastoma Presenting With Pure Word Deafness: Report of One Case and Review of Literature. *Pediatrics and Neonatology*. 2011;52(5):290–293.
- Clarke S, Bellmann A, Meuli RA, Assal G, Steck AJ. Auditory agnosia and auditory spatial deficits following left hemispheric lesions: evidence for distinct processing pathways. *Neuropsychologia*. 2000;38(6):797–807.
- Clarke S, Thiran AB. Auditory Neglect: What and Where in Auditory Space. *Cortex*. 2004; 40(2), 291–300. doi: 10.1016/S0010-9452(08)70124-2
- Confavreux C, Croisile B, Garassus P, Aimard G, Trillet M. Progressive amusia and aprosody. *Archives of Neurology*, 1992;49(9), 971-976.

- Corina DP, Loudermilk BC, Detwiler L, Martin RF, Brinkley JF, Ojemann G. Analysis of naming errors during cortical stimulation mapping: Implications for models of language representation. *Brain and Language*. 2010;115(2):101–112.
- Coslett HB, Brashear HR, Heilman KM. Pure word deafness after bilateral primary auditory cortex infarcts. *Neurology*. 1984;34(3):347–352.
- Creutzfeldt O, Ojemann G, Lettich E. Neuronal activity in the human lateral temporal lobe. I. Responses to speech. *Exp Brain Res*. 1989;77(3):451–475.
- Croisile B, Laurent B, Michel D, Le Bars D, Cinotti L, Mauguiere F. Different clinical types of degenerative aphasia. *Rev Neurol* 1991;147:192e9.
- Cusick CG, Seltzer B, Cola M, Griggs E. Chemoarchitectonics and corticocortical terminations within the superior temporal sulcus of the rhesus monkey: evidence for subdivisions of superior temporal polysensory cortex. *J Comp Neurol*. 1995;360(3):513–535.
- Da Costa S, Van Der Zwaag W, Marques JP, Frackowiak RSJ, Clarke S, Saenz M. Human Primary Auditory Cortex Follows the Shape of Heschl's Gyrus. *Journal of Neuroscience*. 2011;31(40):14067–14075.
- Damian MF, Bowers JS. Assessing the role of orthography in speech perception and production: Evidence from picture–word interference tasks. *European Journal of Cognitive Psychology*. 2009; 21(4), 581–598. doi: 10.1080/09541440801896007
- Damian MF, Martin RC. Semantic and phonological codes interact in single word production. *Journal of Experimental Psychology. Learning, Memory, and Cognition*. 1999; 25(2), 345–361.
- Davis MH, Johnsrude IS. Hierarchical processing in spoken language comprehension. *Journal of Neuroscience*. 2003;23(8):3423–3431.

- Deacon TW. Cortical connections of the inferior arcuate sulcus cortex in the macaque brain. *Brain Res.* 1992;573(1):8–26.
- Dejerine J, Serieux P. Un cas de surdite verbale pure term&e par aphasie sensorielle. *Revue de Psychiatric* 1898; 2, 7- 11.
- De La Sayette V, Dupuy B, Eustache F, Morin I, Viader F, Morin P, Lechevalier B. Multimodal or multisensorial agnosia?. *Revue neurologique*, 1993;150(5), 346-353.
- Delgutte B, Joris PX, Litovsky RY, Yin TC. Receptive fields and binaural interactions for virtual-space stimuli in the cat inferior colliculus. *J. Neurophysiol.* 1999;81, 2833–2851.
- Denes G, Semenza C. Auditory modality-specific anomia: evidence from a case of pure word deafness. *Cortex.* 1975;11(4):401–411.
- De Renzi E, Gentilini M, Pattacini F. Auditory extinction following hemisphere damage. *Neuropsychologia.* 1984;22(6):733–744.
- De Santis L, Clarke S, Murray MM. Automatic and Intrinsic Auditory "What" and "Where" Processing in Humans Revealed by Electrical Neuroimaging. *Cerebral Cortex.* 2006;17(1):9–17.
- Di Salle F, Formisano E, Seifritz E, et al. Functional Fields in Human Auditory Cortex Revealed by Time-Resolved fMRI without Interference of EPI Noise. *NeuroImage.* 2001;13(2):328–338.
- Dodd B. The role of vision in the perception of speech. *Perception.* 1977; 6(1), 31–40.
- Donaldson JO, Hale MS, Klau M. A case of reversible pure-word deafness during lithium toxicity. *Am J Psychiatry.* 1981;138(2):242.
- Dronkers NF, Redfern BB, Knight RT. The Neural Architecture of Language Disorders. In MS Gazzaniga (Ed), *The cognitive neurosciences* Cambridge, MA: MIT Press. 1999:949–958.
- Dronkers NF. The Pursuit of Brain–Language Relationships. *Brain and Language.* 2000;71(1):59–61.

- Dronkers NF, Wilkins DP, Van Valin RD, redfern BB, Jaeger JJ. Lesion analysis of the brain areas involved in language comprehension. *Cognition*. 2004;92(1-2):145–177.
- Duffau H. The anatomo-functional connectivity of language revisited. *Neuropsychologia*. 2008;46(4):927–934.
- Dumahel JR, Poncet M. Deep dysphasia in a case of phonemic deafness: Role of the right hemisphere in auditory language comprehension. *Neuropsychologia*. 1986;24(6):769–779.
- Edwards SB, Ginsburgh CL, Henkel CK, Stein BE. Sources of subcortical projections to the superior colliculus in the cat. *J. Comp. Neurol*. 1979;184, 309–330.
- Efron R. Temporal perception, aphasia and déjà vu. *Brain*. 1963;86(3):403–424.
- Efron R, Crandall PH, Koss B, Divenyi PL, Yund EW. Central auditory processing: III. The “cocktail party” effect and anterior temporal lobectomy. *Brain and Language*. 1983; 19(2), 254–263.
- Ellis AW. Introduction to Byrom Bramwell's (1897) case of word meaning deafness. *Cognitive Neuropsychology*. 1984;1(3):245–258.
- Engelien A, Silbersweig D, Stern E, et al. The functional anatomy of recovery from auditory agnosia. A PET study of sound categorization in a neurological patient and normal controls. *Brain*. 1995;118 (Pt 6):1395–1409.
- Escera C, Corral MJ, Yago E. An electrophysiological and behavioral investigation of involuntary attention towards auditory frequency, duration and intensity changes. *Brain Res Cogn Brain Res*. 2002;14(3):325–332.
- Erber NP. Interaction of audition and vision in the recognition of oral speech stimuli. *Journal of Speech and Hearing Research*. 1969; 12(2), 423–425.
- Eustache F, Lechevalier B, Viader F, Lambert J. Identification and discrimination disorders in auditory perception: a report on two cases. *Neuropsychologia*. 1990;28(3):257–270.

- Franklin S, Howard D, Patterson K. Abstract word meaning deafness. *Cognitive Neuropsychology*. 1994;11(1): 1–34.
- Franklin S, Turner J, Ralph MAL, Morris J, Bailey PJ. A distinctive case of word meaning deafness? *Cognitive Neuropsychology*. 1996;13(8):1139–1162.
- Freud S. *Zur Auffassung der Aphasien*. Vienna: Franz Deuticke. 1891.
- Freund CS. *Labyrinthtaubheit und Sprachtaubheit*. Wiesbaden: Bergmann. 1895.
- Fries W, Swihart A. A. Disturbance of rhythm sense following right hemisphere damage. *Neuropsychologia*, 1990;28(12), 1317-1323.
- Fung VS, Sue CM, Somerville ER. Paroxysmal word deafness secondary to focal epilepsy. *Neurology*. 2000;54(2):533–534.
- Frey S, Campbell JSW, Pike GB, Petrides M. Dissociating the Human Language Pathways with High Angular Resolution Diffusion Fiber Tractography. *Journal of Neuroscience*. 2008;28(45):11435–11444.
- Fujii T, Fukatsu R, Watabe S, et al. Auditory sound agnosia without aphasia following a right temporal lobe lesion. *Cortex*. 1990;26(2):263–268.
- Fullerton BC, Pandya DN. Architectonic analysis of the auditory-related areas of the superior temporal region in human brain. *J Comp Neurol*. 2007;504(5):470–498.
- Furst M, Levine RA, Korczyn AD, Fullerton BC, Tadmor R, Algom D. Brainstem lesions and click lateralization in patients with multiple sclerosis. *Hearing research*, 1995;82(1), 109-124.
- Galaburda A, Sanides F. Cytoarchitectonic organization of the human auditory cortex. *J Comp Neurol*. 1980;190(3):597–610.
- Garde M, Cowey A. “Deaf Hearing”: Unacknowledged Detection of Auditory Stimuli in a Patient with Cerebral Deafness. *Cortex*. 2000;36(1):71–79.

- Gazzaniga MS, Glass AV, Sarno MT, Posner JB. Pure word deafness and hemispheric dynamics: a case history. *Cortex*. 1973;9(1):136–143.
- Geniec P, Morest DK. The neuronal architecture of the human posterior colliculus. A study with the Golgi method. *Acta Otolaryngol Suppl* 1975;295:1–33.
- Geschwind N. Disconnexion syndromes in animals and man. I. *Brain*. 1965;88(2):237–294.
- Giard MH, Lavikahen J, Reinikainen K, et al. Separate representation of stimulus frequency, intensity, and duration in auditory sensory memory: An event-related potential and dipole-model analysis. *Journal of Cognitive Neuroscience*. 1995;7(2):133–143.
- Giraud AL, Price CJ. The constraints functional neuroimaging places on classical models of auditory word processing. *Journal of Cognitive Neuroscience*. 2001;13(6):754–765.
- Giraudeau D. Note sur un cas de surdit  cerebrale. *Revue de Medicine*, 1882; 2, pp. 448–452.
- Godefroy O, Leys D, Furby A, et al. Psychoacoustical deficits related to bilateral subcortical hemorrhages. A case with apperceptive auditory agnosia. *Cortex*. 1995;31(1):149–159.
- Goldstein MN, Brown M, Hollander J. Auditory agnosia and cortical deafness: analysis of a case with three-year followup. *Brain and Language*. 1975;2(3):324–332.
- Gour vitch B, Le Bouquin Jeann s R, Faucon G, Li geois-Chauvel C. Temporal envelope processing in the human auditory cortex: Response and interconnections of auditory cortical areas. *Hear Res*. 2008;237(1-2): 1–18.
- Gow DW Jr. The cortical organization of lexical knowledge: A dual lexicon model of spoken language processing. *Brain and Language*. 2012;121(3):273–288.
- Graves WW, Grabowski TJ, Mehta S, Gupta P. The left posterior superior temporal gyrus participates specifically in accessing lexical phonology. *Journal of Cognitive Neuroscience*. 2008;20(9):1698–1710.

- Greenberg S. A multi-tier framework for understanding spoken language. *Listening to speech: An auditory perspective*. 2006:411–433.
- Griffiths TD, Bates D, Rees A, Witton C, Gholkar A, Green GG. Sound movement detection deficit due to a brainstem lesion. *J Neurol Neurosurg Psychiatr*. 1997a;62(5):522–526.
- Griffiths TD, Rees A, Witton C, Cross PM, Shakir RA, Green GG. Spatial and temporal auditory processing deficits following right hemisphere infarction. A psychophysical study. *Brain*. 1997b;120 (Pt 5):785–794.
- Griffiths TD, Warren JD, Dean JL, Howard D. “When the feeling’s gone”: a selective loss of musical emotion. *J Neurol Neurosurg Psychiatr*. 2004;75(2):344–345.
- Guéguin M, Le Bouquin Jeannès R, Faucon G, Chauvel P, Liégeois-Chauvel C. Evidence of functional connectivity between auditory cortical areas revealed by amplitude modulation sound processing. *Cereb Cortex*. 2007;17(2):304–313.
- Habib M, Daquin G, Milandre L, et al. Mutism and auditory agnosia due to bilateral insular damage--role of the insula in human communication. *Neuropsychologia*. 1995;33(3):327–339.
- Hackett TA, Preuss TM, Kaas JH. Architectonic identification of the core region in auditory cortex of macaques, chimpanzees, and humans. *J Comp Neurol*. 2001;441(3):197–222.
- Haeske-Dewick H, Canavan AG, Hömberg V. Sound localization in egocentric space following hemispheric lesions. *Neuropsychologia*. 1996; 34(9), 937–942.
- Haguenauer JP, Schott B, Michel F, Dubreuil C, Romanet P. March. Three case histories of cortical and sub-cortical auditory lesions. Audiological and tomodynamical confrontations (author's transl). In *Annales d'oto-laryngologie et de chirurgie cervico faciale: bulletin de la Societe d'oto-laryngologie des hopitaux de Paris* 1979;Vol. 96, No. 3, pp. 185-196.

- Halgren E, Baudena P, Clarke JM, et al. Intracerebral potentials to rare target and distractor auditory and visual stimuli. I. Superior temporal plane and parietal lobe. *Electroencephalogr Clin Neurophysiol*. 1995;94(3):191–220.
- Hall DA, Riddoch MJ. Word meaning deafness: Spelling words that are not understood. *Cognitive Neuropsychology*. 1997;14(8):1131–1164.
- Hamanaka T, Asano K, Morimune S, Seko K. Ein Fall von reiner Worttaubheit ohne akustische Agnosie. *Studia phonologica*. 1980;14:16–24.
- Hari R, Rif J, Tiihonen J, Sams M. Neuromagnetic mismatch fields to single and paired tones. *Electroencephalogr Clin Neurophysiol*. 1992;82(2):152–154.
- Harrington IA, Heffner RS, Heffner HE. An investigation of sensory deficits underlying the aphasia-like behavior of macaques with auditory cortex lesions. *NeuroReport*. 2001;12(6):1217–1221.
- Harrington IA, Heffner HE. A Behavioral Investigation of “Separate Processing Streams” Within Macaque Auditory Cortex. Abstracts of the Twenty Fifth Meeting of the Association for Research in Otolaryngology, 25, 120.; 2002:1–1.
- Hart HC, Palmer AR, Hall DA. Different areas of human non-primary auditory cortex are activated by sounds with spatial and nonspatial properties. *Hum Brain Mapp*. 2004;21(3):178–190.
- Hartline PH, Vimal RP, King AJ, Kurylo DD, Northmore DPM. Effects of eye position on auditory localization and neural representation of space in superior colliculus of cats. *Experimental brain research*, 1995;104(3), 402-408.
- Hashimoto R, Homae F, Nakajima K, Miyashita Y, Sakai KL. Functional Differentiation in the Human Auditory and Language Areas Revealed by a Dichotic Listening Task. *NeuroImage*. 2000;12(2):147–158.

- Hattiangadi N, Pillion J, Slomine B, Christensen J, Trovato M, Speedie L. Characteristics of auditory agnosia in a child with severe traumatic brain injury: A case report. *Brain and Language*. 2005;92(1):12–25.
- Häusler R, Levine RA. Auditory dysfunction in stroke. *Acta Otolaryngol*. 2000;120(6):689–703.
- Hayashi K, Hayashi R. Pure word deafness due to left subcortical lesion: neurophysiological studies of two patients. *Clin Neurophysiol*. 2007;118(4):863–868.
- Head H. *Aphasia and Kindred Disorders of Speech*. Cambridge University Press, London. 1926.
- Heilman KM, Valenstein E. Auditory neglect in man. *Arch Neurol*. 1972; 26: 32–5.
- Heffner HE, Heffner RS. Hearing loss in Japanese macaques following bilateral auditory cortex lesions. *J Neurophysiol*. 1986;55(2):256–271.
- Heffner, HE. The role of macaque auditory cortex in sound localization. *Acta Oto-Laryngologica. Supplementum*. 1997; 532, 22–27.
- Heffner, HE. The neurobehavioral study of auditory cortex. *The Auditory Cortex: a Synthesis of Human and Animal Research*. 2005; 111–126.
- Hemphill RE, Stengel E. A study on pure word-deafness. *Journal of Neurology and Psychiatry*, 1940;3, 251–262.
- Hennenberg R. Hirnbefund bei reiner worttaubheit. *Zentralbl. f. Neurol*. 1926;43, 251–252.
- Henschen SE. On the hearing sphere. *Acta Otolaryngol*. 1918;1(1):423–485.
- Henschen SE. *Klinische und pathologische Beiträge zur Pathologie des Gehirns*. Stockholm: Nordiska Bokhandeln. 1920.
- Hickok G, Buchsbaum B, Humphries C, Muftuler T. Auditory-motor interaction revealed by fMRI: speech, music, and working memory in area Spt. *Journal of Cognitive Neuroscience*. 2003;15(5):673–682.

- Hickok G, Poeppel D. The cortical organization of speech processing. *Nat Rev Neurosci*. 2007;8(5):393–402.
- Hickok G, Okada K, Barr W, et al. Bilateral capacity for speech sound processing in auditory comprehension: Evidence from Wada procedures. *Brain and Language*. 2008;107(3):179–184.
- Horenstein S, Bealmeat K. Concerning the nature of word deafness. *Transactions of the American Neurology Association*, 1973;98, 264-267.
- Hugdahl K, Wester K. Auditory neglect and the ear extinction effect in dichotic listening: a reply to Beaton and McCarthy (1993). *Brain and Language*. 1994; 46(1), 166–173. doi:10.1006/brln.1994.1009
- Huffman RF, Henson OW. The descending auditory pathway and acousticomotor systems: connections with the inferior colliculus. *Brain Res Brain Res Rev* 1990;15:295–323.
- Humphries C, Liebenthal E, Binder JR. Tonotopic organization of human auditory cortex. *NeuroImage*. 2010;50(3):1202–1211.
- Hutchison ER, Blumstein SE, Myers EB. An event-related fMRI investigation of voice-onset time discrimination. *NeuroImage*. 2008;40(1):342–352.
- Iizuka O, Suzuki K, Endo K, Fujii T, Mori E. Pure word deafness and pure anarthria in a patient with frontotemporal dementia. *European journal of neurology*, 2007;14(4), 473-475.
- Ilmberger J. Dissociation of visual and auditory order thresholds after cerebral injury in man. *Hum Neurobiol*. 1984;3(4):245–247.
- Isenberg AL, Vaden KI, Jr, Saberi K, Muftuler LT, Hickok G. Functionally distinct regions for spatial processing and sensory motor integration in the planum temporale. *Human Brain Mapping*. 2011; 33(10), 2453–2463. doi:10.1002/hbm.21373

- Jacobs B, Schneider S. Analysis of lexical-semantic processing and extensive neurological, electrophysiological, speech perception, and language evaluation following a unilateral left hemisphere lesion: Pure word deafness? *Aphasiology*. 2003;17(2):123–141.
- Javitt DC, Steinschneider M, Schroeder CE, Vaughan HG, arezzo JC. Detection of stimulus deviance within primate primary auditory cortex: intracortical mechanisms of mismatch negativity (MMN) generation. *Brain Res*. 1994;667(2):192–200.
- Jenkins WM, Masterton RB. Sound localization: effects of unilateral lesions in central auditory system. *J. Neurophysiol*. 1982;47, 987–1016.
- Jerger, J., Weikers, N.J., Sharbrough, F.W., and Jerger, S. Bilateral lesions of the temporal lobe. *Acta Otolaryngology, Supplement* 1972;258: 7-51,
- Jerger, J., Lovering, L., & Wertz, M. Auditory disorder following bilateral temporal lobe insult: Report of a case. *Journal of Speech and Hearing Disorders*, 1972;37, 523.
- Johannes S, Jöbges ME, Dengler R, Münte TF. Cortical auditory disorders: a case of non-verbal disturbances assessed with event-related brain potentials. *Behav Neurol*. 1998;11(1):55–73.
- Joly O, Pallier C, Ramus F, Pressnitzer D, Vanduffel W, Orban GA. Processing of vocalizations in humans and monkeys: A comparative fMRI study. *NeuroImage*. 2012;62(3):1376–1389.
- Jones EG. Chemically defined parallel pathways in the monkey auditory system. *Annals of the New York Academy of Sciences*. 2003;999:218–233.
- Jones J, Dinolt R. Pure word deafness. *Laryngoscope*. 1952;62(2):194–203.
- Kaga K, Nakamura M, Shinogami M, Tsuzuku T, Yamada K, Shindo M. Auditory nerve disease of both ears revealed by auditory brainstem responses, electrocochleography and otoacoustic emissions. *Scandinavian audiology*, 1996;25(4), 233-238.

- Kaga K, Shindo M, Tanaka Y. Central auditory information processing in patients with bilateral auditory cortex lesions. *Acta Otolaryngol Suppl.* 1997;532:77–82.
- Kaga K, Shindo M, Tanaka Y, Haebara H. Neuropathology of auditory agnosia following bilateral temporal lobe lesions: a case study. *Acta Otolaryngol.* 2000;120(2):259–262.
- Kamei H, Nakane K, Nishimaru K, Shiraishi K, Matuo M. Pure Word Deafness after cerebrovascular disease: a case report. *Clinical Neurology*, 1981;21, 402-408.
- Kanshepolksy J, Kelley J, Waggener J. A cortical auditory disorder. *Neurology.* 1973;23:699–705.
- Kaseda Y, Tobimatsu S, Morioka T, Kato M. Auditory middle-latency responses in patients with localized and non-localized lesions of the central nervous system. *J Neurol.* 2012;238(8):427–432.
- Karbe H, Herholz K, Weber-Luxenburger G, Ghaemi M, Heiss WD. Cerebral networks and functional brain asymmetry: evidence from regional metabolic changes during word repetition. *Brain and Language.* 1998;63(1):108–121.
- Karibe H, Yonemori T, Matsuno F, Honmou O, Minamida Y, Uede Tanabe S, Hashi K. A case of tentorial meningioma presented with pure word deafness. *No to shinkei Brain and nerve* 2000;52(11), 997-1001.
- Kazui S, Naritomi H, Sawada T, Inoue N, Okuda JI. Subcortical auditory agnosia. *Brain and Language.* 1990;38(4):476–487.
- Kemp DT, Ryan S, Bray P. A guide to the effective use of otoacoustic emissions. *Ear and hearing* 1990;11(2), 93-105.
- Kim SH, Suh MK, Seo SW, Chin J, Han SH, Na DL. Pure Word Deafness in a Patient with Early-Onset Alzheimer's Disease: An Unusual Presentation. *Journal of Clinical Neurology*, 2011;7(4), 227-230.
- Kirshner HS, Webb WG. Selective involvement of the auditory-verbal modality in an acquired communication disorder: benefit from sign language therapy. *Brain and Language.* 1981;13(1):161–170.

- Kitayama I, Yamazaki K, Shibahara K, Nomura J. Pure word deafness with possible transfer of language dominance. *Psychiatry and Clinical Neurosciences*, 1990;44(3), 577-584.
- Klein R, Harper J. The problem of agnosia in the light of a case of pure word deafness. *Journal of Mental Science* 1956;102, I 12- 120.
- Kleist K. Gehirnpathologische und lokalisatorische Ergebnisse über Hörstörungen, Geräuschaubheiten und Amusien. *European Neurology*, 1928;68(1-6), 853-860.
- Kleist, K. Gehirnpathologie. Leipzig: Barth. 1934.
- Kleist K. Phonemic Deafness (So-Called Pure Word Deafness). in: *Sensory Aphasia and Amusia*. New York: Pergamon Press.; 1962:28–41.
- Kohn SE, Friedman RB. Word-meaning deafness: A phonological-semantic dissociation. *Cognitive Neuropsychology*. 1986;3(3):291–308.
- Korzyukov O, Alho K, Kujala A, et al. Electromagnetic responses of the human auditory cortex generated by sensory-memory based processing of tone-frequency changes. *Neuroscience Letters*. 1999;276(3):169–172.
- Kosmal A, Malinowska M, Kowalska DM. Thalamic and amygdaloid connections of the auditory association cortex of the superior temporal gyrus in rhesus monkey (*Macaca mulatta*). *Acta Neurobiol Exp (Wars)*. 1997;57(3):165–188.
- Koyama S, Shindou J, Maruyama J. A case of pure word deafness after cerebral hemorrhage. *Hokkaido igaku zasshi The Hokkaido journal of medical science*, 2007;82(4), 213-216.
- Kraus N, Ozdamar O, Hier D, Stein L. Auditory middle latency responses (MLRs) in patients with cortical lesions. *Electroencephalogr Clin Neurophysiol*. 1982;54(3):275–287.
- Kraus N, Nicol T. Brainstem origins for cortical ‘what’ and ‘where’ pathways in the auditory system. *Trends Neurosci* 2005;28, 176–181.

- Kreifelts B, Ethofer T, Grodd W, Erb M, Wildgruber D. Audiovisual integration of emotional signals in voice and face: An event-related fMRI study. *NeuroImage*. 2007; 37(4), 1445–1456. doi:10.1016/j.neuroimage.2007.06.020
- Kriegstein von K, Patterson RD, Griffiths TD. Task-Dependent Modulation of Medial Geniculate Body Is Behaviorally Relevant for Speech Recognition. *CURBIO*. 2008;18(23):1855–1859.
- Krumbholz K, Schönwiesner M, Rübsem R, Zilles K, Fink GR, Cramon von DY. Hierarchical processing of sound location and motion in the human brainstem and planum temporale. *European Journal of Neuroscience*. 2005;21(1):230–238.
- Kumar P, Peepal P. Electrocochleography in individuals with Meniere's disease. *Indian J Otol*. 2012;18(2):72.
- Kusmirek P, Rauschecker JP. Functional Specialization of Medial Auditory Belt Cortex in the Alert Rhesus Monkey. *J Neurophysiol*. 2009;102(3):1606–1622.
- Kussmaul A. Disturbances of speech. In: von Ziemssen H, ed. *Encyclopedia of the Practice of Medicine*. New York: William Wood 1877;581-875.
- Lachaux J-P, Jerbi K, Bertrand O, et al. A blueprint for real-time functional mapping via human intracranial recordings. *PLoS ONE*. 2007;2(10):e1094.
- Lackner JR, Teuber HL. Alterations in auditory fusion thresholds after cerebral injury in man. *Neuropsychologia*. 1973;11(4):409–415.
- Lambert J, Eustache F, Lechevalier B, Rossa Y, Viader F. Auditory agnosia with relative sparing of speech perception. *Cortex*. 1989;25(1):71–82.
- la Mothe de LA, Blumell S, Kajikawa Y, Hackett TA. 2006a. Cortical connections of the auditory cortex in marmoset monkeys: Core and medial belt regions. *J Comp Neurol*. 496(1):27–71.
- la Mothe de LA, Blumell S, Kajikawa Y, Hackett TA. 2006b. Thalamic connections of the auditory cortex in

- marmoset monkeys: Core and medial belt regions. *J Comp Neurol.* 496(1):72–96.
- la Mothe de LA, Blumell S, Kajikawa Y, Hackett TA. 2012a. Thalamic connections of auditory cortex in marmoset monkeys: lateral belt and parabelt regions. *Anat Rec (Hoboken).* 295(5):822–836.
- la Mothe de LA, Blumell S, Kajikawa Y, Hackett TA. 2012b. Cortical Connections of Auditory Cortex in Marmoset Monkeys: Lateral Belt and Parabelt Regions. *Anat Rec.* 295(5):800–821.
- Langers DRM, Backes WH, van Dijk P. Representation of lateralization and tonotopy in primary versus secondary human auditory cortex. *NeuroImage.* 2007;34(1):264–273.
- Langers DRM, van Dijk P. Mapping the Tonotopic Organization in Human Auditory Cortex with Minimally Salient Acoustic Stimulation. *Cerebral Cortex.* 2012;22(9):2024–2038.
- Las L, Stern EA, Nelken I. Representation of tone in fluctuating maskers in the ascending auditory system. *The Journal of neuroscience* 2005; 25(6), 1503-1513.
- Leaver AM, Rauschecker JP. Cortical Representation of Natural Complex Sounds: Effects of Acoustic Features and Auditory Object Category. *Journal of Neuroscience.* 2010;30(22):7604–7612.
- Lechevalier B, Rossa Y, Eustache F, Schupp C, Boner L, Bazin C. Un cas de surdit  corticale  pargnant en partie la musique. *Rev Neurol (Paris).* 1984;140(3):190–201.
- Lessard N, Lepore F, Poirier P, Villemagne J, Lassonde M. Sound localization in hemispherectomized subjects: the contribution of crossed and uncrossed cortical afferents. *Experimental Brain Research.* 2000; 134(3), 344–352. doi:10.1007/s002210000463
- Lev nen S, Ahonen A, Hari R, McEvoy L, Sams M. Deviant auditory stimuli activate human left and right auditory cortex differently. *Cereb Cortex.* 1996;6(2):288–296.
- Lewis JW, Van Essen DC. Corticocortical connections of visual, sensorimotor, and multimodal processing areas in the parietal lobe of the macaque monkey. *J Comp Neurol.* 2000;428(1):112–137.

- Lewis JW, Phinney RE, Brefczynski-Lewis JA, DeYoe EA. Lefties get it “right” when hearing tool sounds. *Journal of Cognitive Neuroscience*. 2006;18(8):1314–1330.
- Lhermitte F, Chain F, Escourolle R, Ducarne B, Pillon B, Chedru F. Etude des troubles perceptifs auditifs dans les lésions temporales bilatérales. *Rev Neurol (Paris)* 1972;24:327-351.
- Liasis A, Towell A, Boyd S. Intracranial evidence for differential encoding of frequency and duration discrimination responses. *Ear Hear*. 2000;21(3):252–256.
- Lichtheim L. On aphasia. *Brain*. 1885;(7):433–485.
- Liebenthal E. Neural Substrates of Phonemic Perception. *Cerebral Cortex*. 2005;15(10):1621–1631.
- Liepmann H, Storch, E. Der mikroskopische Gehirnbefund bei dem Fall Gorstelle. *Monatsschrift für Psychiatrie and Neurologie* 1902;11, 115-120.
- Liepmann H. Anatomische Befunde bei Aphasischen und Apraktischen. *Neurologisches Centralblatt* 1912;31, 1524-1 530.
- Liégeois-Chauvel C, Musolino A, Badier JM, Marquis P, Chauvel P. Evoked potentials recorded from the auditory cortex in man: evaluation and topography of the middle latency components. *Electroencephalogr Clin Neurophysiol*. 1994;92(3):204–214.
- Liégeois-Chauvel C, Peretz I, Babai M, Laguitton V, Chauvel P. Contribution of different cortical areas in the temporal lobes to music processing. *Brain*. 1998;121 (Pt 10):1853–1867.
- Litovsky RY, Fligor BJ, Tramo MJ. Functional role of the human inferior colliculus in binaural hearing. *Hearing Research*. 2002; 165(1-2), 177–188.
- MacLeod A, Summerfield Q. Quantifying the contribution of vision to speech perception in noise. *Br J Audiol*. 1987; 21:131–141

- Maeder PP, Meuli RA, Adriani M, et al. Distinct Pathways Involved in Sound Recognition and Localization: A Human fMRI Study. *NeuroImage*. 2001;14(4):802–816.
- Maneta A, Marshall J, Lindsay J. Direct and indirect therapy for word sound deafness. *Int J Lang Commun Disord*. 2001;36(1):91–106.
- Marie, P. What to think about subcortical aphasias (pure aphasias) *Semaine Medicale* 26: 493-500. In M. F. Cole and M. Cole (Eds. and Transl.) *Pierre Marie's Papers on Speech Disorders*. New York: Hafner. 1906; pp 75-102.
- Margolis RH, Rieks D, Fournier EM, Levine SE. Tympanic electrocochleography for diagnosis of Meniere's disease. *Archives of Otolaryngology–Head & Neck Surgery* 1995;121(1), 44-55.
- Marshall RC, Rappaport BZ, Garcia-Bunuel L. Self-monitoring behavior in a case of severe auditory agnosia with aphasia. *Brain and Language*. 1985;24(2):297–313.
- Massaro DW. Preperceptual images, processing time, and perceptual units in auditory perception. *Psychol Rev*. 1972;79(2):124.
- Matsumoto R, Imamura H, Inouchi M, et al. Left anterior temporal cortex actively engages in speech perception: A direct cortical stimulation study. *Neuropsychologia*. 2011;49(5):1350–1354.
- Matzker J. Two new methods for the assessment of central auditory functions in cases of brain disease. *Annals of Otolaryngology, Rhinology and Laryngology*, 68, 1185-1197.
- May PJC, Tiitinen H. Mismatch negativity (MMN), the deviance-elicited auditory deflection, explained. *Psychophysiology*. 2010;47(1):66–122.
- Mazzucchi A, Marchini C, Budai R, Parma M. A case of receptive amusia with prominent timbre perception defect. *J Neurol Neurosurg Psychiatr*. 1982;45(7):644–647.

- McGettigan C, Faulkner A, Altarelli I, Obleser J, Baverstock H, Scott SK. Speech comprehension aided by multiple modalities: Behavioural and neural interactions. *Neuropsychologia*. 2012; 50(5), 762–776. doi: 10.1016/j.neuropsychologia.2012.01.010
- Mc Laughlin MR, Jannetta PJ, Clyde BL, et al. Microvascular decompression of cranial nerves: lessons learned after 4400 operations. *J Neurosurg* 1999;90:1–8.
- Mendez MF, Geehan GR. Cortical auditory disorders: clinical and psychoacoustic features. *J Neurol Neurosurg Psychiatr*. 1988;51(1):1–9.
- Mendez MF. Generalized auditory agnosia with spared music recognition in a left-hander. Analysis of a case with a right temporal stroke. *Cortex*. 2001;37(1):139–150.
- Merchán MA, Berbel P. Anatomy of the ventral nucleus of the lateral lemniscus in rats: a nucleus with a concentric laminar organization. *J Comp Neurol* 1996;372:245–263.
- Merchán MA, Saldana E, Plaza I. Dorsal nucleus of the lateral lemniscus in the rat: concentric organization and tonotopic projection to the inferior colliculus. *J Comp Neurol* 1994;342:259–278.
- Merzenich MM, Brugge JF. Representation of the cochlear partition of the superior temporal plane of the macaque monkey. *Brain Res*. 1973;50(2):275–296.
- Mesulam MM. Slowly progressive aphasia without generalized dementia. *Annals of Neurology*, 11, 592–598.
- sulam, M.M. 1982. Slowly progressive aphasia without generalized dementia. *Annals of Neurology*, 1982;11, 592–598.
- Metz-Lutz MN, Dahl E. Analysis of word comprehension in a case of pure word deafness. *Brain and Language*. 1984;23(1):13–25.
- Miceli G. The processing of speech sounds in a patient with cortical auditory disorder. *Neuropsychologia*. 1982;20(1):5–20.

- Michel F, Peronnet F, Schott B. A propos d'un cas de surdit  de l'h misch re gauche (h mianacousie droite). Lyon Medical. 1976;(236):691–698.
- Michel F, Andreewsky E. Deep dysphasia: An analog of deep dyslexia in the auditory modality. Brain and Language. 1983;18(2):212–223.
- Michel F, Peronnet F, Schott B. A case of cortical deafness: clinical and electrophysiological data. Brain and Language. 1980;10(2):367–377.
- Miller LM, Despoosito M. Perceptual Fusion and Stimulus Coincidence in the Cross-Modal Integration of Speech. Journal of Neuroscience. 2005; 25(25), 5884–5893. doi:10.1523/JNEUROSCI.0896-05.2005
- Miller LM, Recanzone GH. Populations of auditory cortical neurons can accurately encode acoustic space across stimulus intensity. Proc Natl Acad Sci USA. 2009;106(14):5931–5935.
- Mills CK. On the localisation of the auditory centre. Brain 1891;14, 464-472.
- Moore RY, Goldberg JM.. Projections of the inferior colliculus in the monkey. Exp. Neurol. 1966;14, 429–438.
- Moore JK, Osen KK. The cochlear nuclei in man. Am J Anat 1979;154:393–418.
- Morest DK. The laminar structure of the medial geniculate body in the cat. J Anat 1965;99:143–160.
- Morest DK, Oliver DL. The neuronal architecture of the inferior colliculus in the cat: defining the functional anatomy of the auditory midbrain. J Comp Neurol 1984;222:209–236.
- Morosan P, Rademacher J, Schleicher A, Amunts K, Schormann T, Zilles K. Human Primary Auditory Cortex: Cytoarchitectonic Subdivisions and Mapping into a Spatial Reference System. NeuroImage 2001;13(4): 684–701.
- Morel A, Kaas JH. Subdivisions and connections of auditory cortex in owl monkeys. J Comp Neurol. 1992;318(1):27–63.

- Morel A, Garraghty PE, Kaas JH. Tonotopic organization, architectonic fields, and connections of auditory cortex in macaque monkeys. *J Comp Neurol.* 1993;335(3):437–459.
- Moskowitz N, Liu JC. Central projections of the spiral ganglion of the squirrel monkey. *J. Comp. Neurol.* 1972;144, 335–344.
- Motomura N, Yamadori A, Mori E, Tamaru F. Auditory Agnosia. Analysis of a case with bilateral subcortical lesions. *Brain.* 1986;109(3):379–391.
- Munoz M, Mishkin M, Saunders RC. Resection of the Medial Temporal Lobe Disconnects the Rostral Superior Temporal Gyrus from Some of its Projection Targets in the Frontal Lobe and Thalamus. *Cerebral Cortex.* 2009;19(9):2114–2130.
- Murayama J, Kashiwagi T, Kashiwagi A, Mimura M. Impaired pitch production and preserved rhythm production in a right brain-damaged patient with amusia. *Brain and Cognition*, 2004; 56(1), 36-42.
- Näätänen R, Lehtokoski A, Lennes M, et al. Language-specific phoneme representations revealed by electric and magnetic brain responses. *Nature.* 1997;385(6615):432–434.
- Näätänen R, Kujala T, Winkler I. Auditory processing that leads to conscious perception: A unique window to central auditory processing opened by the mismatch negativity and related responses. *Psychophysiology.* 2010;48(1):4–22.
- Nadol JB. Synaptic morphology of inner and outer hair cells of the human organ of Corti. *J. Electron Microsc. Tech.* 1990;15, 187–196.
- Naeser MA, Alexander MP, Helm-Estabrooks N, Levine HL, Laughlin SA, Geschwind N. Aphasia with predominantly subcortical lesion sites. *Arch Neurol.* 1982;39(2):14.
- Nielsen JM, Sult CW. Agnosias and the body scheme. *Bull Los Angeles Neurol Soc.* 1939;(4):69.

- Nishioka H, Takeda Y, Koba T, Yano J, Ohiwa Y, Haraoka J, Ito H. A case of cortical deafness with bilateral putaminal hemorrhage. *No shinkei geka. Neurological surgery*, 1993;21(3), 269-272.
- Noort JV. The structure and connections of the inferior colliculus. An Investigation of the Lower Auditory System. Leiden, Netherlands: Van Gorcum and Company. 1969.
- Noppeney U, Patterson K, Tyler LK, et al. Temporal lobe lesions and semantic impairment: a comparison of herpes simplex virus encephalitis and semantic dementia. *Brain*. 2006;130(4):1138–1147.
- Nakakoshi S, Kashino M, Mizobuchi A, Fukada Y, Katori H. Disorder in sequential speech perception: A case study on pure word deafness. *Brain and language*, 2001;76(2), 119-129.
- Narain C. Defining a Left-lateralized Response Specific to Intelligible Speech Using fMRI. *Cerebral Cortex*. 2003;13(12):1362–1368.
- Neff WD. Localization and lateralization of sound in space. In: *Hearing Mechanisms in Vertebrates*. Edited by A. V. S. DeReuck and J. Knight. London: Churchill.
- Obleser J, Boecker H, Drzezga A, et al. Vowel sound extraction in anterior superior temporal cortex. *Hum Brain Mapp*. 2006a;27(7):562–571.
- Obleser J, Zimmermann J, Van Meter J, Rauschecker JP. Multiple Stages of Auditory Speech Perception Reflected in Event-Related fMRI. *Cerebral Cortex*. 2006b;17(10):2251–2257.
- Okada S, Hanada M, Hattori H, Shoyama T. A Case of Pure Word-Deafness: About the relation between auditory perception and recognition of speech-sound. *Studia phonologica*. 1963;3:58–65.
- Okada K, Hickok G. Two cortical mechanisms support the integration of visual and auditory speech: A hypothesis and preliminary data. *Neuroscience Letters*. 2009; 452(3), 219–223. doi:10.1016/j.neulet.2009.01.060
- Olson IR, Gatenby JC, Gore JC. A comparison of bound and unbound audio-visual information processing in the human cerebral cortex. *Brain Research. Cognitive Brain Research*. 2002; 14(1), 129–138.

- Opitz B, Schröger E, Cramon von DY. Sensory and cognitive mechanisms for preattentive change detection in auditory cortex. *European Journal of Neuroscience*. 2005;21(2):531–535.
- Oppenheimer DR, Newcombe F. Clinical and anatomic findings in a case of auditory agnosia. *Arch Neurol*. 1978;35(11):712–719.
- Otsuki M, Soma Y, Sato M, Homma A, Tsuji S. Slowly progressive pure word deafness. *Eur Neurol*. 1998;39(3):135–140.
- Paavilainen P, Alho K, Reinikainen K, Sams M, Näätänen R. Right hemisphere dominance of different mismatch negativities. *Electroencephalogr Clin Neurophysiol*. 1991;78(6):466–479.
- Paiement P, Champoux F, Bacon BA, Mercier C, Gagné J.-P, Lassonde M, Lepore F. Auditory pathways fail to re-establish normal cortical activation patterns in response to binaural stimulation following a unilateral lesion of the inferior colliculus. *Neurocase*. 2009; 15(2), 89–96. doi:10.1080/13554790802620566
- Palva T, Ojala L. Middle ear conduction deafness and bone conduction. *Acta oto-laryngologica* 1955;45(2), 137-152.
- Pan C-L, Kuo M-F, Hsieh S-T. Auditory agnosia caused by a tectal germinoma. *Neurology*. 2004;63(12):2387–2389.
- Patterson RD, Uppenkamp S, Johnsrude IS, Griffiths TD. The processing of temporal pitch and melody information in auditory cortex. *Neuron*. 2002;36(4):767–776.
- Patterson K, Nestor PJ, Rogers TT. Where do you know what you know? The representation of semantic knowledge in the human brain. *Nat Rev Neurosci*. 2007;8(12):976–987.
- Pavani F, Macaluso E, Warren JD, Driver J, Griffiths TD. A common cortical substrate activated by horizontal and vertical sound movement in the human brain. *CURBIO*. 2002;12(18):1584–1590.

- Peretz I, Kolinsky R, Tramo M, et al. Functional dissociations following bilateral lesions of auditory cortex. *Brain*. 1994;117(6):1283–1301.
- Peretz I, Belleville S, Fontaine S. Dissociations between music and language functions after cerebral resection: A new case of amusia without aphasia. *Canadian journal of experimental psychology Revue canadienne de psychologie experimentale*, 1997;51(4), 354-368.
- Perrodin C, Kayser C, Logothetis NK, Petkov CI. Voice Cells in the Primate Temporal Lobe. *CURBIO*. 2011;21(16):1408–1415.
- Petkov CI, Kayser C, Augath M, Logothetis NK. Functional Imaging Reveals Numerous Fields in the Monkey Auditory Cortex. *Plos Biol*. 2006;4(7):e215.
- Petkov CI, Kayser C, Steudel T, Whittingstall K, Augath M, Logothetis NK. A voice region in the monkey brain. *Nat Neurosci*. 2008;11(3):367–374.
- Pfeifer RR. Classification of response patterns of spike discharges for units in the colchlear nucleus: Tone-burst stimulation. *Experimental brain research* 1966; 1, 220-235.
- Phillips DP, Farmer ME. Acquired word deafness, and the temporal grain of sound representation in the primary auditory cortex. *Behav Brain Res*. 1990;40(2):85–94.
- Piccirilli M, Sciarra T, Luzzi S. Modularity of music: evidence from a case of pure amusia. *J Neurol Neurosurg Psychiatr*. 2000;69(4):541–545.
- Pinard M, Chertkow H, Black S, Peretz I. A case study of pure word deafness: modularity in auditory processing? *Neurocase*. 2002;8(1-2):40–55.
- Poeppl D. Pure word deafness and the bilateral processing of the speech code. *Cognitive Science*. 2001;25(5): 679–693.
- Poeppl D. Pure word deafness and the bilateral processing of the speech code. *Cognitive Science*. 2012a;25(5):

679–693.

Poeppel D, Emmorey K, Hickok G, Pylkkanen L. Towards a New Neurobiology of Language. *Journal of Neuroscience*. 2012b;32(41):14125–14131.

Poliak S. The main afferent fiber systems of the cerebral cortex in primates. 1932.

Polster MR, Rose SB. Disorders of auditory processing: evidence for modularity in audition. *Cortex*. 1998;34(1):47–65.

Poremba A, Malloy M, Saunders RC, Carson RE, Herscovitch P, Mishkin M. Species-specific calls evoke asymmetric activity in the monkey's temporal poles. *Nature*. 2004;427(6973):448–451.

Potzl O. Zur klinik und anatomie der reinen worttaubheit. Berlin, Krager. 1919.

Praamstra P, Meyer AS, Levelt WJM. Neurophysiological Manifestations of Phonological Processing: Latency Variation of a Negative ERP Component Timelocked to Phonological Mismatch. *Journal of Cognitive Neuroscience*. 1994;6:204–219.

Pratt H, Polyakov A, Aharonson V, Korczyn AD, Tadmor R, Fullerton BC, et al. Effects of localized pontine lesions on auditory brain-stem evoked potentials and binaural processing in humans. *Electroencephalography and clinical Neurophysiology* 1998;108:511–20.

Quensel F, Pfeifer RA. Ein Fall von reiner sensorischer Amusie. *Journal of Neurology*, 77(1), 156-163. 1923.

Rabbit RD. A hierarchy of examples illustrating the acoustic coupling of the ear drum. *Journal of the acoustical society of America* 1990; 82, 1243-1252.

Rademacher J, Bürgel U, Zilles K. Stereotaxic Localization, Intersubject Variability, and Interhemispheric Differences of the Human Auditory Thalamocortical System. *NeuroImage*. 2002;17(1):142–160.

Rapin I. Cortical deafness, auditory agnosia, and word-deafness: How distinct are they. *Human Communication Canada*. 1985;9:29–37.

- Rauschecker JP, Scott SK. Maps and streams in the auditory cortex: nonhuman primates illuminate human speech processing. *Nat Neurosci.* 2009;12(6):718–724.
- Rauschecker JP, Tian B, Hauser M. Processing of complex sounds in the macaque nonprimary auditory cortex. *Science.* 1995.
- Rauschecker JP, Tian B, Pons T, Mishkin M. Serial and parallel processing in rhesus monkey auditory cortex. *J Comp Neurol.* 1997;382(1):89–103.
- Recanzone GH, Guard DC, Phan ML, Su TIK. Correlation between the activity of single auditory cortical neurons and sound-localization behavior in the macaque monkey. *J Neurophysiol.* 2000;83(5):2723–2739.
- Repp BH. A range-frequency effect on perception of silence in speech. *Haskins Laboratories Status Report on Speech Research.* 1980:151–165.
- Rhode WS, Greenberg S. Encoding of amplitude modulation in the cochlear nucleus of the cat. *Journal of neurophysiology,* 1994;71(5), 1797-1825.
- Roberts AC, Tomic DL, Parkinson CH, et al. Forebrain connectivity of the prefrontal cortex in the marmoset monkey (*Callithrix jacchus*): An anterograde and retrograde tract-tracing study. *J Comp Neurol.* 2007;502(1):86–112.
- Roeser RJ, Daly DD. Auditory cortex disconnection associated with thalamic tumor A case report. *Neurology,* 1974;24(6), 555-555.
- Romanski LM, Bates JF, Goldman-Rakic PS. Auditory belt and parabelt projections to the prefrontal cortex in the rhesus monkey. *J Comp Neurol.* 1999;403(2):141–157.
- Rosati G, De Bastiani P, Paolino E, Prosser S, Arslan E, Artioli M. Clinical and audiological findings in a case of auditory agnosia. *J Neurol.* 1982;227(1):21–27.

- Rosburg T. Left hemispheric dipole locations of the neuromagnetic mismatch negativity to frequency, intensity and duration deviants. *Brain Res Cogn Brain Res*. 2003;16(1):83–90.
- Ruff RM, Hersh NA, Pribram KH. Auditory spatial deficits in the personal and extrapersonal frames of reference due to cortical lesions. *Neuropsychologia*. 1981; 19(3), 435–443.
- Russ BE, Ackelson AL, Baker AE, Cohen YE. Coding of Auditory-Stimulus Identity in the Auditory Non-Spatial Processing Stream. *J Neurophysiol*. 2007;99(1):87–95.
- Saffran EM, Marin OS, Yeni-Komshian GH. An analysis of speech perception in word deafness. *Brain and Language*. 1976;3(2):209–228.
- Saldana E, Feliciano M, Mugnaini E. Distribution of descending projections from primary auditory neocortex to inferior colliculus mimics the topography of intracollicular projections. *J Comp Neurol* 1996;371:15–40.
- Saldana E, Merchán MA Intrinsic and commissural connections of the rat inferior colliculus. *J Comp Neurol* 1992;319:417–437.
- Sanders DA, Goodrich SJ. The relative contribution of visual and auditory components of speech to speech intelligibility as a function of three conditions of frequency distortion. *Journal of Speech, Language and Hearing Research*. 1971; 14(1), 154.
- Sanchez Longo LP, Forester FM, Auth TL. A clinical test for sound localization and its applications. *Neurology*. 1957; 7(9), 655–663.
- Satoh M, Takeda K, Murakami Y, Onouchi K, Inoue K, Kuzuhara S. A case of amusia caused by the infarction of anterior portion of bilateral temporal lobes. *Cortex*. 2005;41(1):77–83.
- Saur D, Kreher BW, Schnell S, et al. Ventral and dorsal pathways for language. *Proceedings of the National Academy of Sciences*. 2008;105(46):18035–18040.

- Saygin AP. Neural resources for processing language and environmental sounds: Evidence from aphasia. *Brain*. 2003;126(4):928–945.
- Saygin AP, Leech R, Dick F. Nonverbal auditory agnosia with lesion to Wernicke's area. *Neuropsychologia*. 2010;48(1):107–113.
- Scheich H, Baumgart F, Gaschler-Markefski B, et al. Functional magnetic resonance imaging of a human auditory cortex area involved in foreground-background decomposition. *Eur J Neurosci*. 1998;10(2):803–809.
- Scherg M, Vajsar J, Picton TW. A source analysis of the late human auditory evoked potentials. *Journal of Cognitive Neuroscience*. 1989;1(4):336–355.
- Schmahmann JD, Pandya DN, Wang R, et al. Association fibre pathways of the brain: parallel observations from diffusion spectrum imaging and autoradiography. *Brain*. 2007;130(3):630–653.
- Schnider A, Benson DF, Alexander DN, Schnider-Klaus A. Non-verbal environmental sound recognition after unilateral hemispheric stroke. *Brain*. 1994;117 (Pt 2):281–287.
- Schönwiesner M, RübSamen R, Cramon von DY. Hemispheric asymmetry for spectral and temporal processing in the human antero-lateral auditory belt cortex. *European Journal of Neuroscience*. 2005;22(6):1521–1528.
- Schuster P, Taterka H. Beitrag zur Anatomie und Klinik der reinen Worttaubheit. *Zeitschrift für Neurologie und Psychiatric*, 1926;105, 494-538.
- Schwartz MF, Kimberg DY, Walker GM, et al. Anterior temporal involvement in semantic word retrieval: voxel-based lesion-symptom mapping evidence from aphasia. *Brain*. 2009;132(12):3411–3427.
- Schwartz MF, Faseyitan O, Kim J, Coslett HB. The dorsal stream contribution to phonological retrieval in object naming. *Brain*. 2012;135(12):3799–3814.
- Scott SK, Blank CC, Rosen S, Wise RJ. Identification of a pathway for intelligible speech in the left temporal lobe. *Brain*. 2000;123 Pt 12:2400–2406.

- Sekiyama K, Kanno I, Miura S., Sugita Y. Auditory-visual speech perception examined by fMRI and PET. *Neuroscience Research*. 2003; 47(3), 277–287. doi:10.1016/S0168-0102(03)00214-1
- Seliger GM, Lefever F, Lukas R, Chen J, Schwartz S, Codeghini L, Abrams G. Word deafness in head injury: implications for coma assessment and rehabilitation. *Brain Injury* 1991;5, 53–56.
- Seltzer B, Pandya DN. Further observations on parieto-temporal connections in the rhesus monkey. *Exp Brain Res*. 1984;55(2):301–312.
- Shehata-Dieler W, Shimizu H, Soliman SM, Tusa RJ. Middle latency auditory evoked potentials in temporal lobe disorders. *Ear Hear*. 1991;12(6):377–388.
- Sherman SM. Thalamocortical interactions. *Current Opinion in Neurobiology*. 2012;22(4):575–579.
- Shindo M, Kaga K, Tanaka Y. Auditory agnosia following bilateral temporal lobe lesions-report of a case (author's transl). *Nō to shinkei Brain and nerve*, 1981;33(2), 139.
- Shindo M, Kaga K, Tanaka Y. Speech discrimination and lip reading in patients with word deafness or auditory agnosia. *Brain and Language*. 1991;40(2):153–161.
- Shivashankar N, Shashikala HR, Nagaraja D, Jayakumar PN, Ratnavalli E. Pure word deafness in two patients with subcortical lesions. *Clin Neurol Neurosurg*. 2001;103(4):201–205.
- Shoumaker RD, Ajax ET, Schenkenberg T. Pure word deafness (auditory verbal agnosia). *Diseases of the nervous system*. 1977.
- Spoendlin H, Schrott A. Analysis of the human auditory nerve. *Hear. Res*. 1989;143, 25-38.
- Spreen O, Benton AL, Fincham RW. Auditory agnosia without aphasia. *Arch Neurol*. 1965.

- Steinschneider M. Intracortical Responses in Human and Monkey Primary Auditory Cortex Support a Temporal Processing Mechanism for Encoding of the Voice Onset Time Phonetic Parameter. *Cerebral Cortex*. 2004;15(2):170–186.
- Stefanatos GA, Gershkoff A, Madigan S. On pure word deafness, temporal processing, and the left hemisphere. 2005:1–15.
- Stefanatos GA, Braitman LE, Madigan S. Fine grain temporal analysis in aphasia: Evidence from auditory gap detection. *Neuropsychologia*. 2007;45(5):1127–1133.
- Steinke WR, Cuddy LL, Jakobson LS. Dissociations among functional subsystem governing melody recognition after right-hemisphere damage. *Cogn Neuropsychol* 2001;18: 411–437.
- Stevenson RA, James TW. Audiovisual integration in human superior temporal sulcus: Inverse effectiveness and the neural processing of speech and object recognition. *NeuroImage*. 2009; 44(3), 1210–1223. doi: 10.1016/j.neuroimage.2008.09.034
- Stinson MR, Khanna SM. 1989. Sound propagation in the ear canal and coupling to the ear drum with measurements on model systems. *Journal of the acoustical society of America*, 85, 2481-2491.
- Striem-Amit E, Hertz U, Amedi A. Extensive Cochleotopic Mapping of Human Auditory Cortical Fields Obtained with Phase-Encoding fMRI. Op de Beeck H, ed. *PLoS ONE*. 2011;6(3):e17832.
- Strominger NL, Nelson LR, Dougherty WJ. Second order auditory pathways in the chimpanzee. *J. Comp. Neurol*. 1977;15, 349–365.
- Studdert-Kennedy M. Hemispheric Specialization for Speech Perception. *J Acoust Soc Am*. 1970;48(2B):579.
- Sumbly WH, Pollack I. Visual contribution to speech intelligibility in noise. *The Journal of the Acoustical Society of America*. 1954; 26(2), 212–215.

- Sweet RA, Dorph-Petersen K-A, Lewis DA. Mapping auditory core, lateral belt, and parabelt cortices in the human superior temporal gyrus. *J Comp Neurol*. 2005;491(3):270–289.
- Symonds C. Aphasia. *J Neurol Neurosurg Psychiatr*. 1953;16(1):1–6.
- Sysoeva O, Takegata R, Näätänen R. Pre-attentive representation of sound duration in the human brain. *Psychophysiology*. 2006;43(3):272–276.
- Szirmai I, Farsang M, Csüri M. Cortical auditory disorder caused by bilateral strategic cerebral bleedings. Analysis of two cases. *Brain and Language*. 2003;85(2):159–165.
- Tabira T, Tsuji S, Nagashima T, Nakajima T, Kuroiwa Y. Cortical deafness in multiple sclerosis. *J Neurol Neurosurg Psychiatr*. 1981;44(5):433–436.
- Takahashi N, Kawamura M, Shinotou H, Hirayama K, Kaga K, Shindo M. Pure word deafness due to left hemisphere damage. *Cortex*. 1992;28(2):295–303.
- Tanaka Y, Taguchi K, Sakabe N, Igarashi E. Pure auditory agnosia associated with alteration of voice and personal character. A case report. *Folia Phoniatri (Basel)*. 1965;17:185–194.
- Tanaka Y, Yamadori A, Mori E. Pure word deafness following bilateral lesions. A psychophysical analysis. *Brain*. 1987;110(2):381–403.
- Tanaka Y, Kamo T, Yoshida M, Yamadori A. “So-called” cortical deafness. Clinical, neurophysiological and radiological observations. *Brain*. 1991;114(6):2385–2401.
- Tanaka Y, Nakano I, Obayashi T. Environmental sound recognition after unilateral subcortical lesions. *Cortex*. 2002;38(1):69–76.
- Taniwaki T, Tagawa K, Sato F, Iino K. Auditory agnosia restricted to environmental sounds following cortical deafness and generalized auditory agnosia. *Clin Neurol Neurosurg*. 2000;102(3):156–162.

- Tata MS, Ward LM. Early phase of spatial mismatch negativity is localized to a posterior “where” auditory pathway. *Exp Brain Res*. 2005;167(3):481–486.
- Tata MS, Ward LM. Spatial attention modulates activity in a posterior “where” auditory pathway. *Neuropsychologia*. 2005;43(4):509–516.
- Terao Y, Mizuno T, Shindoh M, et al. Vocal amusia in a professional tango singer due to a right superior temporal cortex infarction. *Neuropsychologia*. 2006;44(3):479–488.
- Terr LI, Edgerton BJ. Three-dimensional reconstruction of the cochlear nuclear complex in humans. *Arch Otolaryngol* 1985;111:495–501.
- Tessier C, Weill-Chounlamounry A, Michelot N, Pradat-Diehl P. Rehabilitation of word deafness due to auditory analysis disorder. *Brain Inj*. 2007;21(11):1165–1174.
- Thiran AB, Clarke S. Preserved use of spatial cues for sound segregation in a case of spatial deafness. *Neuropsychologia*. 2003; 41(9), 1254–1261. doi:10.1016/S0028-3932(03)00014-9
- Thompson GC, Cortez AM. The inability of squirrel monkeys to localize sound after unilateral ablation of auditory cortex. *Behavioural Brain Research*. 1983; 8(2), 211–216.
- Tiitinen H, Alho K, Huotilainen M, Ilmoniemi RJ, Simola J, Näätänen R. Tonotopic auditory cortex and the magnetoencephalographic (MEG) equivalent of the mismatch negativity. *Psychophysiology*. 1993;30(5): 537–540.
- Towle VL, Yoon HA, Castelle M, et al. ECoG gamma activity during a language task: differentiating expressive and receptive speech areas. *Brain*. 2008;131(8):2013–2027.
- Tramo MJ, Bharucha JJ, Musiek FE. Music perception and cognition following bilateral lesions of auditory cortex. *Journal of Cognitive Neuroscience*. 1990;2(3):195–212.

- Turken AU, Dronkers NF. The Neural Architecture of the Language Comprehension Network: Converging Evidence from Lesion and Connectivity Analyses. *Front Syst Neurosci.* 2011;5:1–20.
- Ulrich G. Interhemispheric functional relationships in auditory agnosia. An analysis of the preconditions and a conceptual model. *Brain and Language.* 1978;5(3):286–300.
- Uusvuori J, Parviainen T, Inkinen M, Salmelin R. Spatiotemporal Interaction between Sound Form and Meaning during Spoken Word Perception. *Cerebral Cortex.* 2007; 18(2), 456–466. doi:10.1093/cercor/bhm076
- van Atteveldt NM, Formisano E, Goebel R, Blomert L. Top–down task effects overrule automatic multisensory responses to letter–sound pairs in auditory association cortex. *NeuroImage.* 2007; 36(4), 1345–1360. doi: 10.1016/j.neuroimage.2007.03.065
- Weidner WE, Jinks AFG. The effects of single versus combined cue presentations on picture naming by aphasic adults. *Journal of Communication Disorders.* 1983; 16: 111–121.
- Van Gehuchten A, Goris C. Un cas de surditte verbale pure par abcs du lobe temporal gauche; trepanation, guerison. *Le Nevruxe,* 1901;3, 65-82.
- Viemeister NF, Wakefield GH. Temporal integration and multiple looks. *J. Acoust. Soc. Am.* 1991; 90, 858–865.
- Viceic D, fornari E, Thiran J-P, et al. Human auditory belt areas specialized in sound recognition: a functional magnetic resonance imaging study. *NeuroReport.* 2006;17(16):1659–1662.
- Vignolo L. auditory agnosia: a review and report of recent evidence. In: Benton(Ed.), *Contributions to Clinical Neuropsychology,* aldine, Chicago. 1969.
- Vignolo LA. Auditory agnosia. *Philos Trans R Soc Lond, B, Biol Sci.* 1982;298(1089):49–57.
- Vignolo LA. Music agnosia and auditory agnosia. Dissociations in stroke patients. *Annals of the New York Academy of Sciences.* 2003;999:50–57.

- von Economo CF, Koskinas GN. Die cytoarchitektonik der hirnrinde des erwachsenen menschen. J. Springer. 1925.
- Stockert von TR. On the structure of word deafness and mechanisms underlying the fluctuation of disturbances of higher cortical functions. *Brain and Language*. 1982;16(1):133–146.
- Wallace AB, Blumstein SE. Temporal integration in vowel perception. *J Acoust Soc Am*. 2008;125(3):1704–1711.
- Wallace MN, Johnston PW, Palmer AR. Histochemical identification of cortical areas in the auditory region of the human brain. *Exp Brain Res*. 2002;143(4):499–508.
- Wang E, Peach RK, Xu Y, Schneck M, Manry C. Perception of Dynamic Acoustic Patterns by an Individual with Unilateral Verbal Auditory Agnosia. *Brain and Language*. 2000;73(3):442–455.
- Warr WB. Fiber degeneration following lesions in the anterior ventral cochlear nucleus of the cat. *Exp Neurol* 1966;14, 453–474.
- Warren JD, Zielinski BA, Green GGR, Rauschecker JP, Griffiths TD. Perception of sound-source motion by the human brain. *Neuron*. 2002;34(1):139–148.
- Warren JD, Griffiths TD. Distinct mechanisms for processing spatial sequences and pitch sequences in the human auditory brain. *Journal of Neuroscience*. 2003;23(13):5799–5804.
- Warren JD, Jennings AR, Griffiths TD. Analysis of the spectral envelope of sounds by the human brain. *NeuroImage*. 2005;24(4):1052–1057.
- Weeks RA, Aziz-Sultan A, Bushara KO, Tian B, Wessinger CM, Dang N et al. A PET study of human auditory spatial processing. *Neuroscience Letters*. 1999; 262(3), 155–158.
- Weisenburg T, McBride KE. *Aphasia*. 1935.

- Werner S, Noppeney U. Superadditive Responses in Superior Temporal Sulcus Predict Audiovisual Benefits in Object Categorization. *Cerebral Cortex*. 2010; 20(8), 1829–1842. doi:10.1093/cercor/bhp248
- Wernicke C, Tesak J. *Der Aphasische Symptomenkomplex*. 1874.
- Wernicke, C. Friedlander; Ein Fall von Taubheit in folge von doppelseiteger Laesion des Schläfenlappens. *Fortschr. Med.*, 1883;1, pp. 177–185.
- Wertheim N, Botez MI. Receptive amusia: a clinical analysis. *Brain*, 1961;84(1), 19-30.
- Wiegand L, Winter I.M. 2001. Temporal representation of iterated rippled noise as a function of delay and sound level in the ventral cochlear nucleus. *J Neurophysiol* 85, 1206-1219.
- Williams AJ, Fuzessery ZM. Facilitatory mechanisms shape selectivity for the rate and direction of FM sweeps in the inferior colliculus of the pallid bat. *J Neurophysiol* 2010;104, 1456–1471.
- Wilson SJ, Pressing JL, Wales RJ. Modelling rhythmic function in a musician post-stroke. *Neuropsychologia*. 2002;40(8):1494–1505.
- Winer JA. The human medial geniculate body. *Hear Res* 15: 225–247. 1984.
- Wirkowski E, Echausse N, Overby C, Ortiz O, Radler L, I can hear you yet cannot comprehend: A case of pure word deafness. *The Journal of Emergency Medicine* 2006;30, 53–55.
- Wise RJ, Scott SK, Blank SC, Mummery CJ, Murphy K, Warburton EA. Separate neural subsystems within 'Wernicke's area'. *Brain*. 2001;124(Pt 1):83–95.
- Wolberg SC, Temlett JA, Fritz VU. Pure word deafness. *S Afr Med J*. 1990;78(11):668–670.
- Wolmetz M, Poeppel D, Rapp B. What Does the Right Hemisphere Know about Phoneme Categories? *Journal of Cognitive Neuroscience*. 2011;23(3):552–569.

- Woods DL, Knight RT, Neville HJ. Bitemporal lesions dissociate auditory evoked potentials and perception. *Electroencephalogr Clin Neurophysiol.* 1984;57(3):208–220.
- Woods TM, Lopez SE, Long JH, Rahman JE, Recanzone GH. 2006. Effects of Stimulus Azimuth and Intensity on the Single-Neuron Activity in the Auditory Cortex of the Alert Macaque Monkey. *J Neurophysiol.* 96(6): 3323–3337.
- Woods DL, Herron TJ, Cate AD, et al. Functional Properties of Human Auditory Cortical Fields. *Front Syst Neurosci.* 2010;4.
- Wortis SB, Pfeffer AZ. Unilateral auditory-spatial agnosia. *J Nerv Ment Dis.* 1948;108(3):181–186.
- Wright TM, Pelphrey KA, Allison T, McKeown MJ, McCarthy G. Polysensory interactions along lateral temporal regions evoked by audiovisual speech. *Cerebral Cortex (New York, N.Y. : 1991).* 2003; 13(10), 1034–1043.
- Yabe H, Winkler I, Czigler I, et al. Organizing sound sequences in the human brain: the interplay of auditory streaming and temporal integration. *Brain Res.* 2001;897(1):222–227.
- Yamamoto T, Kikuchi T, Nagae J, Ogata K, Ogawa M, Kawai M. Dysprosody associated with environmental auditory sound agnosia in right temporal lobe hypoperfusion--a case report. *Rinsho shinkeigaku Clinical neurology,* 2004;44(1), 28-33.
- Yaqub BA, Gascon GG, Al-Nosha M, Whitaker H. Pure word deafness (acquired verbal auditory agnosia) in an Arabic speaking patient. *Brain.* 1988;111 (Pt 2):457–466.
- Yin TC, Chan JC. Interaural time sensitivity in medial superior olive of cat. *J Neurophysiol* 1990;64, 465–488.
- Yin P, Mishkin M, Sutter M, Fritz JB. Early Stages of Melody Processing: Stimulus-Sequence and Task-Dependent Neuronal Activity in Monkey Auditory Cortical Fields A1 and R. *J Neurophysiol.* 2008;100(6):3009–3029.

- Zaidel E. Auditory vocabulary of the right hemisphere following brain bisection or hemidecortication. *Cortex*. 1976;12(3):191–211.
- Zatorre RJ, Ptito A, Villemure JG. Preserved auditory spatial localization following cerebral hemispherectomy. *Brain*. 1995; 118 (Pt 4), 879–889.
- Zatorre RJ, Bouffard M, Belin P. Sensitivity to Auditory Object Features in Human Temporal Neocortex. *Journal of Neuroscience*. 2004; 24(14), 3637–3642. doi:10.1523/JNEUROSCI.5458-03.2004
- Ziehl F. Ueber einen Fall von Worttaubheit und das Lichtheim'sche Krankheitsbild der subcorticalen sensorischen Aphasie. *Deutsche Zeitschrift für Nervenheilkunde*, 1896;8: 259e307.
- Zhu R-J, Lv Z-S, Shan C-L, Xu M-W, Luo B-Y. Pure word deafness associated with extrapontine myelinolysis. *J Zhejiang Univ Sci B*. 2010;11(11):842–847.
- de Zubicaray, G. I., Wilson, S. J., McMahon, K. L., & Muthiah, S. (2001). The semantic interference effect in the picture–word paradigm: An event–related fMRI study employing overt responses. *Human Brain Mapping*, 14(4), 218–227.
- Zubicaray, G. I., & McMahon, K. L. (2009). Auditory context effects in picture naming investigated with event-related fMRI. *Cognitive, Affective, & Behavioral Neuroscience*, 9(3), 260–269. doi:10.3758/CABN.9.3.260