Medically important snakes and snakebite envenoming in Iran

Dehghani, Rouhullah; Monzavi, Seyed Mostafa; Mehrpour, Omid; Shirazi, Farshad M.; Hassanian-Moghaddam, Hossein; Keyler, Daniel E.; Wüster, Wolfgang; Westerström, Alexander; Warrell, David A.

Toxicon

DOI:
https://doi.org/10.1016/j.toxicon.2023.107149

Published: 23/05/2023

Peer reviewed version

Journal Pre-proof



Medically important snakes and snakebite envenoming in Iran

Ruhollah Dehghani, Seyed Mostafa Monzavi, Omid Mehrpour, Farshad M. Shirazi, Hossein Hassanian-Moghaddam, Daniel E. Keyler, Wolfgang Wüster, Alexander Westerström, David A. Warrell

PII: S0041-0101(23)00135-6

DOI: https://doi.org/10.1016/j.toxicon.2023.107149

Reference: TOXCON 107149

To appear in: *Toxicon*

Received Date: 28 March 2023

Revised Date: 1 May 2023

Accepted Date: 2 May 2023

Please cite this article as: Dehghani, R., Monzavi, S.M., Mehrpour, O., Shirazi, F.M., Hassanian-Moghaddam, H., Keyler, D.E., Wüster, W., Westerström, A., Warrell, D.A., Medically important snakes and snakebite envenoming in Iran, *Toxicon* (2023), doi: https://doi.org/10.1016/j.toxicon.2023.107149.

Author contributions:
Conceptualization (R.D., O.M., D.A.W.); Methodology (S.M.M., O.M.); Investigation (S.M.M., R.D., H.H.M., W.W., A.W., F.M.S.); Validation (S.M.M., D.A.W., D.E.K., W.W., A.W.); Visualization (S.M.M., R.D.); Data curation (S.M.M., O.M.); Formal analysis (S.M.M., D.A.W., O.M.); Writing - original draft (All authors); Writing - review & editing (All authors); Supervision (D.A.W., O.M.)

A Critical Review on: Medically Important Snakes and Snakebite Envenoming in Iran

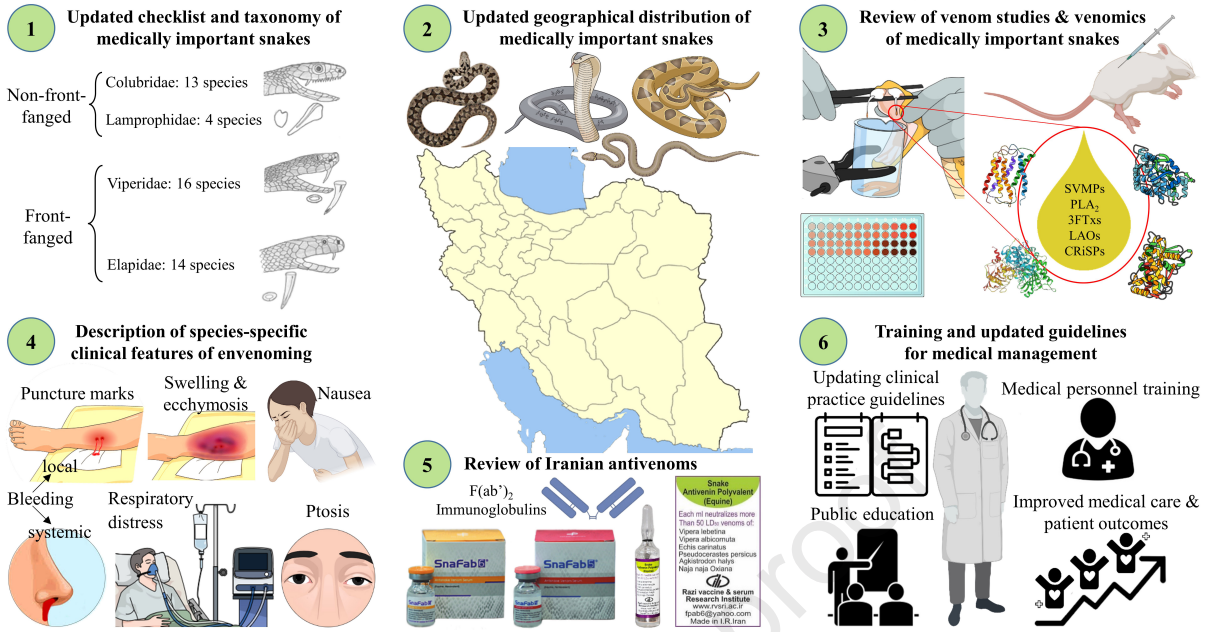

Medically important snakes and snakebite envenoming in Iran

Ruhollah Dehghani[1,2*], Seyed Mostafa Monzavi[3,4*], Omid Mehrpour[5,6✉], Farshad M. Shirazi[7], Hossein Hassanian-Moghaddam[4,8], Daniel E. Keyler[9], Wolfgang Wüster[10], Alexander Westerström[11], David A. Warrell[12]

[1] Department of Environmental Health, Kashan University of Medical Sciences, Kashan, Iran

[2] Social Determinants of Health Research Center, Kashan University of Medical Sciences, Kashan, Iran

[3] Medical Toxicology Center, Mashhad University of Medical Sciences, Mashhad, Iran

[4] Social Determinants of Health Research Center, Shahid Beheshti University of Medical Sciences, Tehran Iran

[5] Medical Toxicology and Drug Abuse Research Center, Birjand University of Medical Sciences, Birjand, Iran

[6] Rocky Mountain Poison and Drug Center, Denver Health and Hospital Authority, Denver, CO, USA.

[7] Arizona Poison and Drug Information Center, University of Arizona, Tucson, AZ, USA.

[8] Department of Clinical Toxicology, Loghman Hakim Hospital, Shahid Beheshti University of Medical Sciences, Tehran, Iran

[9] Department of Experimental & Clinical Pharmacology, University of Minnesota, Minneapolis, MN, USA

[10] Molecular Ecology and Evolution at Bangor, School of Natural Sciences, Bangor University, Bangor, UK

[11] National Museum of Natural History, Sofia, Bulgaria

[12] Nuffield Department of Clinical Medicine, University of Oxford, Oxford, UK

* These authors contributed equally to this work.

✉ **Correspondence to:** Omid Mehrpour; MD. Medical Toxicology and Drug Abuse Research Center, Birjand University of Medical Sciences, Birjand, Iran, AND Rocky Mountain Poison and Drug Center, Denver Health and Hospital Authority, Denver, CO, USA.

E-mail: omid.mehrpour@yahoo.com.au, omid.mehrpour@cuanschutz.edu

Manuscript type: Review Article (Systematic Review)

Running title: Medically Important Snakes of Iran

ABSTRACT

Snakebite is a common health condition in Iran with a diverse snake fauna, especially in tropical southern and mountainous western areas of the country with plethora of snake species. The list of medically important snakes, circumstances and effects of their bite, and necessary medical care require critical appraisal and should be updated regularly. This study aims to review and map the distributions of medically important snake species of Iran, re-evaluate their taxonomy, review their venomics, describe the clinical effects of envenoming, and discuss medical management and treatment, including the use of antivenom. Nearly 350 published articles and 26 textbooks with information on venomous and mildly venomous snake species and snakebites of Iran, were reviewed, many in Persian (Farsi) language, making them relatively inaccessible to an international readership. This has resulted in a revised updated list of Iran's medically important snake species, with taxonomic revisions of some, compilation of their morphological features, remapping of their geographical distributions, and description of species-specific clinical effects of envenoming. Moreover, the antivenom manufactured in Iran is discussed, together with treatment protocols that have been developed for the hospital management of envenomed patients.

Keywords: Iran; Elapidae; Hydrophiini; Viperidae; Snakebites; Antivenoms

1. INTRODUCTION

Paradoxically, snake [mɑːr in Persian (Farsi) language] has epitomized both "vivification/ vitality/agility/well-being/productivity" and "annihilation/cunning/treason" in Persian culture and literature (Afshari & Monzavi, 2016b; Rasmi, 2016). "Bimar", Persian for "patient", is a word compounded of "bi (= without)" and "mar"; denoting a living entity that has lost its vitality/well-being (bimar = without well-being) (Afshari & Monzavi, 2016b). Rooted in old Persian, and perhaps through mutual understanding and cultural exchange, these concepts may have contributed to an ancient Greek symbol, the "Rod of Asclepius", a serpent-entwined staff, representing health and healing. In addition, in historical remains and architecture of Persian territory, the snake is depicted with reverence, as signifying life, fertility, and blessings conferred on nature and the environment (Kazemi Shishavan & Maleki, 2018; Rasmi, 2016; Taheri, 2015).

Iran (literally means the land of Aryan people) covers an area of 1,648,195 square kilometers, bordering Armenia, Azerbaijan, and Turkmenistan in the north, Afghanistan and Pakistan in the east, and Iraq and Turkey in the west, and associated maritime boundaries with Kuwait, Iraq, Saudi Arabia, Bahrain, Oman, Qatar, and the United Arab Emirates across the Persian Gulf and the Sea (or Gulf) of Oman (also known as Sea of Makran) (**Fig. 1**). Iran is separated from the arid lowland areas of Iraq by the high Zagros Mountains, more than 4,000 m in altitude, and from the Caucasus and Turkmenistan's arid sandy deserts in the north and northeast, by the higher Alborz Mountains, at more than 5,500 m. The country's 31 provinces have widely varying climates (**Fig. 1**). Average annual rainfall is rarely more than 40 mm in some parts of central and southern Iran, but exceeds 600 mm in some western and northern regions. The faunal diversity of Iran is influenced by its geographical position interconnecting the Palearctic, Ethiopian and Oriental regions (Dehghani et al., 2014b; Hosseinzadeh et al., 2014; Jowkar et al., 2016). Iran's vast biological diversity and tropical/subtropical, and semi-arid climate, have provided an ideal habitat, in which many species of snakes and other reptiles have evolved. This has exposed Iranians to the potential health-related dangers of encounters with these creatures throughout history. Ancient Indo-Iranian (Aryan) healers and physicians practiced various and sometimes strange methods of treating snakebite~~s~~ victims, although some of them, contemporary with Thrita or Trita (the earliest known Aryan physician and producer of antidotes and remedies, in about 3000 BCE) (Ambartsumian, 2001; Dadashi Arani & Mastali Parsa, 2020; Jayne, 1919; Nayernouri, 2015), were said to have had a good knowledge of antidotal remedies for snakebites (Kaviani Pooya, 2010; Najmabadi, 1992; Saameie, 2020). More recently, the world-renowned Iranian physicians, Zakaria Razi (Abu Bakr al-Razi or Rhazes, 854-932 A.D.) and Ibn Sina (Avicenna, 980-1037 A.D.), advanced the knowledge on snakebites and envenoming management. At a time when the "snake stone" was one of the foundations of traditional snakebite treatment, Razi was among the few who questioned its usefulness. Through careful observation and scrutiny, he ultimately discredited its effectiveness (A'alam, 2000; Pymm, 2017). He used pressure bandaging

above the bite site and a kind of snakebite antidote (*Teriaq-e Afa'ei*) to treat the patients and he believed that the internal temperature of the patient should be increased using grape wine or naked lady lily (Rezaei-Orimi et al., 2022). Avicenna in his monumental masterpiece, *The Canon of Medicine*, provided classified diagnostic descriptions of bites of different venomous animals. He listed 30 different snakes and ranked them according to 3 classes based on lethality to humans. His therapeutic directives were based mainly on preventing venom's entering the bloodstream, i.e., by washing the wound, incision of the bite site and amputation of the bitten limb (for severe cases), and on the use of various herbal remedies depending on the snake species involved (Rezaei-Orimi et al., 2019).

Modern ophiology in Iran owes an enormous debt to the late Professor Mahmoud Latifi (1929-2005), a renowned herpetologist, who devoted his life to gathering information about the snakes of Iran (**Fig. 2**). Following 24 years of painstaking expeditions (1959 to 1983) across the whole country, Latifi and his team collected 62 species from 28 genera and 8 families of venomous and non-venomous snakes. These were the basis of research articles and, notably, his classic textbook, "Snakes of Iran", originally published in 1985 in Persian by the Iranian Department of Environment (IDE) (Latifi, 1985), and later translated into English through the support of the National Museum of Natural History, Smithsonian Institution and the Society for the Study of Amphibians and Reptiles (Latifi, 1991). The naming of *Montivipera latifii*, an endemic species of viper from the Lar valley in Mount Damavand, was fitting recognition of his endeavors. Latifi also pioneered antivenom production in Iran at the Razi Vaccine and Serum Research Institute in Karaj, supplying the country and the Middle East region for over 50 years. This program depended on the help of a network of snake catchers who brought snakes captured throughout Iran to the institute (**Fig. 2**). Another major contribution was the late Dr. Reza Farzanpay's (1934-2018) book "Ophiology" on the morphological characteristics of Iran's snakes [published in Persian, 1990] (Farzanpay, 1990). Dr. Farzanpay was best known for his work on scorpions and scorpion antivenoms at the Razi Institute. Zoological studies and conservation of wildlife, including snakes, in Iran are also indebted to the late Eskandar Firouz (1926-2020), a pioneering environmentalist and conservationist, who was the founding director of the IDE and a cofounder of the Convention on Wetlands of International Importance, also known as the Ramsar Convention (1971). In 1977, he was elected president of the International Union for Conservation of Nature and Natural Resources (IUCN). His book "The Complete Fauna of Iran" (2005) is an essential reference for anyone interested in the vertebrate fauna of Asia and the Middle East (Firouz, 2005) (**Fig. 2**).

Worldwide, the survival of snakes is threatened by human intrusion into their environment, global climatic change, and excessive collecting, for commercial reasons such as the sale of their body parts for food and medicines, venoms and skin (Almasieh et al., 2019; Ansari, 2020; Dehghani et al., 2014a; Jowkar et al., 2016; Reading et al., 2010; Yousefi et al., 2019). This is why

so many snake species are now in the IUCN's red list of threatened species (Betts et al., 2020). Therefore, accurate and up-to-date information about the geographical distribution and preferred habitats of different snake species is needed to conserve them and their ecosystems, and to make the human inhabitants of these regions aware of the risk of venomous snakebites (Yousefi et al., 2020). Determination of precise geographical distributions of venomous snake species is also important for developing preventive interventions to reduce human-snake encounters, and to improve medical services to make antivenom and other medical resources more readily available (Warrell, 2016). The list of medically-important snakes of Iran has not been critically reevaluated since the publication of Latifi's book in 1985 (Latifi, 1991, 1985). The present study has reviewed all relevant publications concerning the geographical distribution, morphology, taxonomy, venom composition, clinical effects of envenoming, and clinical significance of Iran's medically important snakes (i.e., front-fanged venomous, and non-front-fanged mildly-venomous snakes, both potentially dangerous to human health). Locally developed protocols for medical management of envenomed patients are also assessed in the light of international advances in clinical toxinology.

2. METHODS

A systematic review was performed using keywords including, "SNAKE", "SNAKEBITE", "ENVENOMING", "ENVENOMATION", "ANTIVENOM" and "IRAN"; as well as "species names" of snakes currently known to be part of herpetofauna of Iran, based on two reliable resources (Latifi, 1991, 1985; Safaei-Mahroo et al., 2015). Articles and scientific documents available up to the end of 2022 were explored in peer-reviewed biological and biomedical journals, as well as eminent indexing databases including Web of Science, PubMed, Scopus and Google Scholar. In addition, articles in Persian were retrieved from Iranian online repositories of scientific literature including the Scientific Information Database (SID) and IranDoc. Original studies of clinical findings of envenoming or LD_{50} studies of venom of snake species occurring in Iran, including studies not performed by Iranian scientists or those carried out in adjacent or neighboring countries, were also reviewed and reliable data extracted. A total of 2897 articles were identified, and after removal of 797 duplicates, the abstracts of the remaining titles were evaluated; and accordingly, 1768 irrelevant documents and those not meeting the required criteria were removed. Within the study objectives, 347 documents (including 186 studies from Iran and 161 articles about publications involving Iran's snake species occurring in other geographic regions) were finally determined to be eligible for review and were subjected to deeper scrutiny and analyses (**Fig. 3**). Ten Iranian clinical and environmental toxicology textbooks and compendia on Iranian herpetofauna, as well as sixteen international toxicology and toxinology textbooks were also reviewed for relevant information on Iranian snakes and snakebites (Afshari & Monzavi, 2016a; Balali-Mood & Shariat, 1999; Dehghani, 2010; Farzanpay, 1990; Firouz, 2005; Latifi, 1991, 1985; Mozaffari et al., 2016; Nabipour, 2012; Rajabizadeh, 2018; Zare Mirakabadi & Teymurzadeh, 2009). An Iranian website focusing on ecological information including Iran's wilderness deserts (https://www.irandeserts.com), which is directed by an expert team of scientists and interested volunteers, was accessed to retrieve relevant photos and information on the geographical biotopes of Iranian snakes. The http://reptile-database.reptarium.cz/, https://www.iucnredlist.org and https://www.inaturalist.org databases were also accessed to find relevant photos, taxonomic information and global conservation status of the Iranian snake species. Reports and guidelines endorsed by the World Health Organization (WHO), available on the WHO website (www.who.int/snakebites/resources), were also reviewed. Following consensus of all authors, retrieved materials that were deemed authentic were further interpreted, and compiled with tables, representative images of medically important snakes of Iran and their geographical distributions in regionalized distribution maps along with their global conservation status (based on IUCN).

3. RESULTS

3.1. Checklist of Iranian medically important snakes

Snakebite is not uncommon in Iran, at least for some Iranians who live and work in regions inhabited by a plethora of snake species, such as the tropical southern and mountainous western areas of the country. Various species of snakes and snakebites are reported, from islands in the Persian Gulf in the South, to the northernmost regions of the country (Afshari & Monzavi, 2016b; Dehghani, 2010; Nabipour, 2012). A total of 89 species have been identified, of which 30 are venomous, seventeen are mildly-venomous (non-front-fanged species) and the remainder are considered non-venomous (Dehghani, 2010; Dehghani et al., 2014c; Ebrahimi et al., 2018; Farzanpay, 1990; Fathinia et al., 2011; Firouz, 2005; Gholamifard, 2011; Hosseinian Yousefkhani et al., 2014; Latifi, 1991, 1985; Latifi et al., 1966; Malekoutian et al., 2018; Moradi et al., 2013; Mozaffari et al., 2016; Nabipour, 2012; Nasrabadi et al., 2016; Rajabizadeh, 2013, 2018; Ramezani et al., 2011; Rastegar-Pouyani et al., 2008; Safaei-Mahroo et al., 2015; Shaykhi Ilanloo et al., 2015; Soleimanfallah et al., 2018; Zare Mirakabadi & Teymurzadeh, 2009). While some species are widely distributed throughout the country, others are restricted to limited geographic regions (**Supplementary material - Table 1S**). Potential factors influencing the distribution of Iran's common venomous snakes include rainfall seasonality, alterations in habitat suitability, and vegetation properties (Yousefi et al., 2015; Yousefi et al., 2020). Some species have shown morphological adaptations to specific geographical locations (Fathinia & Rastegar-Pouyani, 2010; Gholamifard, 2011; Gholamifard & Esmaeili, 2010; Moradi et al., 2014; Navidpour et al., 2019; Rajabizadeh et al., 2012; Rastegar-Pouyani et al., 2008; Safaei-Mahroo et al., 2015; Todehdehghan et al., 2019; Yousefi et al., 2015).

In this study, at the family and subfamily levels, we followed the classification of Pyron et al. (Pyron et al., 2013). Accordingly, the functionally venomous snake species of Iran are grouped in the families Colubridae (subfamily Colubrinae), Lamprophiidae (subfamily Psammophiinae), Elapidae and Viperidae (subfamilies Crotalinae and Viperinae). While older works have frequently recognized subfamilies within the Elapidae (especially the subfamily Hydrophiinae for the marine elapids), recent studies (Figueroa et al., 2016; Pyron et al., 2013; Wallach et al., 2017; Zaher et al., 2019) have not supported this arrangement. Therefore, the subfamilies within the Elapidae are not recognized in this manuscript.

3.1.1. Non-front-fanged snakes

For humans, bites by the majority of opisthoglyphous (non-front-fanged or rear-fanged) snakes are mainly mildly or non-venomous, and are rarely severe, even though these snakes possess venoms containing components that are often highly toxic to their natural prey (Weinstein et al., 2023b; Weinstein et al., 2013). This is largely due to the fact that the venom-delivering fangs are at the back of the maxilla with lack of venom storage reservoir, and the venom glands lack

powerful compressor muscles (Modahl & Mackessy, 2019; Modahl et al., 2016; Saviola et al., 2014). Hence, except in a few documented cases, this precludes the injection of venom under high pressure and in quantities in sufficient to cause envenoming in humans, unlike the front-fanged (proteroglyphous and solenoglyphous) vipers and elapids (Araujo et al., 2018; Brandehoff et al., 2019; Dehghani et al., 2012; Weinstein et al., 2014). However, outside Iran, bites by a few opisthoglyphous species (e.g., *Dispholidus typus, Rhabdophis* spp., and *Thelotornis* spp.) can result in envenoming as dangerous as from front-fanged venomous snakes (Dashevsky et al., 2018; Junqueira-de-Azevedo et al., 2016; Weinstein et al., 2013). The mildly venomous non-front-fanged snakes of Iran belong to two families - Colubridae and Lamprophiidae (**Supplementary material - Table 1SA & Table 2S**). Their venoms contain proteins that are structurally convergent with those of front-fanged venomous snakes (Xie et al., 2022).

3.1.1.1. Colubridae

Over 40 colubrid species have been recorded in Iran, the majority of which are considered non-venomous, or whose bites are largely unstudied (Dehghani et al., 2014c; Dehghani et al., 2016a; Rastegar-Pouyani et al., 2008; Safaei-Mahroo et al., 2015). Among these, thirteen species in four genera (*Boiga, Hemorrhois, Platyceps* and *Telescopus*) are considered mildly venomous (Dehghani et al., 2016a; Moradi et al., 2021; Rastegar-Pouyani et al., 2008; Safaei-Mahroo et al., 2015; Schaetti et al., 2012). *Boiga* and *Telescopus* species in Iran are functionally venomous, whereas symptomatic envenoming after bites by *Hemorrhois* and *Platyceps* species has not been adequately documented.

The black-headed cat snake (*Boiga trigonata melanocephala*) occurs exclusively in eastern Iran, whereas *Hemorrhois, Platyceps and Telescopus* species collectively inhabit most regions of the country, although their diversity is greatest in the western third of the country, and lowest in the deserts of the center (Moshtaghie et al., 2018; Safaei-Mahroo et al., 2015). The recent discovery of the black-headed tiger snake (*Telescopus nigriceps*) in the southwest of Iran, close to the Iraq border, has increased the number of *Telescopus* species in Iran to five (**Table 1S**) (Nilson & Rastegar-Pouyani, 2013; Rastegar-Pouyani et al., 2008; Safaei-Mahroo et al., 2015). The type specimen of *Platyceps rhodorachis* was from Persia (De Filippi, 1865). *P. rhodorachis* and *T. rhinopoma* have also been recorded on some southern islands of Iran (Latifi, 1991), i.e., *P. rhodorachis* on Kharg (or Khark), Kish, Qeshm, Hengam and Hormoz Islands; and *T. rhinopoma* on Kharg Island.

3.1.1.2. Lamprophiidae

The four species of Iranian Lamprophiidae are members of the subfamily Psammophiinae in the genera *Psammophis* and *Malpolon* (**Table 2S**). Snakes in the closely-related Lamprophiidae and Elapidae families are sometimes referred to jointly as the superfamily Elapoidea (Kelly et al., 2009), but Elapoidea have now been shown to be paraphyletic. *Psammophis lineolatus*,

Psammophis schokari, *Malpolon insignitus fuscus* and *Malpolon moilensis* occur in Iran. In the Persian Gulf, *P. schokari* is recorded from Kharg and Qeshm Islands, and *M. moilensis* from Kharg Island (Latifi, 1991). Iran has been the easternmost global distribution of the genus *Malpolon* (Safaei-Mahroo et al., 2016).

3.1.2. Front-fanged venomous snakes

Iran's front-fanged venomous snakes belong to two families, Elapidae (terrestrial and marine elapids) and Viperidae [Crotalinae (pit vipers) and Viperinae (true/Old World vipers)], which altogether include 30 species (**Tables 1SB & 3S**) (Gholamifard et al., 2012; Rastegar-Pouyani et al., 2008; Rezaie-Atagholipour et al., 2016; Safaei-Mahroo et al., 2015). The truly endemic venomous species of Iran are *Macrovipera razii*, *Montivipera latifii*, *Montivipera kuhrangica*, and *Bungarus persicus* (Abtin et al., 2014; Bok et al., 2017; Fathinia et al., 2016; Gholamifard, 2011; Oraie, 2020; Oraie et al., 2018; Rajabizadeh et al., 2011a; Rajabizadeh et al., 2012).

3.1.2.1. Elapidae

In Iran, 14 elapid species in 4 genera have been recorded, characterized by their proteroglyphous fangs and circular pupils (**Table 1SB & 3S**) (Firouz, 2005; Latifi, 1985; Rastegar-Pouyani et al., 2008; Shoorabi et al., 2017). Among the terrestrial elapids, the most widely distributed species are the Central Asian/Oxus/Caspian Cobra (*N. oxiana*) (Shoorabi et al., 2017), and the Eastern black desert or Morgan's Cobra (*Walterinnesia morgani*) (Nilson & Rastegar-Pouyani, 2007). The Iranian/Persian krait (*Bungarus persicus*), a relatively recent addition to the list of Iranian Elapidae, is restricted to the southeastern part of the country (Abtin et al., 2014; Rajabizadeh, 2018). It is the westernmost geographically distributed member of the genus Bungarus (Abtin et al., 2014).

***Bungarus*:** *B. persicus* was discovered approximately 100 kilometers west of the Pakistan border, north of Sarbaz in Iran's Sistan and Baluchistan province (Abtin et al., 2014). It is distinguished from its closest relative *B. sindanus* by a unique small loreal scale or loreal black spot and higher numbers of ventral and subcaudal scales. Recently, there were two other reports from Bashagard, Hormozgan province (Shahi et al., 2022). There has also been a report of likely specimen collected in Ras Jiwani in Pakistan's Baluchistan region, just across the Pakistan-Iran borders, which was perhaps misidentified as *B. caeruleus* (Shockley, 1949).

***Naja*:** *N. oxiana* is distributed in northeastern and possibly eastern Iran, Afghanistan, northwestern India (Jammu and Kashmir, and Himachal Pradesh), northern and western Pakistan, southern Turkmenistan, southwestern Tajikistan and southern Uzbekistan (Kazemi et al., 2021a; Kazemi et al., 2021b; Yousefi et al., 2020).

***Walterinnesia*:** *W. morgani* has been reported from northern, western and southern parts of Iran, and, elsewhere, in Iraq, southeastern Turkey (Urfa), Syria, Saudi Arabia, and Kuwait (Gholamifard & Rastegar-Pouyani, 2012; Nilson & Rastegar-Pouyani, 2007).

***Hydrophis*:** Marine elapids are represented in the Persian Gulf and the Sea of Oman by 11 species in the monophyletic clade Hydrophiini (viviparous sea snakes) (Gillett et al., 2014; Heydari Sereshk & Riyahi Bakhtiari, 2014; Lillywhite et al., 2014; Mirtschin et al., 2018; Nabipour, 2012; Rezaie-Atagholipour et al., 2016; Rezaie-Atagholipour et al., 2012a; Rezaie-Atagholipour et al., 2012b; Sanders et al., 2013). The most recent addition to Iran's list of sea snakes is Günther's or Cantor's narrow-headed sea snake (*Hydrophis cantoris*) (Rezaie-Atagholipour et al., 2016). *H. cantoris*, *H. viperinus* and *H. cyanocinctus* live in deep waters and are occasionally caught in fishing nets. Although rarely seen, they are not in danger of extinction. The beaked sea-snake (*H. schistosus*) has a very potent venom, making it perhaps the deadliest snake of Iran (**Tables 1S, 3S**). Elsewhere, it has been proven to be the most medically important sea-snake species (Mirtschin et al., 2018). The yellow-bellied sea-snake (*H. platurus*) is a pelagic species (inhabiting the open ocean) which floats, feeds, and, remarkably, drinks fresh rain water after storms on the sea surface (Gillett et al., 2014; Lillywhite et al., 2014). Stokes's sea-snake (*H. stokesii*) has been recorded in the Makran coast of Baluchistan in Pakistan, contiguous with Iran's Makran coast of Baluchistan, making it highly probable that this species also occurs in Iran's coastal waters (Rastegar-Pouyani et al., 2008). Despite their prodigious numbers, all species of sea-snakes are threatened by rapidly-increasing water pollution, fishing activities and marine vessel traffic (Heydari Sereshk & Riyahi Bakhtiari, 2014; Rezaie-Atagholipour et al., 2012a; Rezaie-Atagholipour et al., 2012b; Yaghmour et al., 2022).

3.1.2.2. Viperidae

The 16 Viperidae species (belonging to eight genera and two subfamilies) recorded in Iran (**Table 1S & 3S**) are characterized by vertically elliptical pupils, marked flattened triangular (wedge-shaped) head, and retractable solenoglyphous fangs (**Fig. 4**). The most widely distributed species are the Sindh or Sochurek's Saw-scaled viper (*Echis carinatus sochureki*), Blunt-nosed or Levantine Viper (*Macrovipera lebetina*), and Persian Horned Viper (*Pseudocerastes persicus*) (Dehghani et al., 2014b; Fathinia & Rastegar-Pouyani, 2010; Moradi et al., 2014; Rastegar-Pouyani et al., 2008; Safaei-Mahroo et al., 2015). These species are responsible for the majority of human snakebite envenomings in Iran (Dehghani et al., 2014b; Dehghani et al., 2012; Monzavi et al., 2019a; Monzavi et al., 2019b).

***Cerastes*:** The Arabian or Desert Horned Viper (*Cerastes gasperettii*) occurs in southwestern Iran, inhabiting arid areas around oases in Khuzestan (Carné et al., 2020; Spawls & Branch, 1995). It has also been seen on Tahmadu (Jabrin) Island in the Persian Gulf (Latifi, 1991). Based on morphological observations, Werner et al. proposed that *C. gasperettii* be divided into to two

subspecies (i.e., *C. g. gasperettii* and *C. g. mendelssohni*). However, a recent molecular phylogenetic analysis has questioned this subspecific division (Carné et al., 2020).

***Echis*:** Despite studies suggesting that two distinct taxa of *Echis* occur in Iran, *E. multisquamatus* Cherlin, 1981 and *E. carinatus sochureki* Stemmler, 1969 (Bagherian & Kami, 2008; Cherlin, 1981; Cherlin, 1990), they have been synonymized based on more recent evidence of molecular phylogeny and clinal variation in morphology (Arnold et al., 2009; Navidpour et al., 2019; Pook et al., 2009). Hence, only one *Echis* taxon, i.e., *E. carinatus sochureki*, is recognized in Iran. The species is widely distributed in the country, except in the northwest parts. It also occurs on Kharg, Shif, Lavan, Kish, Qeshm, Greater Tunb and Hormoz Islands in the Persian Gulf (Latifi, 1991).

***Eristicophis*:** MacMahon's Desert Viper or Leaf-nosed Viper (*Eristicophis macmahonii*) is an uncommon monotypic species native to the dry loose sandy desert regions in the extreme east of Iran (e.g., Tasouki) that share borders with Afghanistan and Pakistan (**Tables 1S, 3S**). It was first described by Alcock, Finn, Maynard and McMahon in 1896 close to the Iran border in Pakistan (Amirchah, Zeh, Drana Koh and Robat I. between 760 and 1,360 m altitude (Alcock et al., 1896), and in Iran by Guibé (Guibé, 1957) as "*Pseudocerastes latirostris*" from "Taraki 120 km after Zabol on the way to Zahedan" near to the Afghanistan border, and by Latifi (Latifi, 1991), who examined one specimen from Kerman and a few others from the Iran-Pakistan border (Latifi, 1991). Sindaco shows a record from near Zahak (Sindaco et al., 2013) and Joger (Joger, 1984) shows two records from the Zahak "bulge" but does not specify a source. Based on Papenfuss et al.'s assessment, this species also occurs near Jiroft, Kerman province (Papenfuss et al., 2021). It is a small irritable viper, characterized by two butterfly-shaped laterally projecting naso-rostral scales, which help prevent sand entering its nostrils, especially when the animal burrows down into the sand concealing itself to ambush prey.

***Gloydius*:** The Caucasian Pit Viper (*Gloydius caucasicus*) is Iran's only pit viper. Recently it was elevated from being a subspecies of *G. halys* to full species rank (Asadi et al., 2019; Shi et al., 2016). It inhabits a range of environments in the Hyrcanian broad-leaved forest of the Alborz range, in northeastern to northwestern Iran, and in southeast Azerbaijan, ranging in altitude from 30 to 3000 m above sea level (Ghelichy Salakh et al., 2020; Khani et al., 2017). It is the most westerly species of Crotalinae in the Palearctic (Asadi et al., 2019; Ghelichy Salakh et al., 2019; Shi et al., 2016). This species has been regularly collected by the Razi Institute for antivenom production since 1924 (Asadi et al., 2019).

***Macrovipera*:** The Blunt-nosed or Levantine Viper (*Macrovipera lebetina*) is widely distributed from Turkey and Cyprus east to Kashmir. In Iran, two sub-species are recognized, *M. lebetina obtusa* in the northwest and *M. l. cernovi* (Cernov's Viper) in the northeast (Stümpel & Joger, 2009; Stümpel et al., 2016). Recently, a second species of potential medical importance, Razi's viper (*Macrovipera razii*), has been identified in the Zagros Mountains of central and southern Iran, distinguished from *M. lebetina* by mitochondrial Cytb gene sequence phylogeny and

morphology (Oraie, 2020; Oraie et al., 2018). Compared to *M. lebetina, M. razii* has higher ventral scale counts, elongated anterior chin-shields, and lower numbers of canthal and inter-supraocular scales.

***Montivipera*:** The three closely-related species of the *Montivipera raddei* complex in Iran comprise *M. raddei*, *M. latifii*, and *M. kuhrangica* (Behrooz et al., 2018; Fakharmanesh et al., 2014; McDiarmid et al., 1999; Rajabizadeh, 2013; Stümpel et al., 2016; Yousefi et al., 2015). Through molecular analyses (on the basis of nuclear and mitochondrial genes), the sub-specific status of *M. raddei kurdistanica* and *M. raddei albicornuta* was not supported, implying that they should be collapsed into *M. raddei* (Stümpel et al., 2016). Phylogenetic evaluations also suggested that *M. latifii* is a separate evolutionary lineage from the closely-related Armenian, Caucasus or Radde's Viper (*M. raddei*). This was confirmed by the distinctive ecological adaptation of *M. latifii* to alpine habitats in the Alborz Mountains, where it can remain active despite the cold climate (Stümpel et al., 2016; Yousefi et al., 2015). Although regarded by some as diverging populations of the same species (Rastegar-Pouyani et al., 2014), using mitochondrial gene assay, phylogenetic and phylogeographic analyses, it has been shown that *M. latifii* and *M. kuhrangica* represent two monophyletic clades (Behrooz et al., 2018). Latifi's Viper (*M. latifii*), an endemic species, possesses a venom more potent than the venoms of other Iranian Viperidae except *E. c. sochureki* and *M. raddei* (**Table 1**) (Archundia et al., 2011; Latifi, 1984; Weinstein & Minton, 1984). Several species of the raddei complex, especially *M. latifii*, are rare and listed as "threatened" in the IUCN's red list (Ahmadi et al., 2019; Yousefi et al., 2015) with *M. latifii* classed as "endangered". This latter species has been subject to irrational killings, and its distribution is restricted to the Lar Valley, central Alborz region (Asadi et al., 2016; Behrooz et al., 2015; Rajabizadeh et al., 2012). The Kuhrang mountain viper (*M. kuhrangica*) is another endemic *Montivipera* that is restricted to the Central Zagros region and is rarely observed (Rajabizadeh et al., 2011a). The occurrence of Wagner's or ocellate mountain viper (*M. wagneri*) in Iran is uncertain. Although Nilson and Andrén reported a type locality of the species in the "vicinity of Lake Urmia" in northwestern Iran (Nilson & Andrén, 1984), it has not been reliably observed in the country since then (Kumlutas et al., 2015; Rastegar-Pouyani et al., 2008), although recent explorations have demonstrated a wide range for *M. wagneri* in eastern Turkey towards its border with northwestern Iran (Mebert et al., 2020).

***Pseudocerastes*:** The horns of "false horned vipers" (*Pseudocerastes*) are composed of numerous small supraocular scales, rather than the single supraocular scales of the genus *Cerastes* (Bok et al., 2017; Fathinia et al., 2014). The Persian horned viper *(Pseudocerastes persicus*) is perhaps the most widely distributed viper species in the Middle East, from Northern Iraq to Pakistan with isolated populations in mountains of the South-East Arabian Peninsula (Sindaco et al., 2013). Field's horned viper (*P. fieldi*) is separated from *P. persicus* in its geographical range by the Zagros Mountains, and, although formerly classified as a sub-species, is now recognized as a separate

species, based both on morphological features and differences in venom composition (Bdolah, 1986; Dehghani et al., 2014c; Gholamifard & Esmaeili, 2010). *P. persicus* has uniformly keeled scales and a longer tail than *P. fieldi*. The southern localities for *P. fieldi* in Iran need to be confirmed (Sindaco et al., 2013), while it is likely that the Fars record from a decade ago (Gholamifard & Esmaeili, 2010), was based on a misidentified *P. persicus*. In general, controversy has remained, and while some scientists do not recognize *P. fieldi* from Iran and suggest that all *P. fieldi* records from Iran were perhaps *P. persicus* (Fathinia et al., 2018; Safaei-Mahroo et al., 2015), others have reported the occurrence of *P. fieldi* in western and central Iran (Dehghani et al., 2014c; Mozaffari et al., 2016). The spider-tailed horned viper (*Pseudocerastes urarachnoides*), occurs in the west of Iran, and is also reported from the extreme East of Iraq (Al-Sheikhly et al., 2019; Al-Sheikhly et al., 2020; Fathinia et al., 2020). It has an extraordinary bristle-brush-like appendage on the tip of its tail (**Table 1S**). It was first collected during an American museum expedition in 1968, but neither the integrity of its solpugid/solifugid (camel spider)-like caudal appendage, a lure that attracts prey such as small birds and lizards, nor its specific status were appreciated until 2006 (Bostanchi et al., 2006; del Marmol et al., 2016; Fathinia et al., 2009; Fathinia et al., 2016).

***Vipera*:** The Alburzi or Armenian steppe viper (*Vipera eriwanensis*) is distributed over northwest Iran, northeast Turkey and Transcaucasia (Rajabizadeh et al., 2011b), and is in danger of extinction (Tuniyev et al., 2009a). It was formerly considered a subspecies of the *V. ursinii* complex (Rajabizadeh et al., 2011b). Höggren et al. recognized *V. eriwanensis* as a distinct species (Höggren et al., 1993), a status supported by a more recent study (Zinenko et al., 2015). Ebner's viper (*V. ebneri*) has been reported from the central Alborz and the northernmost Zagros mountains. It was previously regarded as a sub-species of *V. eriwanensis* (Kukushkin et al., 2012; Rajabizadeh et al., 2011b; Rastegar-Pouyani et al., 2008), but species status was supported by Zinenko et al. (Zinenko et al., 2015). The zoogeographic status of the Transcaucasian sand viper (*Vipera ammodytes transcaucasiana*), has remained controversial (Mülder, 2017; Stümpel & Joger, 2009; Tok & Kumlutş, 1996). While it has been reported from extreme northwestern Iran, these reports seem unreliable, and its presence in the country has not been rigorously established (Mülder, 2017; Safaei-Mahroo et al., 2015; Tuniyev et al., 2009b). Elsewhere, it occurs in northern Turkey, Georgia, and northwest Azerbaijan (Mülder, 2017). Some herpetologists consider it a sub-species of *V. ammodytes,* whereas others accord it the status of a full species (Nilson et al., 1999).

3.2. A brief review of studies on the venoms of some Iranian snakes

Experimental studies of Iranian snake venoms date from Latifi's original studies on venom yield and lethal potency (Latifi, 1984), to more recent cytotoxic assays, and the application of proteomics or venomics (Ghezellou et al., 2021; Ghezellou et al., 2019). Lethal doses (LD_{50}) of the venoms of some common Iranian snakes of medical importance are presented in **Table 1.**

Table 1. Lethal doses (LD_{50}) of Iran's medically important snakes (Studies on mouse using crude venom)

Species/Subspecies	Route of injection	Reporting format	Result (mg/kg)	Reference
Cerastes gasperettii	i.p.	Median	0.98	(Al-Sadoon et al., 2016)
	i.p.	Median	1.32	(Zaeri et al., 2021a)
Echis carinatus sochureki	i.p.	Median	1.68	(Ghezellou et al., 2021)
	i.v.	Mean ± SD	0.25 ± 0.06	(Latifi, 1984)
	i.v.	Median (Range)	0.26 (0.2-0.32)	(Latifi & Tabatabai, 1989)
	i.v.	Median (95% CI)	0.55 (0.44-0.69)	(Salmanizadeh et al., 2013)
	i.v.	Median	0.57	(Nasri Nasrabadi et al., 2022)
Gloydius caucasicus (halys)	i.p.	Median	1.45	(Fathi et al., 2022)
	i.v.	Mean ± SD	0.69 ± 0.04	(Latifi, 1984)
	i.p	Median	0.84-0.92	(Rasoulinasab et al., 2020)
Hydrophis cantoris	s.c.	Median	0.5	(Reid, 1956)
Hydrophis curtus	i.v.	Median	0.7	(Alam & Qasim, 1993)
	i.p.	Median	0.12	(Carey & Wright, 1960)
	i.v.	Median (95% CI)	0.2 (0.18-0.24)	(Tan et al., 2018)
Hydrophis cyanocinctus	i.v.	Median	0.6	(Alam & Qasim, 1993)
	i.p.	Median	0.8	(Ali et al., 1999a)
	i.v.	Median (95% CI)	0.29 (0.26-0.32)	(Baxter & Gallichio, 1976)
	s.c.	Median (95% CI)	0.49 (0.44-0.56)	
	i.v.	Median	0.13	(Calvete et al., 2012)
	i.p.	Median	0.17	
Hydrophis gracilis	s.c.	Median (95% CI)	0.51 (0.44-0.59)	(Baxter & Gallichio, 1976)
Hydrophis ornatus	i.m.	Median	0.16	(Tamiya & Puffer, 1974)
	i.v.	Median	2.2	(Tu, 1974)
Hydrophis platurus	i.p.	Median (95% CI)	0.12 (0.08-0.18)	(Lomonte et al., 2014)
	i.v.	Median (95% CI)	0.2 (0.04-0.32)	
Hydrophis schistosus	i.v.	Median (95% CI)	0.1 (0.08-0.11)	(Baxter & Gallichio, 1976)
	s.c.	Median (95% CI)	0.12 (0.1-0.14)	
	s.c.	Median (95% CI)	0.16 (0.15-019)	(Broad et al., 1979)
	i.v.	Median (95% CI)	0.07 (0.05-0.09)	(Tan et al., 2015)
	i.v.	Median	0.14-0.21	(Tu, 1974)
Hydrophis spiralis	i.v.	Median	0.4	(Alam & Qasim, 1993)
	i.p.	Median	0.58	(Carey & Wright, 1960)
Hydrophis stokesii	i.v.	Median (95% CI)	0.17 (0.15-0.2)	(Baxter & Gallichio, 1976)
	s.c.	Median (95% CI)	0.28 (0.24-0.31)	
Hydrophis viperinus	i.v.	Median	4.5	(Tu, 1974)
Macrovipera lebetina cernovi	i.v.	Median (95% CI)	0.88 (0.65-1.2)	(Archundia et al., 2011)
	i.v.	Median (95% CI)	0.99 (0.92-1.0)	(Garcia-Arredondo et al., 2019)
Macrovipera lebetina obtusa	i.v.	Median (95% CI)	1.51 (1.32-1.72)	(Archundia et al., 2011)
	i.v.	Median	0.9	(Elfiky et al., 2022)
	i.p.	Range	2.5-2.8	(Eskafi et al., 2021)
	i.p.	Median	3.87	(Fathi et al., 2022)

Table 1. Lethal doses (LD_{50}) of Iran's medically important snakes (Studies on mouse using crude venom)

Species/Subspecies	Route of injection	Reporting format	Result (mg/kg)	Reference
	i.v.	Median (95% CI)	0.82 (0.79-0.85)	(Garcia-Arredondo et al., 2019)
	i.v.	Mean ± SD	0.92 ± 0.07	(Kurtovic et al., 2014)
	i.v.	Mean ± SD	0.32 ± 0.07	(Latifi, 1984)
	i.p.	Median (95% CI)	1.75 (0.95-2.75)	(Pla et al., 2020)
	s.c.	Median	3.0	(Schöttler, 1938)
Malpolon insignitus (*monspessulanus*)	i.v.	Median	6.5	(Rosenberg et al., 1985)
Montivipera latifii	i.v.	Median	0.4	(Archundia et al., 2011)
	i.p.	Median	0.84	(Fathi et al., 2022)
	i.v.	Median (95% CI)	0.28 (0.24-0.31)	(Garcia-Arredondo et al., 2019)
	i.v.	Mean ± SD	0.28 ± 0.04	(Latifi, 1984)
	i.v.	Median (95% CI)	0.35 (0.31-0.42)	(Weinstein & Minton, 1984)
	i.p.	Median (95% CI)	2.07 (1.73-2.47)	
	s.c.	Median (95% CI)	4.61 (3.82-5.55)	
Montivipera raddei	i.v.	Median (95% CI)	0.19 (0.19-0.2)	(Archundia et al., 2011)
	i.p.	Range	1.63-2.05	(Fathi et al., 2022)
	i.v.	Median (95% CI)	0.2 (0.16-0.23)	(Garcia-Arredondo et al., 2019)
	i.v.	Mean ± SD	0.46 ± 0.03	(Kurtovic et al., 2014)
	i.v.	Mean ± SD	0.36 ± 0.05	(Latifi, 1984)
Naja oxiana	i.v.	Median	0.56	(Kazemi-Lomedasht et al., 2019)
	i.v.	Mean ± SD	0.42 ± 0.05	(Latifi, 1984)
	i.v.	Median	0.49	(Latifi & Tabatabai, 1989)
	s.c.	Median	0.45	(Minton, 1967)
Pseudocerastes fieldi	i.v.	Median	0.25	(Batzri-Izraeli & Bdolah, 1982)
	i.v.	Median	1.06	(Elfiky et al., 2022)
	i.p.	Median	1.0	(Gitter et al., 1962)
Pseudocerastes persicus	i.v.	Mean ± SD	0.81 ± 0.14	(Latifi, 1984)
	i.v.	Median	1.1	(Madani et al., 2018)
Vipera ammodytes transcaucasiana	i.v.	Median (95% CI)	0.4 (0.35-0.31)	(Garcia-Arredondo et al., 2019)
Vipera eriwanensis	i.v.	Mean ± SD	1.09 ± 0.03	(Latifi, 1984)
Walterinnesia morgani	i.p.	Median (95% CI)	0.66 (0.13-3.37)	(Calvete et al., 2021)
Pooled venom (*N. oxiana, C. gasperettii, E. c sochureki, M. l. obtusa, G. caucasicus,* and *M. raddei*)*	i.p.	Median	0.57	(Kadkhodazadeh et al., 2020)

* The six common snakes of medical importance in Iran

Abbreviations: i.p. = intraperitoneal, i.v. = intravenous, s.c. = subcutaneous, LD50 = 50% lethal dose

The LD_{50} values summarized in **Table 1**, indicate that some Hydrophiini have the most potent venoms among Iranian venomous snakes. *H. schistosus* has the most lethal venom, followed closely by *H. platurus*, *H. curtus* and *H. cyanocinctus*. Among Iranian terrestrial species, *M. raddei* has the most lethal venom, closely followed by *M. latifii* and *E. c. sochureki*.

3.2.1. Colubridae and Lamprophiidae: Despite advances in 'omics' profiling of venoms, the venoms of non-front-fanged snakes remain largely unexplored (Modahl et al., 2016). However, a combination of transcriptomic, proteomic and genomic studies has revealed that some non-front-fanged snake venoms contain many protein families similar to those found in Viperidae and Elapidae, such as three-finger toxins (3FTxs), snake venom metalloproteinases (SVMPs), phospholipases A_2 (PLA_2), serine proteases, hyaluronidases, L-amino acid oxidases (LAOs), C-type lectins (CTLs) and Cysteine-Rich Secretory Proteins (CRiSPs) (Junqueira-de-Azevedo et al., 2016; Modahl et al., 2016). These venoms are highly toxic to diapsid (birds and reptiles) prey, but are usually less potent and typically produce weaker, negligible, or no neurotoxic effects in mammals (Dashevsky et al., 2018). Clinically, bites by most non-front-fanged species pose lower risks to humans compared with vipers and elapids, as discussed earlier.

Iranian non-front-fanged snake genera, whose venoms are rich in 3FTxs, include *Boiga* and *Psammophis* (Modahl & Mackessy, 2019; Sunagar et al., 2013). *Platyceps rhodorachis* venom is also rich in 3FTxs, as analyzed with liquid chromatography and mass spectrometry (Fry et al., 2003). Likewise, *Telescopus* species venoms contain 3FTx (such as denmotoxin and irditoxin) but in lower yields (Dashevsky et al., 2018; Junqueira-de-Azevedo et al., 2016; Lumsden et al., 2004; Modahl & Mackessy, 2019). *Hemorrhois* species venoms may contain anticoagulant toxins (Ana Maria, 2021) and venoms of some *Boiga* species such as *B. irregularis* contain serine proteases, with known fibrinogenolytic activity (Mackessy, 2002). Venoms of *Malpolon* species are potentially dangerous because of their pro-hemorrhagic fraction (intravenous LD_{50} = 1 mg/kg), but coagulopathy has never been reported in human victims (Rosenberg et al., 1992).

3.2.2. Elapidae and Viperidae: Venoms of Iranian elapids are usually rich in 3FTxs, whereas those of Iranian vipers are usually rich in SVMPs (Ghezellou et al., 2021; Modahl et al., 2016; Mohebbi et al., 2016; Monzavi et al., 2019a). The composition, and pharmacological and pathophysiological properties of venoms of some species are described as follows:

Bungarus sp.: There is no published report of *B. persicus* venom or clinical effects of envenoming. However, the venoms of closely-related species such as *B. sindanus* and *B. caeruleus*, which are notorious for their neurotoxic effects, are rich in 3FTxs (including α-bungarotoxin) and PLA_2s (including β-bungarotoxin~~s~~) and also contain SVMPs, LAOs, acetylcholinesterase, CRiSPs and Kunitz-type serine protease inhibitors (Oh et al., 2019; Patra et al., 2019; Sunagar et al., 2021).

***Cerastes gasperettii*:** The major components of *C. gasperettii* venom are SVMPs, serine proteases, PLA_2, CTLs, disintegrins, CRiSPs, and LAOs (Al-Sadoon et al., 2016; Zaeri et al., 2021a).

457 In mice, the venom can cause severe hepatic inflammation and necrosis, glomerular
458 degeneration and coagulative necrosis of the kidney, lung congestion, testicular tissue
459 degeneration, myonecrosis, hemodynamic disturbances (reduction in mean arterial pressure
460 and bradycardia), and hemorrhage (Al-Sadoon et al., 2013a; Al-Sadoon et al., 2013b; Al-Sadoon
461 et al., 2014; Al-Sadoon et al., 2016; Bassam, 1995; Zaeri et al., 2021a).

462 ***Echis carinatus sochureki***: Its venom is rich in SVMPs, and also contains serine proteases, PLA_2s,
463 LAOs, CTLs, disintegrins, CRiSPs, hyaluronidase, and growth factors (Casewell et al., 2009). The
464 venom possesses pro-coagulant properties such as prothrombin activation (Babaie et al.,
465 2013a; Mehdizadeh Kashani et al., 2012; Nasri Nasrabadi et al., 2022; Salmanizadeh et al.,
466 2013), and anticoagulant activities (Amrollahi Byoki & Zare Mirakabadi, 2013; Babaie et al.,
467 2013b; Ghezellou et al., 2021; Latifi & Tabatabai, 1989; Mehdizadeh Kashani et al., 2012; Nasri
468 Nasrabadi et al., 2022), such as fibrinogenolytic (Kamyab et al., 2017) and anti-platelet effects
469 (Babaie et al., 2013b; Mehdizadeh Kashani et al., 2012). Animal and *in vitro* experiments
470 revealed that the venom can also induce hemodynamic instability, acute tubular necrosis,
471 interstitial pulmonary inflammation, neurotoxicity and myotoxicity (Barfaraz & Harvey, 1994;
472 Harvey et al., 1994; Zaeri et al., 2021b). In addition, it has *in vitro* cytotoxic effects (Balali
473 Bahadorani & Zare Mirakabadi, 2016; Zare Mirakabadi & Horrieh, 2020).

474 ***Eristicophis macmahonii***: Venom of a specimen from Nushki, Baluchistan in Pakistan, consisted
475 of SVMPs, kallikrein serine proteases, LAOs and PLA_2, disintegrins, lectins, CRiSPs and vascular
476 endothelial growth factor (VEGF) (Ali et al., 2015). The venom inhibits platelet aggregation and
477 causes edema in mice (Ali et al., 1999b). Its venom is also procoagulant (Op den Brouw et al.,
478 2021a), fibrinogenolytic (Op den Brouw et al., 2021b), and has anti-cancer activities (Op den
479 Brouw et al., 2021a; Op den Brouw et al., 2021b).

480 ***Gloydius caucasicus***: Its venom has pro-hemorrhagic, necrotizing, and edematogenic activities,
481 and contains a non-protease anticoagulant factor (Ghorbanpur et al., 2010), and pro-coagulant
482 effects (Rasoulinasab et al., 2020), attributable to a serine protease (Ghorbanpur et al., 2009). *In*
483 *vitro*, the venom has shown anti-cancer effects on colon cancer cells (Salmanzadeh Zehkesh &
484 Mohammadpour Donighi, 2021)

485 ***Hydrophis spp.:*** The venoms of Iranian *Hydrophis* are rich in 3FTxs (> 50%), and neuromyotoxic
486 PLA_2s, explaining their lethal potency. Other components include SVMPs, LAOs and CRiSPs in
487 very low quantities. (Calvete et al., 2012; Mohebbi et al., 2016). Venoms are powerfully anti-
488 bacterial *in vitro* (Abtahi et al., 2014).

489 ***Macrovipera lebetina***: Venom of both *M. l. obtusa and M. l. cernovi* contain enzymes, such as
490 PLA_2 and hyaluronidase, explaining local tissue damage , and pro-coagulant factor V and X
491 activators (Amoozegari et al., 2016; Amoozegari et al., 2013; Ghezellou et al., 2022; Igci &
492 Demiralp, 2012; Sanz et al., 2008; Shanaki Bavarsad et al., 2009), linked to coagulopathy.

493 Experimental evidence showed a PLA_2 vasodilator component responsible for hemodynamic
494 instability and circulatory failure (Fatehi-Hassanabad & Fatehi, 2004). Proteomic studies
495 revealed a serine protease that can lead to coagulopathy and platelet aggregation (i.e., a
496 unique short disintegrin known as obtustatin, dimeric disintegrin, CTLs and LAO), and Zn^{2+}-
497 SVMPs that can damage the vascular endothelium (Amoozgari et al., 2020; Bazaa et al., 2005;
498 Ghezellou et al., 2022; Hamza et al., 2010; Pla et al., 2020; Sanz et al., 2008). The venom also
499 contains large amounts of bradykinin-potentiating peptides (BPPs), C-type natriuretic peptides
500 (C-NAP) and possibly nitric oxide or nitric oxide-like compounds contributing to hypotensive
501 effects (Bazaa et al., 2005; Fatehi-Hassanabad & Fatehi, 2004; Pla et al., 2020; Sanz et al., 2008),
502 and VEGF-like molecules (svVEGF) that cause increased capillary permeability (Bazaa et al.,
503 2005). The venom has shown *in vitro* fibrinolytic activity (Amoozgari et al., 2020; Hamza et al.,
504 2010), cytotoxicity (Esmaeili Jahromi et al., 2016; Kakanj et al., 2015; Oghalaie et al., 2017), and
505 considerable affinity to mimic epitopes of human alpha 1 neuronal nicotinic acetylcholine
506 receptors (Chowdhury et al., 2022), and in animal models has caused cardiovascular collapse
507 and neuromuscular blockade (Fatehi-Hassanabad & Fatehi, 2004).

508 ***Montivipera latifii***: Its venom contains a pro-coagulant serine protease isoform (Taherian et al.,
509 2016), and can cause pro-hemorrhagic and necrotizing effects (Weinstein & Minton, 1984). It
510 can damage the lipid bilayer of erythrocyte membrane causing hemolysis (Ghulikyan et al.,
511 2016; Kirakosyan et al., 2016). It also has anti-cancer and anti-bacterial effects *in vitro*
512 (Moridikia et al., 2018).

513 ***Montivipera raddei***: Proteomics of Armenian *M. raddei* venom revealed toxins similar to those
514 of *M. l. obtusa* venom, such as dimeric disintegrin, CRiSPs, PLA_2, serine protease, CTL, LAO,
515 svVEGF, Zn^{2+}-dependent SVMPs, BPPs and C-NAP (Sanz et al., 2008). An isoform of the serine
516 protease has shown to possess procoagulant activity (Taherian et al., 2016). The venom also
517 contains an anti-coagulant Kunitz-type serine protease inhibitor (Sanz et al., 2008). Anti-
518 proliferative and cytotoxic effects of the venom have been observed *in vitro* (Amirian et al.,
519 2022; Malekara et al., 2020).

520 ***Montivipera wagneri***: Its venom is potently anticoagulant by inhibiting factor Xa (Chowdhury et
521 al., 2021) and has anti-cancer properties *in vitro* (Nalbantsoy et al., 2016).

522 ***Naja oxiana***: Its venom contains post-synaptic 3FTxs, such as a long neurotoxin (Nasiripour et
523 al., 2008; Samianifard et al., 2021; Talebzadeh-Farooji et al., 2004), cardiotoxins (Angaji et al.,
524 2016; Gasanov et al., 2015), and cytotoxins that can cause local tissue inflammation, necrosis,
525 hemolysis and inhibition of platelet aggregation (Derakhshani et al., 2020; Esmaili et al., 2021;
526 Gasanov et al., 2014; Gasanov et al., 2015). Coagulopathic properties of *N. oxiana* venom
527 (Mitel'man, 1966), have never been detected clinically. The venom also exhibits anti-plasmodial
528 (Hajialiani et al., 2020), anti-leishmanial (Fallahi et al., 2020; Sharifi et al., 2021), anti-bacterial

529 (Talebi Mehrdar, 2020; Talebi Mehrdar et al., 2017), anti-rabies (Farzad et al., 2020), and anti-
530 cancer activities (Barati & Davoudi, 2017; Derakhshani et al., 2020; Ebrahim et al., 2015;
531 Ebrahim et al., 2016; Javani Jouni et al., 2022; Sinaei et al., 2022).

532 ***Pseudocerastes fieldi:*** Its venom is unusual in lacking the metalloproteinase hemorrhagin,
533 procoagulant and LAO activities that are typical of most Viperidae, but it possesses CRiSPs, serine
534 proteases, Kunitz peptide, lectin, VEGF, and a heterodimeric PLA_2 complex with pre-synaptic
535 neurotoxic activity in experimental models (Ali et al., 2015; Bdolah, 1986; Francis et al., 1995;
536 Gitter et al., 1962; Op den Brouw et al., 2021a; Op den Brouw et al., 2021b; Tsai et al., 1983).
537 Some venom fractions can inhibit platelet aggregation, and have fibrinogenolytic and hemolytic
538 activities (Batzri-Izraeli & Bdolah, 1982; Mehdizadeh Kashani et al., 2012; Op den Brouw et al.,
539 2021b).

540 ***Pseudocerastes persicus*:** Its venom contains SVMPs, kallikrein and CRiSPs, acidic and basic PLA_2
541 enzymes, lectin toxins, VEGF, nerve growth factor (Ali et al., 2015; Op den Brouw et al., 2021b),
542 a natriuretic peptide (Amininasab et al., 2004; Elmi et al., 2006) and Kunitz-type proteins
543 (Banijamali et al., 2019; Op den Brouw et al., 2021b). Unlike *P. fieldi* venom, the venom of *P.*
544 *persicus* has prohemorrhagic and LAO activities (Bdolah, 1986). The venom also has
545 fibrinogenolytic, cytotoxic, antibacterial and anti-cancer effects (Ghezellou et al., 2021;
546 Nodooshan et al., 2021; Op den Brouw et al., 2021b; Shahbazi et al., 2019; Zargan et al., 2022).

547 ***Pseudocerastes urarachnoides:*** Its venom contains SVMPs, serine proteases, LAOs, PLA_2 and
548 lectin isoforms, and causes strong procoagulant, fibrinogenolytic and cytotoxic effects (Op den
549 Brouw et al., 2021a; Op den Brouw et al., 2021b). The procoagulant activity of the venom is
550 attributed to prothrombin and factor X activation (Op den Brouw et al., 2021a).

551 ***Vipera ammodytes transcaucasiana***: Its venom contains PLA_2s (including a potentially-
552 neurotoxic Vipoxin homologue), SVMPs, serine proteases, LAOs, CRiSPs, CTLs, VEGF, a disintegrin
553 and a phosphodiesterase (Hempel et al., 2018). The venom has shown anticoagulant (Chowdhury
554 et al., 2021), cytotoxic and anti-cancer activities (Celen et al., 2018).

555 ***Walterinnesia morgani*:** No studies of Iranian *W. morgani* venom have been published, but, the
556 composition of venom from a Turkish specimen has been characterized using mass
557 spectrometry (Calvete et al., 2021). It consists of 3FTxs, PLA_2s, CRiSPs, and Kunitz-type serine
558 proteinase inhibitor, with a low content of class PIII SVMPs, LAO, endonuclease,
559 phosphodiesterase, VEGF and acetylcholinesterase (Calvete et al., 2021). A procoagulant factor
560 X activator (probably a serine protease) has been identified in the venom of the closely-related
561 *W. aegyptia* (Khan & Al-Saleh, 2015).

562 **3.3. Snakebites in Iran**

563 ***3.3.1. Epidemiology***

564 According to available statistics released from the Iranian Ministry of Health (2002-2011)
565 (Dehghani et al., 2014a; Dehghani et al., 2014b), there are 5,000-7,000 snakebite
566 envenomings/year or 6.3-8.8/100,000 population/year, which falls within the very wide WHO
567 guesstimates of 210-11,079/year or 0.3-47.2/100,000/year in Iran (Kasturiratne et al., 2008).
568 Snakebite in Iran results in 3-12 snakebite deaths/year or 0.003-0.01 snakebite deaths/100,000
569 population/year, compared to WHO estimates of 6-13.2 snakebite deaths/year, or 0.01-
570 0.02/100,000/year (Dehghani et al., 2014a; Dehghani et al., 2014b; Kasturiratne et al., 2008;
571 Monzavi et al., 2014). These estimates for Iran are lower than worldwide estimated average
572 incidences of 25.7-40 snakebite envenomings/100,000 population/year; and 1.2-2 snakebite
573 deaths/100,000 population/year (Gutierrez et al., 2017), which is surprising considering the
574 country's extensive desert and rural areas, and possessing a rich and diverse venomous snake
575 fauna. A low mortality might be explained by the high priority accorded to snakebite as a
576 toxicological emergency and the access to toxicology trained physicians in the Iranian healthcare
577 system, together with the provision of antivenom, as part of an essential pharmaceutical
578 stockpile (IFDA, 2021), even in remote and less developed areas of the country. Urbanization may
579 have reduced the number of snakebite encounters (rural areas are inhabited by < 25% of total
580 population). However, under-reporting might be concealing the real magnitude of the snakebite
581 problem in Iran. In India, for example, a well-designed community-based survey revealed 25-fold
582 higher snakebite mortalities than a government figure based on returns from health facilities
583 (Suraweera et al., 2020). In Iran, the problem of under-reporting may be partly addressed by the
584 introduction of a standardized national minimum dataset registry for poisoning (Banaye
585 Yazdipour et al., 2020).

586 Hospital-based epidemiological studies have shown that only approximately 0.5-1% of acute
587 poisoning cases admitted to emergency departments of tertiary hospitals in Iran are due to
588 snakebites (Afshari et al., 2004; Alavi & Alavi, 2008; Rasouli et al., 2011; Shadnia et al., 2007).
589 Using species-distribution models and considering the habitat preferences of the 4 most common
590 medically-important venomous snakes, the northeast of Iran was predicted to have the highest
591 snakebite risk (Yousefi et al., 2020). However, most snakebites are reported from the middle and
592 southern provinces of Iran (Alavi & Alavi, 2008; Alinejad et al., 2017; Dehghani et al., 2014a;
593 Dehghani et al., 2014b; Hafezi et al., 2018; Jalali et al., 2012; Kassiri et al., 2019; Sagheb et al.,
594 2011b; Soleimani et al., 2021), partly because of their warmer climate (Ebrahimi et al., 2018),
595 which affords more favorable snake thermoregulation and that prolongs the snakes' active
596 seasons. In Iran, most snakebites occur during the warm months of the year, when outdoor
597 agricultural and leisure activities increase (Dehghani et al., 2022; Khosravani et al., 2018; Monzavi
598 et al., 2019b; Oghabian et al., 2022). More than 70% of snakebites occur in rural areas of Iran
599 (Dehghani et al., 2014b; Dehghani et al., 2014c; Dehghani et al., 2016c; Ebrahimi et al., 2018;
600 Eslamian et al., 2016; Monzavi et al., 2019b; Moradiasl et al., 2018; Nejadrahim et al., 2019), and,
601 as in other parts of the world, young adult men are most commonly affected (Dadpour et al.,

2012; Dehghani et al., 2014a; Dehghani et al., 2014b; Ebrahimi et al., 2018; Eslamian et al., 2016; Farzaneh et al., 2017; Khadem-Rezaiyan et al., 2018; Monzavi et al., 2019b; Nejadrahim et al., 2019; Oghabian et al., 2022; Soleimani et al., 2021). The economic burden caused by snakebite has been estimated to be less than 0.001% of the Iran's gross domestic product (Mashhadi et al., 2017; Patikorn et al., 2022).

3.3.2. Clinical features of snakebite

Many clinico-epidemiological studies of snakebite have been reported from Iran, nonetheless, in very few of them the species of snake responsible was reported. As a result, clinical envenoming syndromes attributed to Iranian snakes, have not been verified in most cases. One reason might be polyvalent antivenoms produced by Razi Vaccine and Serum Research Institute, and Padra Serum Alborz company, both covering the common local species of greatest medical importance and being available in tertiary referral hospitals throughout the country (Abouyannis et al., 2021; Dehghani et al., 2014a; Dehghani et al., 2014b; Monzavi et al., 2014), have made species diagnosis less important. Another reason is that the species of snake responsible is not among the essential data that should be recorded in the medical forms of snakebite patients in Iran. To identify the species of snake responsible, immunodiagnostic methods can be used, but only in Australia snake venom diagnostic/detection kits (SVDK/VDK) are commercially available for clinical use despite some problems in interpreting their results (Dhananjaya et al., 2015; Johnston et al., 2017). Elsewhere, confirmation of species identity relies on competent identification of the snake brought with the patient, or of photographs captured at the scene of the bite. Alternatively, its identity might be inferred from by observing the evolving clinical signs of envenoming, using a syndromic algorithm (Bawaskar & Bawaskar, 2019; Monzavi et al., 2014). However, for optimal medical management of an envenomed snakebite patient, it is important to know which species was responsible, so that likely complications can be anticipated, prevented or managed. There are, however, a few clinical reports from Iran based on expertly identified snakes (Dadpour et al., 2012; Hassanian-Moghaddam et al., 2022; Kazemi et al., 2021c; Kazemi et al., 2023b; Monzavi et al., 2019a; Monzavi et al., 2019b; Monzavi et al., 2015). This information has been augmented by published accounts of snake envenoming in other countries caused by the same species occurring in Iran (see below).

3.3.2.1. Dry bites

Bites by venomous snakes, with evidence that fangs have pierced the skin, do not always result in envenoming. An average of at least 20% of venomous snake strikes (globally and in Iran) fail to cause local or systemic envenoming (i.e., no systemic effects with no or very limited local effects), so called "dry bites" (Afshari & Monzavi, 2016b; Gold et al., 2002; Lavonas et al., 2011; Mehta & Sashindran, 2002; Monzavi et al., 2019b; Monzavi et al., 2015; Naik, 2017; Riley et al., 2011). The

638 highest rate of dry bites by venomous snakes, up to 80%, has been reported following some
639 Oceanian Elapidae and sea-snake strikes (Naik, 2017). Bites by mildly-venomous non-front-
640 fanged snakes, due to position of fangs and lack of a high-pressure venom delivery apparatus,
641 more often result in dry bites, as reported in studies from central and northeast Iran (Dehghani
642 et al., 2014c; Monzavi et al., 2019b). Only 1-20% of bites by colubrids result in envenoming
643 (Minton, 1990). Dry bites may be wrongly inferred, if victims failed to see the animal involved, or
644 mistook a non-venomous snake or snake-like animal, such as a legless lizard for a venomous
645 snake (Bazi et al., 2019), or suffered a painful penetrating injury from thorns, splinters, or other
646 sharp objects. Since there is usually a delay between the bite and appearance of signs and
647 symptoms of envenoming, "dry bites" should not be diagnosed too hastily. Following viper and
648 cobra bites, local pain and swelling usually appear within 1-2 hours, but systemic effects of viper
649 envenoming may be delayed for some hours. Bites by kraits and sea-snakes may not cause local
650 envenoming, and systemic envenoming may not become evident until 12 hours or more after
651 the bite (Gold et al., 2002; Monzavi et al., 2014; Riley et al., 2011). The initial absence of
652 symptoms in an apparently-well patient can be deceptive, persuading clinicians to discharge the
653 patient prematurely. A wise precaution is a statutory observation period of 24 hours for all
654 suspected snakebite patients.

655 ***3.3.2.2. Clinical effects of envenoming (Clinical syndromes)***

656 In the acute phase following a venomous snakebite, there are sets of clinical manifestations,
657 "envenoming syndromes", that may suggest a genus or species diagnosis (Ariaratnam et al., 2009;
658 Blaylock, 2014; Warrell, 2016). **Table 2** summarizes the common local and systemic effects of
659 snakebite envenoming in Iran. Most bites by venomous snakes and a few by mildly-venomous
660 non-front-fanged snakes cause local effects, while some elapids, particularly kraits and sea-
661 snakes, may cause minimal or no local effects during the early hours after the bite (Mehta &
662 Sashindran, 2002; Monzavi et al., 2014; Riley et al., 2011). Local and systemic effects and their
663 severity differ depending on the species responsible, the amount of venom injected, and its
664 depth of injection, and the composition of the venom (Lavonas et al., 2011; Monzavi et al., 2014;
665 Riley et al., 2011). Punctures made by paired fangs or teeth may be visible at the bite site,
666 suggesting snakebite, but bites by rodents, fish, large spiders, lizards or inanimate sharp objects
667 such as thorns and splinters, as well as incisions made intentionally at the bite site may cause
668 confusion (Bazi et al., 2019; Lavonas et al., 2011; Mehta & Sashindran, 2002; Monzavi et al., 2014;
669 Riley et al., 2011; Zamani et al., 2016).

670 Systemic effects of Viperidae envenoming often include shock and hemostatic disturbances,
671 while envenoming by Elapidae usually causes neurotoxic effects manifesting typically with
672 descending flaccid paralysis (Afshari & Monzavi, 2016b; Dadpour et al., 2012; Isbister et al., 2013;
673 Lavonas et al., 2011; Monzavi et al., 2014; Riley et al., 2011; Warrell, 2010; White, 2005), and in
674 the case of *Hydrophiini* envenoming, generalized rhabdomyolysis (Mehta & Sashindran, 2002;

675 Nabipour, 2012; Nabipour et al., 2015). However, these descriptions cannot be generalized to all
676 snakebite cases in all regions. For example, envenoming by Oceanian (or Australasian) elapids,
677 some North American rattlesnakes, or European *V. a. ammodytes,* may induce both hemostatic
678 disturbances and neurotoxic effects (Di Nicola et al., 2021; Farstad et al., 1997; Isbister et al., 2013;
679 Karabuva et al., 2016; Logonder et al., 2008; Massey et al., 2012; White, 2005). Moreover,
680 presumption of clinical effects following bites by a species based on its venom components may
681 not be sensible. As for example, venom of *P. fieldi* contains potentially neurotoxic components (Ali
682 et al., 2015), but there are no clinical reports of neurotoxic human envenoming by this species.

Table 2. Common clinical features of snakebite envenoming in Iran

Venom effects		Description	Plausible offending snake – (sub)Family
Local			
	Fang marks	Presence of one or two puncture marks suggests a bite by a venomous snake	Venomous snakes[*]
	Tooth marks[¶]	Numerous small shallow puncture wounds arranged in an arc	Non-venomous and mildly venomous snakes
	Pain[†]	Burning, bursting or throbbing pain localized to the bite site and sometimes radiating up the limb	Venomous snakes especially Viperidae, mildly venomous snakes
	Local lymphadenopathy/ lymphadenitis[†]	Painful, tender swelling of local lymph nodes draining the bite site	Venomous snakes
	Local swelling[†]	Swelling around the bite site that may extend rapidly and involve the entire limb and/or areas of adjoining trunk	Venomous snakes especially Viperidae
	Local cutaneous damage[†]	Erythema, local ecchymosis, blister/bulla formation and sometimes local necrosis may appear over hours to few days following the bite	Venomous snakes especially Viperidae
	Local myonecrosis	Necrosis of local muscles adjacent to the bite site	Venomous snakes
	Compartment syndrome	It is a potential, but in practice very rare, manifestation in envenomed tissue that is contained in a tight fascial compartment including the pulp space of digits, anterior forearm or anterior tibia	Viperidae
Systemic			
	Parasympathetic excitation	Uncontrollable vomiting, fasciculations, congested conjunctivae, gooseflesh, sweating, sialorrhea, lacrimation, respiratory tract secretions, cramping abdominal pain, diarrhea	Venomous snakes (especially Elapidae)
	Neurotoxic effects[#]	Descending flaccid paralysis (starting with bilateral ptosis and external ophthalmoplegia with diplopia and blurred vision), bulbar palsy, respiratory paralysis (paralysis of intercostal muscles and diaphragm), fasciculations, limb paralysis	Elapidae
	Myotoxic effects[§]	Myalgia, myopathy, marked increase in serum creatine kinase, muscle stiffness, necrosis of muscle fibers, systemic rhabdomyolysis (occasionally), cardiac dysrhythmia, abnormal echocardiogram, trismus, myoglobinuria, generalized trunk pain	Elapidae (particularly sea-snakes)
	Vasculotoxic and hemotoxic effects[#]	Spontaneous bleeding, thrombocytopenia, coagulopathy (consumption coagulopathy), microangiopathic hemolysis/thrombotic microangiopathy (schistocytes), local or spontaneous systemic hemorrhage, diffuse cutaneous ecchymosis,	Viperidae

		gingival bleeding, epistaxis, hematemesis, melaena/blood in feces, hemoptysis, intracranial hemorrhage, hematuria, uterine bleeding	
	Shock	Severe hypotension, hypovolemia, myocardial depression and elevated levels of troponins	Venomous snakes
	* Bites by mildly venomous snakes (e.g., Iranian colubrids) may also produce fang marks. ¶ Some elapid bites may produce this pattern. † Bites by elapids, especially kraits and sea-snakes, may be painless and without swelling or other local effects. Bites by mildly venomous snakes may produce erythema, blister formation, lymphadenopathy and limited local swelling without (or with limited) progression. §Although rare, in bites by some vipers may also be seen. # Bites by mildly venomous snakes very rarely may also produce neurotoxic effects and limited bleeding from the bite site.		

683 ***3.3.2.3. Species-specific descriptions of snakebite envenoming***

684 Species-specific descriptions of envenoming following bites by the medically important snakes of
685 Iran provided in this section are based on reports of cases, in which the snake responsible for the
686 bite was competently identified using the methods described above, either in Iran, in neighboring
687 countries or other countries inhabited by the species same as those occurring in Iran:

688 **Colubridae and Lamprophiidae:** Although the venoms of some colubrid and lamprophiid species
689 contain toxic components similar to those of vipers and elapids, bites by these non-front-fanged
690 species usually do not result in envenoming in humans. Reports of lethargy and respiratory
691 difficulty following these bites are unlikely to be neurotoxic in origin. In general, the bites of
692 opisthoglyphous species rarely cause systemic effects; and local effects such as swelling, pain,
693 blister formation, erythema/ecchymosis and bleeding from fang punctures are the most common
694 clinical features (Araujo et al., 2018; Dehghani et al., 2014c; Dehghani et al., 2012; Weinstein et
695 al., 2014). Systemic effects include cranial nerve palsy, coagulopathy and thrombocytopenia
696 (Brandehoff et al., 2019; Kuch & Mebs, 2002; Pommier & de Haro, 2007; Weinstein et al., 2023a).

697 Bites by *Boiga trigonata melanocephala* have not been reported, but in Sri Lanka, bites by the
698 closely-related *B. t. trigonata* caused no systemic nor significant local envenoming (Ariaratnam
699 et al., 2009). A case bitten by a large male *Hemorrhois ravergieri* developed rapidly progressive
700 swelling, that spread from bitten fingers to involve the whole hand, 10-15 minutes after the
701 bite. There was also dizziness, and pain in axillary lymph nodes. Symptoms persisted for 3 days
702 (Darevsky, 1969). Mamonov reviewed Darevsky's case and another case reported by Ishunin
703 (Ishunin, 1950), in which there was profuse bleeding of the bite wound, pain, swelling and
704 bluish and reddish discoloration of the hand, which began to resolve 30 hours later, but it took
705 10 days to recover completely; and also reported a similar case of his own (Mamonov, 1977).
706 Pain, transient bleeding and edema quickly spreading from the bite site to affect entire limb
707 (10-15 min after bite) were also reported by Kazemi et al. in three cases of bites by *H. ravergieri*
708 and *H. nummifer* in central and western Iran (Kazemi et al., 2023a). Kocourek reported pain and
709 local swelling in the arm (Kocourek, 1990), and Schweiger reported burning sensation, severe

local swelling in the hand, and severe bleeding from puncture marks after bites by *H. ravergieri* (Schweiger, 1991), the symptoms of both cases resolved a day later. A bite by *H. nummifer* produced similar symptoms (Weinstein et al., 2023b). Branch reported only mild symptoms from a bite by *P. rhodorachis* from Saudi Arabia (Branch, 1982), less severe than those of a bite by this species in Israel, which caused immediate erythema, lymphangitis, swelling and numbness of the bitten hand, and generalized irritation (Perry, 1988). In southern Saudi Arabia, Malik described five confirmed bites by *P. rhodorachis*, all of which produced local pain and tenderness, with local swelling and redness in three, elevated serum creatine kinase in two, and blistering with lymphadenitis, and leukocytosis in one (Malik, 1995). An anecdotal report of "moderate systemic paralysis of the skeletal muscles and breathing difficulty following *P. rhodorachis* bite, which resolved spontaneously after 7 hours" (Fry et al., 2003), is discounted as being medically unsubstantiated. Multiple bites by a presumed *P. najadum* in Greece, initially caused local swelling, diffuse myalgia, and axial muscle stiffness, which progressed to areflexic quadriplegia 3 months after the bite. The patient died from a progressive segmental neuropathy about 6 months after the incident (Chroni et al., 2005). The authors suggested that auto-immune damage to neural antigens provoked by *P. najadum* venom toxins might have been responsible, but causation was not confirmed (Weinstein et al., 2023a). In Nakhchivan Autonomous Republic, Azerbaijan, a 35-year-old farmer was bitten on his index finger by a *Telescopus fallax iberus*, and shortly afterwards, developed hypotension, a hemorrhagic blister on the bitten finger, and pain and swelling extending to the dorsum of the hand. These symptoms resolved after 3 days (Sultanov, 1966). No bites by *T. rhinopoma, T. nigriceps,* or *T. tessellatus* have been reported so far.

A bite by Moila's Snake (*Malpolon moilensis*) caused only local swelling and numbness of the bitten digit (Perry, 1988), while bites by the Eastern Montpellier Snake (*M. insignitus*) are said to have caused only local symptoms such as swelling, paresthesia, stiffness of the affected limb and lymphangitis, which resolved within 48 hours (Jimenez-Cazalla, 2012). Similarly, a bite by *M. insignitus* was reported from central Iran causing only mild local symptoms (Dehghani et al., 2014c). In France, a bite by the closely-related Montpellier Snake (*Malpolon monspessulanus*) caused self-limiting local effects, but some hours later, the patient developed blurred vision, nystagmus, partial oculomotor paralysis with ptosis and complete paralysis of accommodation. These neurological symptoms took 6 days to resolve completely (Pommier & de Haro, 2007). Among 60 reported cases of *M. monspessulanus* bites in Spain, most (50 cases, 83%) were asymptomatic, while nine had local envenoming, and only one developed neurologic symptoms (ptosis, dysphagia, mild dyspnea, difficulty in speaking and loss of reflexes and paresthesia in the bitten limb) in addition to severe swelling. Laboratory tests were normal (Gonzales, 1978). A bite by the Schokari Sand Racer, *Psammophis schokari*, was reported from central Iran (Dehghani et al., 2014c), with only local erythema. In Oman, a bite by *P. schokari* caused mild local swelling, erythema, and pruritus of the bitten finger followed by protracted morbidity (Ineich et al., 2020).

A review of other *Psammophis* bites suggested nothing more than mechanical injury by teeth and fangs (Ineich et al., 2020). No bites by *P. lineolatus* have been reported so far.

***Bungarus persicus*:** No bite by the Persian krait (*Bungarus persicus*) has yet been reported. However, in the northern region of Sarbaz, in Iran's Sistan and Baluchistan province, where this species was discovered, it is well known locally under the name "Siah Mar" (black snake) and it is greatly feared (Abtin et al., 2014). There can be no doubt about the potential danger of envenoming. Features typical of bites by other *Bungarus* species, such as the closely-related Sindh krait (*B. sindanus*) and common krait (*B. caeruleus*), include the risk of painless nocturnal bites inflicted on people sleeping on the ground, minimal or absent symptoms of local envenoming, and evolution of abdominal pain, myalgia, autonomic disturbances and descending paralysis, sometimes after a delay of several hours (Kularatne, 2002; Pillai et al., 2012; Theakston et al., 1990).

Cerastes gasperettii: While there is no report from Iran, a bite by a *Cerastes* in Qatar caused progressive local swelling, consumptive coagulopathy, and cardiotoxic effects (right bundle branch block, bradycardia, chest pain, electrocardiographic ST segment abnormalities, with cardiac troponin elevation) (Razok et al., 2020). However, the authors' attribution to *C. cerastes* (Razok et al., 2020), is impossible on geographical grounds and the snake must have been *C. gasperettii*. In two patients bitten by imported specimens of the closely-related *C. cerastes* in Europe, there were extensive swelling and life-threatening systemic envenoming, characterized by systemic hemorrhage, coagulopathy, increased fibrinolysis, thrombocytopenia, micro-angiopathic hemolytic anemia and acute kidney injury (AKI) (Schneemann et al., 2004).

***Echis carinatus sochureki*:** In a series of confirmed cases of bites by this species in northeast Iran, extensive local edema (55.6%), ecchymoses (48.1%), elevated serum creatine kinase (44.4%), coagulopathy (40.7%), thrombocytopenia (33.3%), lymphadenopathy (29.6%), nausea/vomiting (25.9%), blister formation (11.1%), and local necrosis (25.9%) were documented (Monzavi et al., 2019b). There have also been reports of local and systemic bleeding (epistaxis and gingival bleeding) (Monzavi et al., 2019a; Monzavi et al., 2019b) (**Fig. 5**). AKI has been reported in a case in southern Iran (Sagheb et al., 2011a). *E. c. sochureki* venom contains procoagulants, platelet-activating toxins, and hemorrhagins that are responsible for consumption coagulopathy, thrombocytopenia, vascular endothelial damage and microangiopathic hemolysis leading to local and occasionally serious systemic bleeding (Afshari & Monzavi, 2016b; Babaie et al., 2013a; Balali-Mood & Shariat, 1999; Monzavi et al., 2019b; Salmanizadeh et al., 2013; Warrell, 1995; Warrell, 2016). Outside Iran, among 117 proven cases of *E. c. sochureki* envenoming in Jammu, Northern India, all developed coagulopathy, 68% had evident bleeding and the rest had defective coagulation (Bhat, 1974). Hemorrhages were in the form of local bleeding from the bite wound, hematuria, hemoptysis, gingival bleeding, hematemesis, epistaxis, rectal and subarachnoid hemorrhage. Other symptoms included fever, vomiting, upper abdominal pain, leukocytosis,

785 blisters, regional lymphadenitis and shock (Bhat, 1974). In another report from the Thar Desert
786 region of Rajasthan, India, all the victims developed coagulopathy, the majority had local swelling
787 (92%), and vomiting (92%), two-thirds had local or systemic bleeding (i.e., from bite site,
788 hematuria, hemoptysis, gingival bleeding, hematemesis, melena and intracranial hemorrhage),
789 25% developed local blistering, and 16.7% necrosis (Kochar et al., 2007). Mortality rates in *E. c.*
790 *sochureki* victims treated with antivenom have been very low (Bhat, 1974; Kochar et al., 2007;
791 Monzavi et al., 2019b), but in untreated cases, fatalities are common and may be delayed for
792 several days after the bite (Bhat, 1974; Minton, 1966).

793 ***Eristicophis macmahonii***: There has been no report of bites in Iran. Five cases were described
794 from Baluchistan in Pakistan (Shaw, 1925). Two died several hours after the bite, having
795 developed local swelling, abdominal pain and distension. One of them was weak and feverish,
796 and complained of thirst, but was unable to swallow. She would not raise her eyelids, suggesting
797 the possibility of neurotoxicity. The other victim developed marked local swelling, signs of
798 bleeding, and died after becoming comatose. In two other cases, there was extensive local
799 swelling which persisted for 3 days. Local ulceration developed in one of them (Shaw, 1925). In
800 another report from western Asia, the life of a patient was seriously endangered after an
801 *Eristicophis* bite in spite of treatment with antivenom (Mertens, 1965). In Belgium, a man
802 previously envenomed by four other species, was bitten on one finger by his pet *E. macmahonii,*
803 rapidly become nauseated, developed a rash, collapsed, and become transiently unconscious
804 (Van den Enden & Bottieau, 2005). The affected limb became tender and swollen, with axillary
805 lymphadenopathy and an ecchymosis. He felt weak and breathless with a dry mouth and bilateral
806 eyelid swelling (angioedema). His symptoms resolved with corticosteroids and antihistamines
807 suggesting anaphylaxis caused by hypersensitization by his previous envenomings. Laboratory
808 investigations, including tests of blood coagulation, were normal and the only features directly
809 attributable to envenoming were the local effects (Van den Enden & Bottieau, 2005). Two bites
810 by pet *E. macmahonii* in Switzerland caused local swelling, and in one, minimal coagulopathy
811 (Fuchs et al., 2022).

812 ***Gloydius caucasicus*:** Envenoming can cause local swelling and necrosis (Latifi, 1991, 1985). Since
813 the venom contains a procoagulant serine protease and anticoagulant factor (Ghorbanpur et al.,
814 2010; Ghorbanpur et al., 2009), bleeding and coagulopathy are to be expected. In Ýolöten in
815 south-eastern Turkmenistan, a 5-year-old boy bitten by *G. caucasicus* bled from the bite wound
816 on the foot. Swelling spread up to the shin, while severe anemia (2.9 x 10^6 red blood cells/mm^3)
817 and lymphocytosis emerged. He recovered and was discharged after 8 days of hospitalization
818 despite highly irregular treatment with wound incision, application of a tourniquet and local
819 novocain infiltration (Tushiev, 1963). In Germany, a snake-keeper who was bitten by a closely-
820 related species, *Gloydius halys*, developed incoagulable blood, afibrinogenaemia, elevated
821 plasma fibrin(ogen) degradation products, thrombocytopenia and mildly reduced plasminogen

822 concentrations within two hours after the bite. At the bite site, he developed serosanguineous
823 blisters and necrosis requiring debridement. Hemorrhagic signs included oral mucosal bleeding
824 and frank hematuria. He was given two doses of antivenom 9 and 16 hours after the bite. Blood
825 clotting returned to normal within 48 hours (Meissner et al., 1989).

826 ***Hydrophis spp.:*** No sea-snake bites have been reported from Iran or other Middle-Eastern
827 countries, but symptoms produced by the same species that occur in Iranian waters have been
828 described from other regions (Warrell, 2016; Warrell, 1994). Bites are usually painless with
829 minimal or no local swelling. Early systemic symptoms include headache, a thick feeling of the
830 tongue, thirst, sweating, and vomiting followed by neurotoxicity and generalized rhabdomyolysis
831 in cases of envenoming by many species (Mehta & Sashindran, 2002; Nabipour, 2012; Warrell,
832 2016; Warrell, 1994). Myotoxic symptoms include generalized muscle aching, stiffness, and
833 tenderness that becomes noticeable 30 minutes to over 3 hours after the bite. Trismus is
834 common, and passive stretching of the muscles is painful. Later, there is progressive flaccid
835 paralysis starting with ptosis, as in other neurotoxic envenomings. The patient remains conscious
836 until respiratory muscle paralysis results in respiratory failure. Myoglobinemia and myoglobinuria
837 become evident 3-8 hours after the bite. Myoglobin and potassium released from damaged
838 skeletal muscles may cause AKI, whereas hyperkalemia developing within 6 to 12 hours of the
839 bite may precipitate diastolic cardiac arrest (Nabipour, 2012; Reid, 1961; Sitprija, 2006; Warrell,
840 2016; Warrell, 1994).

841 ***Macrovipera lebetina:*** Local pain and swelling, thirst, nausea, vomiting and sometimes
842 diarrhea, are early symptoms of envenoming. Swelling may extend to involve the whole bitten
843 limb, and trunk, with bruising, lymphangitic markings, regional lymphadenitis, and
844 serosanguinous blistering that preceded necrosis (Balali-Mood & Shariat, 1999; Dadpour et al.,
845 2012; Kazemi et al., 2021c; Monzavi et al., 2019b) (**Fig. 6**). Latifi illustrated extensive swelling,
846 ecchymoses, and digital necrosis with residual deformity in two victims of bites by this species
847 (Latifi, 1991, 1985). Consumption coagulopathy and thrombotic microangiopathy may develop
848 in cases of more severe envenoming, making the victims susceptible to spontaneous local and
849 systemic bleeding from mucous membranes, subconjunctival and retinal hemorrhages, and
850 melena or blood in the feces (Dadpour et al., 2012; Monzavi et al., 2019a; Monzavi et al.,
851 2019b). Anemia is associated with hemolysis and thrombocytopenia (Monzavi et al., 2019b),
852 consistent with microangiopathic hemolysis, and there is neutrophilic leukocytosis. Delayed
853 severe thrombocytopenia, poorly responsive to antivenom, may also occur (Abukamar et al.,
854 2022). Body temperature may be elevated even in the absence of infection and large increases
855 in serum creatine kinase levels (>1000 IU/L) suggest rhabdomyolysis (Monzavi et al., 2019b).
856 AKI and oliguria may develop but this does not appear to be common. In cases of *M. lebetina*
857 envenoming reported from Azerbaijan, Cyprus, Israel, India, Iraq and Jordan; trembling, rigors,
858 dizziness, reduced consciousness, subarachnoid hemorrhage, massive ecchymoses,

859 hemodynamic instability progressing to shock with tachycardia and cold sweats were also
860 noted (Abu Baker et al., 2022; Amr et al., 2020; Sultanov, 1983). The largest published
861 experience of *M. l. obtusa* bites (1,122 cases between 2009 and 2020) is from Azerbaijan
862 (Efendiev, 2021). This species is known locally as "gyurza". In this report, the diagnosis was
863 based on the clinical picture of envenoming and detection of venom in patients' blood by
864 spectrofluorimetry. Severe cases had local swelling and bruising, involving the entire bitten limb
865 and beyond, especially when a tourniquet had been applied. Case-fatality was 1.9%,
866 attributable to septicemia, consumption coagulopathy, shock, hepatic and renal toxicity, and
867 hemolytic anemia. Various antivenoms were used, including Sanofi-Pasteur (probably
868 "Favirept", now discontinued) that proved the safest and most effective, polyvalent
869 "Antigyurza, antiefa, anticobra" produced in Uzbekistan that caused many adverse reactions,
870 and "Antigadyuka" from a Russian manufacturer that was wholly ineffective (Efendiev, 2021).
871 The only report of *M. l. cernovi* envenoming is from Ýolöten in south-eastern Turkmenistan
872 (Tushiev, 1963). A 33-year-old male snake catcher was admitted 3 days after the bite with
873 severe weakness, persistent vomiting, severe radiating pain, swelling and bruising in the bitten
874 limb, thirst, chest tightness, shortness of breath, weak pulse, fever (39°C) and leukocytosis
875 (13,100 white blood cells/µl). He was treated with two doses of "antigyurza" antivenom, began
876 to improve after the fifth day, and was discharged on the 15th day (Tushiev, 1963).

877 ***Montivipera latifii*:** Bites are rare, as this snake is mainly restricted to a highly-protected
878 national park in Iran. In the only report of a confirmed case of *M. latifii* envenoming, a teen-age
879 girl who was bitten on her face, rapidly developed swelling of the head, neck and oropharynx
880 (Hassanian-Moghaddam et al., 2022). Antivenom therapy was delayed, due to a misleading
881 history of hymenoptera sting from the parents, and thus she developed acute upper airway
882 obstruction, respiratory distress, hypoxia, loss of consciousness and cerebral edema. There was
883 an extensive local ecchymosis, but no evidence of coagulopathy. She died several days later
884 from complications of hypoxic brain damage and nosocomial septicemia secondary to hospital-
885 acquired pneumonia (Hassanian-Moghaddam et al., 2022).

886 ***Montivipera raddei*:** Serious local effects and hemostatic disturbances are expected following
887 envenoming by this species (Darevsky, 1966; Ettling et al., 2012; Nejadrahim et al., 2019). Latifi
888 illustrates extensive blistering after a bite by this species (Latifi, 1991, 1985). In Armenia, during
889 1951-3, there were human fatalities, including two 14-year-old children bitten on their legs, and
890 an adult man bitten on the shoulder who died within 12 hours of the bite (Darevsky, 1966). Also
891 in Armenia, a 51-year-old man who was bitten on a finger and thumb developed intense
892 burning and throbbing pain that radiated up the arm to his shoulder, dizziness, profuse
893 sweating and blistering (Ettling et al., 2012). After admission, the patient was treated
894 conservatively with a variety of unconventional medications, but no antivenom was given. At 24
895 hours, there was swelling and ecchymoses of the right side of his body, which increased,

together with myalgia, arthralgia and severe local pain. The patient survived despite lack of antivenom therapy. His pain persisted for several weeks, and at 6th week, necrotic tissue was debrided from the thumb (Ettling et al., 2012).

Naja oxiana: Despite this species' wide distribution in Asia, there are very few reliable published reports about envenoming. According to Latifi (Latifi, 1991, 1985), weakness, drowsiness, and paralysis of the throat, usually develop within one hour and progress rapidly to respiratory distress and possible cardiac arrest. He considered that these symptoms might be delayed for up to 10 hours by applying a tourniquet (this first-aid method currently is not recommended). Local pain and swelling are said to be uncommon and mild, although local blistering and superficial necrosis are described after bites by other Asian cobras (Afshari & Monzavi, 2016a; Warrell, 2016). Neurotoxic envenoming usually starts with bilateral ptosis and external ophthalmoplegia and descends involving muscles innervated by the cranial then thoracic nerves eventually causing life-threatening bulbar and respiratory muscle paralysis. In northeast Iran, a 4-year-old child died after developing respiratory muscle paralysis and cyanosis, 30 minutes after being bitten by a *N. oxiana* (Balali-Mood & Shariat, 1999). Also in Iran (same region), a 39-year-old man bitten on the finger by *N. oxiana* presented with bilateral ptosis, mydriasis, sluggish pupillary light reflex and sialorrhea 30 minutes after the bite. After an hour, he developed difficulty in breathing from respiratory muscle paralysis, requiring intubation and mechanical ventilation. The patient was treated with an initial dose of 100 mL of Razi antivenom (hexavalent), followed by three 50 mL doses at 6-hour intervals. He was extubated 48 hours later (Rajabi et al., 2022). In Russia, a 28-year-old snake-keeper, bitten on his index finger by a captive *N. oxiana* from Turkmenistan, 147 cm in total length, developed increasing weakness in his legs 15 minutes later, a feeling of constriction in the throat, difficulty breathing, and hypotension with frequent extrasystoles (Kudriavtsev, 1983). After 20-25 minutes, there was complete paralysis of the lower extremities, respiratory arrest and coma. However, intravenous and local subcutaneous injection of "anticobra" antivenom resulted in rapid restoration of respiration and consciousness. He also suffered persisting periods of hypotension, multiple extrasystoles, vomiting and chills and showed marked mydriasis. There was swelling of the entire bitten arm with local tissue necrosis at the bite site. He recovered gradually over 5 days (Kudriavtsev, 1983). Barkagan described two patients bitten by *N. oxiana* in Tajikistan, who suffered progressive paralysis involving respiratory muscles and also dysphagia, loss of tendon reflexes, disturbances of superficial and deep sensitivity, dysarthria, aphonia and other disturbances of speech (Barkagan, 1964). In Turkmenistan, *N. oxiana* bite victims experienced local slight burning sensation, redness and swelling, followed after 30 minutes by "irresistible drowsiness", impairment of consciousness and lower limb weakness (Talyzin, 1963). Hypersalivation, paralysis of the tongue and larynx, generalized paralysis and respiratory failure may develop, leading to death in 2-7 h after the bite in untreated cases (Talyzin, 1963).

934 ***Pseudocerastes fieldi***: Although the venom of this species is neurotoxic in small mammals, the
935 very few human bite victims documented in Middle Eastern countries developed only local
936 symptoms and all survived (Amr et al., 2020; Kochva, 1990).

937 ***Pseudocerastes persicus***: The most common clinical manifestations of envenoming are localized
938 pain and swelling, associated with local tissue necrosis. Passing through the superficial lymphatic
939 vessels, the venom causes lymphangitis, swelling, ulceration, and superficial thromboses that
940 slowly spread (Afshari & Monzavi, 2016b; Balali-Mood & Shariat, 1999). Consistent with the
941 known venom composition of *P. persicus* (Mehdizadeh Kashani et al., 2012), consumption
942 coagulopathy and thrombocytopenia have been reported following envenoming (Afshari &
943 Monzavi, 2016b; Balali-Mood & Shariat, 1999; Heiner et al., 2013). A herpetologist bitten by an
944 identified *P. persicus* in Kerman Province, Iran, developed local pain and swelling, bleeding from
945 the bite site, mild non-specific symptoms, increased serum creatine kinase and minimal
946 laboratory evidence of coagulopathy (Kazemi et al., 2023). Four days after a reported bite by this
947 species in Pakistan, a young Makrani boy appeared very weak and jaundiced but seemed to be
948 recovering (Minton, 1966).

949 ***Vipera ammodytes transcaucasiana***: There have been no reports of bites by *V. a.*
950 *transcaucasiana*. However, vomiting, diarrhea, thrombocytopenia, AKI, hypokalemia,
951 proteinuria, elevated liver enzymes, hemolytic anemia, petechiae, hematoma, hematuria,
952 thrombocytopenia, severe coagulopathy, and rarely neurotoxic symptoms (expressed as
953 transient paresis of the bitten limb) have been reported from bites by the closely-related *V. a.*
954 *ammodytes* (Liapis et al., 2019; Marinov et al., 2010; Nikolić et al., 2021).

955 ***Walterinnesia morgani:*** In Iraq, close to the western border of Iran, a man bitten on his leg by a
956 "large black snake", assumed to be *W. morgani*, was reported to have developed respiratory
957 distress and generalized limb weakness along with mild edema, erythema, and numbness around
958 the bite site. During recovery, he experienced diplopia without objective evidence of external
959 ophthalmoplegia but made a complete recovery (Lauer et al., 2011). Also in Iraq, Corkill described
960 three fatalities within 6-10 h of suspected bites by this species (Corkill, 1939, 1932). Clinical
961 features included local swelling, vomiting, collapse and paralysis (Corkill, 1939, 1932).
962 Envenoming by the closely-related Egyptian or Western Black Desert Cobra (*W. aegyptia*) has
963 been reported to cause local pain and swelling, fever, nausea, vomiting, diaphoresis, generalized
964 weakness, involuntary movements, respiratory distress, loss of consciousness, and peripheral
965 neutrophilic leukocytosis (Abu Baker et al., 2022; Lifshitz et al., 2003; Yayon et al., 1988).

966 ***3.3.3. Secondary complications of snakebite envenoming***

967 The etiology of the often poly-microbial wound infections and cellulitis in snake-bitten patients
968 reflects the varied, unusual, and distinctive bacterial flora of snakes' oral cavities (Dehghani et
969 al., 2020; Dehghani et al., 2016b; Sadeghi et al., 2021). However, many snake venoms possess

anti-bacterial activity. In a Brazilian study, bacterial contamination was very uncommon in venom of recently-captured snakes (Garcia-Lima & Laure, 1987). Another source of secondary bacterial or, rarely, fungal infection following snakebite is the use of non-sterile incisions at the bite site (Afshari & Monzavi, 2016b; Dehghani, 2010; Dehghani et al., 2016b; Dehghani et al., 2015).

Many of the systemic manifestations of envenoming arise from direct venom toxicity, but they may sometimes result indirectly through other mechanisms. For example, AKI may be caused by direct nephrotoxicity of snake venom, or it may result from profound or prolonged hypotension due to massive hemorrhage, hypovolemia, anaphylaxis or vasoactive venom toxins, or from "pigment nephropathy" in cases of rhabdomyolysis or hemolysis (Sitprija, 2006). Renal damage is usually transient and responsive to short-term hemodialysis without the complication of chronic renal failure (Elkabbaj et al., 2012; Rahmani et al., 2022; Valenta et al., 2010). In Iran, complications, such as pancreatitis, subarachnoid hemorrhage, compartment syndrome, ischemic contracture, and digital necrosis requiring amputation, have also been reported following snakebite envenoming (Dehghani et al., 2014b; Eslamian et al., 2016; Farzan et al., 2003; Nejadrahim et al., 2019; Sagheb et al., 2011a, 2011b; Zamani et al., 2016). In a rare case of envenoming by *E. c. sochureki* in southern Iran, the victim developed AKI and necrotizing pancreatitis (Sagheb et al., 2011a). AKI and pancreatitis, and posterior reversible encephalopathy syndrome, have also been reported following *C. cerastes* envenoming (Ibrahim et al., 2017; Valenta et al., 2010).

In addition to organic symptoms, snakebite victims may experience psychiatric symptoms and mental health problems such as visual hallucinations, and acute and chronic post-traumatic stress disorders (Khosrojerdi & Amini, 2013; Mehrpour et al., 2018).

3.4. Medical management of snakebite envenoming in Iran

Snakebite envenoming is a medical emergency. If intervention is delayed, irreversible sequelae and even death may ensue (Hassanian-Moghaddam et al., 2022; Monzavi et al., 2014). In fact, traditional therapeutic measures in rural areas, misleading self-reported history by the victims or relatives, and inadequate inspection of the bite wound and initial misdiagnosis by the clinicians, are the major contributory factors that delay appropriate medical interventions. In rural areas of Iran, traditional treatments include aggressive wound incision/pricks, suction, tight tourniquets above the bite site, and local application of various herbal medicines (e.g., mullein, dandelion, onion, turmeric, etc.) (Afshari & Monzavi, 2016b; Astaraki et al., 2020; Balali-Mood & Shariat, 1999; Besharat et al., 2008).

The most effective and the only specific treatment to prevent, halt and reverse venom effects is specific antivenom (Gutierrez, 2018; Warrell, 2016). *E. c. sochureki*, *M. lebetina*, *M. raddei*, *G. caucasicus*, *P. persicus* and *N. oxiana* have long been considered the species of greatest medical

importance in Iran (Afshari & Monzavi, 2016b; Balali-Mood & Shariat, 1999; Latifi, 1985). That is why Iranian antivenoms were designed specifically to target the venoms of these species. Razi™ Polyvalent Antivenin (Razi Vaccine & Serum Research Institute, Tehran, Iran) has been commercially available for over five decades (Latifi, 1984). The antivenom is an equine-derived $F(ab')_2$ immunoglobulin, that is produced in two formulations: (1) pentavalent, capable of neutralizing the venom of 5 common medically important snakes in Iran including *E. carinatus*, *M. lebetina*, *M. raddei (albicornuta)*, *G. caucasicus (halys)* and *P. persicus*, and (2) hexavalent, with the addition of neutralizing *N. oxiana* venom (Latifi, 1984; Monzavi et al., 2019a; Monzavi et al., 2014; Theakston & Warrell, 1991). The hexavalent formulation is distributed only in northeastern regions of Iran, where *N. oxiana* is reported. The effectiveness of this antivenom has been predicted, based on both *in vitro* and *in vivo* studies, but no formal clinical trial has been carried out (Akbari et al., 2010; Heiner et al., 2013; Latifi, 1984; Monzavi et al., 2019a). For this antivenom, the average time needed to achieve a “therapeutic response” or “initial control" (judged by the reversal of systemic effects, or arrest of progression of local effects when there are no systemic effects) was approximately 2 (range 1-9) hours in viper envenomed victims in northeastern Iran after treatment with a median of 10 ampoules (100 mL, two doses of 50 ml/hour) (Monzavi et al., 2019b). In southern parts of the country, higher doses (10-20 ampoules) are usually administered (Rahmani et al., 2014), because different criteria for clinical response are considered (their criteria generally differ from the consensus definition of initial control according to widely-accepted guidelines and textbooks) (Lavonas et al., 2011; Monzavi et al., 2014; Riley et al., 2011; Warrell, 2016). The frequency and severity of early adverse reactions following treatment with this antivenom are reported to be low (4.5-6%) with few or no late reactions, but detection of all adverse events requires close monitoring of patients for at least 4 hours after antivenom treatment and follow-up for the next 4 weeks (Mohammad Alizadeh et al., 2016; Monzavi et al., 2019a; Monzavi et al., 2015). Recently, a new Iranian company (Padra Serum Alborz, Karaj, Iran) has started manufacturing snake antivenoms, i.e., SnaFab5® (pentavalent) and SnaFab6® (hexavalent), to expand antivenom production capacity and availability for Iran and neighboring countries (Abouyannis et al., 2021; Kazemi et al., 2023b). Both brands (Razi™ and SnaFab®) have been listed in the WHO database of antivenoms (World Health Organization, 2021), and share similar composition and formulation. However, to separate IgG, ammonium sulfate is used for Razi™, whereas caprylic acid is employed for SnaFab® production. Razi institute plans to produce a monovalent antivenom for *N. oxiana* (Akbari et al., 2010). In Iran, other suggested innovations have included raising antivenoms in chicken egg yolks (Zolfagharian & Dounighi, 2015), and development of recombinant antibodies against Iranian venomous snakes using phage-display technology (Eskafi et al., 2021; Kadkhodazadeh et al., 2020; Nazari et al., 2020), and species-specific human recombinant Fab antivenom (Kazemi-Lomedasht et al., 2019; Motedayen et al., 2018). Novel drug delivery methods to enhance antivenom efficacy have also been explored (Alirahimi et al., 2018; Shahidi Bonjar, 2014).

1044 Venom-induced hemostatic disorders and shock are usually reversible with prompt and
1045 appropriate antivenom therapy. However, death due to envenoming may occur in the first few
1046 hours after elapid bites, due to neurotoxic bulbar and/or respiratory paralysis (Angaji et al., 2016;
1047 Gasanov et al., 2015; Lewis & Gutmann, 2004). Post-synaptic neurotoxicity following cobra
1048 envenoming is fairly responsive to antivenom therapy; whereas, presynaptic neurotoxicity of sea-
1049 snakes and kraits is poorly reversible, once established, since the PLA_2 neurotoxins permanently
1050 damage targeted nerve terminals at neuromuscular junctions (NMJ)s. Hence, in all cases of
1051 neurotoxic envenoming, airway management and assisted ventilation should be considered to
1052 keep the patient alive until the antivenom takes effect or venom effects wear off.
1053 Anticholinesterases given with atropine may also be helpful first-aid for postsynaptic neurotoxic
1054 effects. Since the appearance of effects of pre-synaptic neurotoxins may be delayed, snakebite
1055 victims, even those with only limited local signs, should be observed carefully, especially during
1056 the first 24 hours after admission to the hospital (Afshari & Monzavi, 2016b; Monzavi et al., 2014;
1057 Riley et al., 2011; Warrell, 2016).

1058 Optimal medical management of a snakebite envenomed patient requires a comprehensive
1059 approach rather than antivenom therapy alone. Region-specific guidelines or protocols are
1060 advocated for this purpose, as medical system infrastructure, antivenom availability, and locally-
1061 important snake species vary in each country or geographical region (Chippaux & Goyffon, 1998;
1062 Lavonas et al., 2011; Monzavi et al., 2014). In Iran, a group of medical toxicologists has developed
1063 a nationally unified protocol for hospital management of snakebite (Monzavi et al., 2014). This
1064 protocol comprises: (1) a severity grading scale for initial assessment of the clinical condition, (2)
1065 a schematic algorithm that indicates a logical sequence of diagnostic and therapeutic measures
1066 with suggested antivenom dosing, and (3) recommended supportive and adjunctive treatments
1067 when necessary (Monzavi et al., 2014).

1068 In clinical practice, this protocol has reduced antivenom usage, compared to a locally-practiced
1069 anecdotal recommendation for antivenom dosing (Monzavi et al., 2015). The protocol also
1070 reduced the healthcare costs and length of hospital stay (Monzavi et al., 2015). Nonetheless, the
1071 minimum recommended starting dose of antivenom in the new protocol (5 ampoules = 50 mL)
1072 (Monzavi et al., 2014; Monzavi et al., 2015), is still 2.5 times higher than the dosage (2 ampoules
1073 = 20 mL) recommended in the package insert of the Razi™ Antivenin (RVSRI, 2021). This is
1074 because the optimal starting dose of antivenom has not been established by formal clinical trials
1075 in Iran (as in many other parts of the world), and that the US guidelines, as a standard practice,
1076 has been adopted instead (Lavonas et al., 2011; Monzavi et al., 2014; Riley et al., 2011).

1077 As mentioned, some clinicians in southern parts of the country consider their own antivenom
1078 dosing and use their own definition of clinical response, which results in administration of higher
1079 starting (10 ampoules) and maintenance doses of antivenom. Therefore, to establish rational
1080 antivenom dosing, a multi-center blinded randomized dose-finding clinical trial may be required,

in which the envenoming species is identified, to compare the manufacturer's recommended dose of 20-ml with 50-ml and 100-ml doses.

In addition to antivenom therapy, supportive measures are essential for critically ill snakebite patients (Monzavi et al., 2014): (1) assisted ventilation for respiratory muscle paralysis; (2) intravenous fluid replacement with or without vasopressor drugs for hypotension and shock; (3) airway support for bites in the head and neck region with a risk of airway obstruction; (4) blood products to accelerate restoration of hemostasis in response to specific antivenom in patients with severe, spontaneous bleeding (e.g., gastro-intestinal bleeding) causing hemodynamic instability; (5) protection of kidneys from pigment nephropathy caused by myoglobinuria in cases of severe myotoxicity/rhabdomyolysis, or hemolysis; (6) use of anticholinesterases, such as neostigmine or edrophonium chloride, along with atropine to reverse NMJ blockade by post-synaptic neurotoxins in cases of cobra bite envenoming; (7) treatment of secondary bacterial bite wound infections. Despite all the evidence and guidelines discouraging early wound incision and fasciotomy for patients with extensive swelling of the bitten limb (Darracq et al., 2015; Greene et al., 2021; Monzavi et al., 2014; Warrell, 2016), these outdated practices persist in some parts of Iran, increasing the risk of complications such as bleeding, secondary nosocomial infections, prolonged hospital admission and residual deformities (Kazemi et al., 2021c). Whether or not anti-inflammatory treatments may help alleviate the local effects of envenoming is an unanswered question. Results of a recent study in Isfahan that compared single with multiple doses of anti-inflammatory treatments (histamine H1 and H2 blockers and hydrocortisone) suggested some benefit of multiple doses (Dorooshi et al., 2021). However, the results were inconclusive because the study was retrospective, non-randomized, unblinded, did not distinguish envenoming by different species, the two groups were not similar before treatment, and many patients had negligible symptoms.

Sea-snake bite envenoming in Iran is rare. Local sailors and fishermen are aware to avoid sea-snakes and release them untouched from the fishing nets. It should be noted that victims of sea-snake bite envenoming are at risk, because local and systemic effects may be absent during the first few hours after the bite, no specific antivenom is available in the country, and anticholinesterases are unlikely to be effective in sea-snake bite venom-induced neurotoxicity (Nabipour et al., 2015; Warrell, 2016). In the absence of a specific antivenom for sea-snake bite envenoming, medical management is based on supportive measures for controlling the neurotoxic and myotoxic effects that may include airway support, assisted ventilation, and prevention of myoglobinuria-induced AKI (Monzavi et al., 2014; Nabipour et al., 2015). An algorithm for the early-stage management of marine envenomings in Iran has been proposed, but it addresses only primary care measures (Nabipour et al., 2015).

4. DISCUSSION & CONCLUSIONS

4.1. Review of Iran's venomous snake fauna

In this review of medically important snakes of Iran, 17 species of mildly-venomous non-front-fanged Colubridae and Lamprophiidae, and 30 species of venomous snakes, including 15 Viperinae, 1 Crotalinae, and 14 Elapidae are discussed. Occurrence of these species, and their population densities vary across Iran with climate and other environmental characteristics (Dehghani, 2010; Dehghani et al., 2014b; Farzanpay, 1990; Firouz, 2005; Latifi, 1991, 1985; Rastegar-Pouyani et al., 2008; Safaei-Mahroo et al., 2015). Among these, three new species, endemic to Iran, were first described within the last 15 years. We have critically reviewed recent taxonomic revisions to produce an updated checklist with some new additions (e.g., *M. razii,* and *H. cantoris*), some former sub-species have been raised to species status (e.g., *Platyceps ladacensis, P. fieldi, G. caucasicus, V. ebneri*), and some sub-species have been subsumed (e.g., *E. c. multisquamatus, M. r. kurdistanica* and *M. r. albicornuta*). Morphological features are described and illustrated and the country-wide geographical distributions of medically-important species are updated and mapped (**Supplementary File**). However, further taxonomic and zoogeographic revisions are anticipated. Freitas et al. have emphasized that taxonomic status (species/sub-species) is important for understanding biodiversity, and for mobilizing efforts and allocating resources to develop conservation strategies (Freitas et al., 2020). In their review of Eurasian vipers, they questioned the species status of the following taxa, based on genetic divergence, and suggested more appropriate status within other species/species complexes: (1) *M. kuhrangica* and *M. latifii* show only 2% genetic divergence from *M. raddei*; (2) *M. wagneri* is part of the *M. bornmuelleri* group; (3) *V. eriwanensis* and *V. ebneri* show close genetic affinity suggesting sub-specific status within the *V. renardi* group (Freitas et al., 2020).

The occurrence of some species in Iran should be clarified. Despite some studies reporting or proposing presence of *M. wagneri* and *V. a. transcaucasiana* in Iran, their presence has not been supported with solid evidence, and hence needs further scrutiny. There are also questions over the occurrence of *P. fieldi* in Iran. Besides, *H. stokesii* has been recorded in the Makran coast of Pakistan, and it likely (but not definitely) occurs alongside this coast of Iran (Rastegar-Pouyani et al., 2008). Unless the statuses of these species are fully elucidated, the presence of these species in Iran should be considered as doubtful (questionable).

4.2. Importance of species identification of venomous snakes

Knowledge of the geographic range distribution of the different medically-important species will help hospital staff to interpret early symptoms of envenoming by the local species in their area, and to prepare patients and medical staff for the likely evolution and complications of envenoming (Amr et al., 2020; Warrell, 2016). In this way, treatment of envenoming by each species can be optimized. In Iran, as elsewhere in the world, there is a great need to design prospective studies to establish the clinical features (phenotype or syndrome) resulting from

envenoming by each species, to form a sounder basis for diagnostic and therapeutic algorithms. Clinical toxicologists and emergency medicine clinicians should be strongly encouraged to establish and enter into the patients' medical records the identity of the biting species, especially when the responsible snake is brought to the hospital (Bawaskar & Bawaskar, 2019; Monzavi et al., 2019a). Alternatively, smart-phone images, taken at the location where the bite occurred, are increasingly available and can easily be sent electronically to a regional or national reference center/herpetologist for identification. When getting an expert opinion is not feasible, perhaps, a recent effort to devise state-of-the-art machine learning algorithms in Iran, which helps generating cellphone applications for snake image identification with reasonable accuracy and reliability can be seen as a solution (Rajabizadeh & Rezghi, 2021). Far less convincing is recognition by the bite victim of colored pictures or museum specimens of local species, or the use of local snake names. Future clinical research on snakebite in Iran will be greatly assisted if species identification can be confirmed using immunodiagnostic methods, especially in those snakebite cases where the responsible snake is not available for examination.

4.3. Venomous snake conservation and community education

Where natural and human environments interface, lack of public education has contributed to ignorance about the biological and ecological value of snakes, predisposing them to the danger of unnecessary human predation. On the other hand, the risk of snakebite envenoming depends on the extent to which human settlements and agricultural activities encroach upon areas with habitats supporting higher population densities of venomous snake species. Enhancing the level of public awareness and knowledge would appreciably reduce the number of adverse snakebite events and increase public support for the conservation of snakes in nature (Mashhadi et al., 2017; Warrell, 2016). Snakes play an integral role in maintaining ecological equilibrium and controlling rodent- and bat-related zoonoses of human and veterinary public health importance, such as plague, leptospirosis, hantavirus, coronavirus and arenavirus diseases. Studies have revealed some snake venom toxins of potential value in designing new treatments for human diseases such as hypertension, thrombophilia, diabetes mellitus, malignancy, infections and intractable pain, and providing useful diagnostic laboratory reagents (Ali et al., 1999b; Chan et al., 2016; Op den Brouw et al., 2021b). This is an additional argument for conserving venomous snakes. Data on geographical distribution of snakes are crucial for determining regions important for the conservation of species in danger of extinction and preserving their habitat. Given the diverse biogeographic status of Iran, a collaborative approach for the sustainable management of Iranian herpetofauna has been recommended to be made between Iranian governmental institutions and NGOs, and international agencies (Jowkar et al., 2016; Rastegar-Pouyani et al., 2015).

4.4. Clinical features of envenoming and management protocols

In this paper, we have provided species-specific descriptions of the clinical features of envenoming by the medically important snakes of Iran according to available literature. In addition, we discussed the improvements made in the medical management of snakebite victims in Iran, by rationalizing antivenom dosage and through appropriate use of supportive measures according to a recently-developed comprehensive protocol. The use of this protocol is more cost-effective and abandons long-practiced unsubstantiated treatments, while it provides step-by-step instructions for clinicians (Monzavi et al., 2015). Although the antivenoms in Iran are polyvalent, covering the most common venomous species, it is highly likely that the antivenom dosage requirements differ between species as well as with different levels of severity of envenoming. Therefore, formal dose-finding clinical trials are necessary, so that antivenom can be used more effectively, and in view of its economic cost and dose-related risk of adverse reactions, excessive dosage can be avoided.

4.5. Provision of antivenoms and medical staff training

Medical facilities, especially those in areas where snakebites are relatively common, should be provided with vital medications, such as adequate stocks of antivenom, especially during the warm seasons (Mondal et al., 2012; Monzavi et al., 2019b). In each geographical region, one of the main challenges affecting the treatment of snakebite victims has been the training of medical staff to recognize signs and symptoms of envenoming and to understand the distinction of the bites by non-venomous species from the bites by venomous species. Medical staff should receive training in snakebite management, including criteria for transferring severely-envenomed patients to higher levels of medical care when necessary (Warrell, 2016). Community education must also be prioritized along with medical staff training, that in case of a venomous snakebite, the victim should be transported quickly and passively to medical care, without delay for traditional treatments.

DECLARATIONS

Ethical clearance: No experimentation with human subjects was involved in this review.

Conflict of interest: The authors declare that they have no known competing financial interests or personal relationships that could have appeared to influence the work reported in this paper.

Funding and support: This research did not receive any specific grant from funding agencies in the public, commercial, or not-for-profit sectors.

Acknowledgements: We are grateful to Professor Mark O'Shea, University of Wolverhampton, UK, for his collation of records of venomous snakes on Persian Gulf islands. Some of the graphical elements used in the graphical abstract were created using BioRender.com and mindthegraph.com. The graphical abstract elements produced via mindthegraph.com, are made available freely by the website under a free culture Creative Commons license (CC BY-SA 4.0).

Author contributions: Conceptualization (R.D., O.M., D.A.W.); Methodology (S.M.M., O.M.); Investigation (S.M.M., R.D., H.H.M., W.W., A.W., F.M.S.); Validation (S.M.M., D.A.W., D.E.K., W.W., A.W.); Visualization (S.M.M., R.D.); Data curation (S.M.M., O.M.); Formal analysis (S.M.M., D.A.W., O.M.); Writing - original draft (All authors); Writing - review & editing (All authors); Supervision (D.A.W., O.M.)

1234 **FIGURE LEGENDS**

1235 **Fig. 1.** Map of the geographic location of Iran and neighboring countries, and Iran's provinces

1236 **Fig. 2.** Iran's pioneers in herpetology and snakebite, and textbooks of ophiology and natural
1237 conservation. **A,** Professor Mahmoud Latifi; **B,** Professor Reza Farzanpay; **C,** Engineer Eskandar
1238 Firouz; **D.** A group photo in the garden of the Razi Institute, Iran, Left to right: Professor Claus
1239 Andrén, Professor Mahmoud Latifi, Professor Göran Nilson, Professor Reza Farzanpay; **E,** The
1240 Snake Sultan, a nomadic Bakhtiari tribe snake catcher for the Razi Institute in the Zagros
1241 Mountains of eastern Iran, with *Pseudocerastes persicus*; **F,** A group photo at the Fifth
1242 symposium of International Society of Toxinology in Irazú Hotel, Costa Rica, 1976, Left to right:
1243 Professor Findlay E. Russell, Professor William B. Elliott, Professor Akira Ohsaka, Professor David
1244 Chapman, Professor Mahmoud Latifi, Professor Roger Bolaños, Professor H. Alistair Reid,
1245 Professor Yoshio Sawai, Professor Gastão Rosenfeld. **G,** *Snakes of Iran* (Persian version) by M.
1246 Latifi, **H,** *Snakes of Iran* (English translated version), **I,** *Ophiology* (in Persian) by R. Farzanpay; **J,**
1247 *The complete fauna of Iran* (in English) by E. Firouz.

1248 **Fig. 3.** Flow diagram of literature search

1249 **Fig. 4.** Cardinal characteristics of Viperidae. **A,** Vertically elliptical pupil; **B,** Solenoglyph
1250 dentition showing tubular (canaliculated) fangs of *Pseudocerastes persicus* - a viper with a wide
1251 geographic distribution in Iran.

1252 * Figures are from R. Dehghani's personal archive and require permission for reproduction.

1253 **Fig. 5.** Symptoms observed following a facial bite that resulted from severe *Echis carinatus*
1254 envenoming in northeast Iran (with permission). **A & B,** The patient was unable to open her eyes
1255 due to extensive edema. Ecchymosis and blister formation were also present. Arrows show the
1256 bite site (fang marks). The edge of edema was marked on the victim's face with a blue line. The
1257 patient developed thrombocytopenia and consumption coagulopathy; **C,** The patient on the 4th
1258 day post-bite, after administration of 24 vials of snake antivenom (Razi Antivenin), and other
1259 supportive treatments. The edema and ecchymoses were considerably reduced compared to the
1260 day of admission and she could open her left eye (of note, by the 7th day post-bite, the edema on
1261 the right side subsided and she could open her right eye, as well).

1262 * Figures are taken with permission from the patient and legal guardians. The figures are from
1263 S. M. Monzavi's personal archive and require permission for reproduction.

1264 **Fig. 6. A & B,** Edema, blister formation, and local necrosis following Viperidae snakebite in
1265 northeast Iran attributed to *Macrovipera lebetina obtusa* bite. The right upper limb of the patient
1266 is massively swollen; **C,** Rapidly developing swelling and necrosis in a toe attributed to
1267 *Macrovipera lebetina obtusa* bite

1268 * Figures are from S. M. Monzavi's personal archive and require permission for reproduction.

1269 **TABLES**

1270 **Table 1.** Lethal doses (LD_{50}) of Iran's medically important snakes

1271 **Table 2.** Common snakebite envenoming features in Iran

1272

1273

1274 **SUPPLEMENTARY FILE:**

1275 **Table 1S.** Photographs, conservation status and distribution of Iran's medically important
1276 snakes

1277 **Table 2S.** Taxonomy and morphologic features of the mildly-venomous (non-front-fanged)
1278 snakes of Iran

1279 **Table 3S.** Taxonomy and morphological features of the venomous snakes of Iran

REFERENCES

A'alam, A. M. (2000). Antivenom. [In Persian]. In *Encyclopedia of the Islamic World*. Tehran, Iran: Encyclopedia Islamica Foundation.

Abouyannis, M., Aggarwal, D., Lalloo, D. G., Casewell, N. R., Hamaluba, M., & Esmail, H., 2021. Clinical outcomes and outcome measurement tools reported in randomised controlled trials of treatment for snakebite envenoming: A systematic review. PLoS Negl Trop Dis. 15, e0009589.

Abtahi, B., Mosafer Khorjestan, S., Ghezellou, P., Aliahmadi, A., Ranaei Siadat, S. O., Kazemi, S. M., . . . Fathinia, B., 2014. Effects of Iranian Snakes Venom True Sea and Terrestrial Snakes on Some Bacterial Cultures. J Persian Gulf (Marine Sci). 5, 27-36.

Abtin, E., Nilson, G., Mobaraki, A., Hosseini, A. A., & Dehgannejhad, M., 2014. A New Species of Krait, Bungarus (Reptilia, Elapidae, Bungarinae) and the First Record of That Genus in Iran. Russ J Herpetol. 21, 243-250.

Abu Baker, M. A., Al-Saraireh, M., Amr, Z., Amr, S. S., & Warrell, D. A., 2022. Snakebites in Jordan: A clinical and epidemiological study. Toxicon. 208, 18-30.

Abukamar, A., Abudalo, R., Odat, M., Al-Sarayreh, M., Issa, M. B., & Momanie, A., 2022. Arabian Levantine viper bite induces thrombocytopenia - a case report. J Med Life. 15, 867-870.

Afshari, R., Majdzadeh, R., & Balali-Mood, M., 2004. Pattern of acute poisonings in Mashhad, Iran 1993-2000. J Toxicol Clin Toxicol. 42, 965-975.

Afshari, R., & Monzavi, S. M. (2016a). *Afshari's Clinical Toxicology and Poisoning Emergency Care. [In Persian & English]* (3rd ed.). Mashhad, Iran: Mashhad University of Medical Sciences Publication.

Afshari, R., & Monzavi, S. M. (2016b). Venomous animals and arthropods envenomation. [In Persian]. In: R. Afshari & S. M. Monzavi (Eds.), *Afshari's Clinical Toxicology and Poisoning Emergency Care.* (3rd ed., pp. 221-241). Mashhad, Iran: Mashhad University of Medical Sciences Publication.

Ahmadi, M., Hemami, M. R., Kaboli, M., Malekian, M., & Zimmermann, N. E., 2019. Extinction risks of a Mediterranean neo-endemism complex of mountain vipers triggered by climate change. Sci Rep. 9, 6332.

Akbari, A., Rabiei, H., Hedayat, A., Mohammadpour, N., Zolfagharian, H., & Teimorzadeh, S., 2010. Production of effective antivenin to treat cobra snake (Naja naja oxiana) envenoming. Arch Razi Inst. 65, 33-37.

Al-Sadoon, M. K., Abdel-Moneim, A. E., Bauomy, A. A., & Diab, M. S. M., 2013a. Histochemical and Biochemical effects induced by LD50 of Cerastes cerastes gasperetti crude venom in mice. Life Sci J. 10, 810-817.

Al-Sadoon, M. K., Abdel Moneim, A. E., Diab, M. S. M., & Bauomy, A. A., 2013b. Hepatic and renal tissue damages induced by Cerastes cerastes gasperetti crude venom. Life Sci J. 10, 191-197.

Al-Sadoon, M. K., Diab, M. S. M., Bauomy, A. A., & Abdel Moneim, A. E., 2014. Cerastes cerastes gasperettii venom Induced Hematological Alterations and Oxidative Stress in Male Mice. J Pure Appl Microbiol. 8, 693-702.

Al-Sadoon, M. K., Diab, M. S. M., Bauomy, A. A., Abdel Moneim, A. E., & Paray, B. A., 2016. The possible effects of melatonin in Cerastes cerastes gasperettii venom-mediated toxicity and oxidative damage in mice. Curr Sci. 110, 1505-1512.

Al-Sheikhly, O. F., Al-Barazengy, A. N., & Al-Haideri, M. L., 2019. First record of the Iranian Spider Viper Pseudocerastes urarachnoides Bostanchi, Anderson, Kami & Papenfuss, 2006 (Serpentes: Viperidae) in Iraq. Sauria. 41, 43-46.

Al-Sheikhly, O. F., Haba, M. K., Al-Rikabi, H. O., & Al-Haideri, M. L., 2020. New localities of the Iranian Spider-tailed Viper Pseudocerastes urarachnoides (Serpentes: Viperidae) in Iraq. Sauria. 42, 43-46.

1326 Alam, J. M., & Qasim, R., 1993. Changes in serum components induced by venoms of marine animals.
1327 Pak J Pharm Sci. 6, 81-87.
1328 Alavi, S. M., & Alavi, L., 2008. Epidemiology of animal bites and stings in Khuzestan, Iran, 1997–2006. J
1329 Infect Public Health. 1, 51-55.
1330 Alcock, A., Finn, F., Maynard, F. P., & McMahon, A. H., 1896. An account of the Reptilia collected by Dr.
1331 F.P. Maynard, Captain A.H. McMahon, C.I.E., and the members of the Afghan-Baluch Boundary
1332 Commission of 1896. J Asiat Soc Bengal. 65, 550-566
1333 Ali, S. A., Alam, J. M., Stoeva, S., Schutz, J., Abbasi, A., Zaidi, Z. H., & Voelter, W., 1999a. Sea snake
1334 Hydrophis cyanocinctus venom. I. Purification, characterization and N-terminal sequence of two
1335 phospholipases A2. Toxicon. 37, 1505-1520.
1336 Ali, S. A., Hamid, F., Abbasi, A., Zaidi, Z. H., & Shehnaz, D., 1999b. Pharmacological effects of the leaf-
1337 nosed viper snake (Eristocophis macmahoni) venom and its HPLC fractions. Toxicon. 37, 1095-
1338 1107.
1339 Ali, S. A., Jackson, T. N., Casewell, N. R., Low, D. H., Rossi, S., Baumann, K., . . . Fry, B. G., 2015. Extreme
1340 venom variation in Middle Eastern vipers: a proteomics comparison of Eristicophis macmahonii,
1341 Pseudocerastes fieldi and Pseudocerastes persicus. J Proteomics. 116, 106-113.
1342 Alinejad, S., Zamani, N., Abdollahi, M., & Mehrpour, O., 2017. A Narrative Review of Acute Adult
1343 Poisoning in Iran. Iran J Med Sci. 42, 327-346.
1344 Alirahimi, E., Kazemi-Lomedasht, F., Shahbazzadeh, D., Habibi-Anbouhi, M., Hosseininejad Chafi, M.,
1345 Sotoudeh, N., . . . Behdani, M., 2018. Nanobodies as novel therapeutic agents in envenomation.
1346 Biochim Biophys Acta Gen Subj. 1862, 2955-2965.
1347 Almasieh, K., Mirghazanfari, S. M., & Mahmoodi, S., 2019. Biodiversity hotspots for modeled habitat
1348 patches and corridors of species richness and threatened species of reptiles in central Iran. Eur J
1349 Wildl Res. 65, 92.
1350 Ambartsumian, A. A. (2001). *Thrita and Avicenna: The Origin of Medicine in Central Asia* Paper presented
1351 at the The 2nd International Ibn Sino (Avicenna) Readings, Tashkent-Bukhara, Uzbekistan.
1352 Amininasab, M., Elmi, M. M., Endlich, N., Endlich, K., Parekh, N., Naderi-Manesh, H., . . . Muhle-Goll, C.,
1353 2004. Functional and structural characterization of a novel member of the natriuretic family of
1354 peptides from the venom of Pseudocerastes persicus. FEBS Lett. 557, 104-108.
1355 Amirian, P., Shahveisi, K., Pazhouhi, M., & Jalili, C., 2022. Anti-proliferative and Apoptosis Induction
1356 effect of Iranian Snake Venom (Vipera Raddei Kurdistanica) on Human Breast Cancer (MCF-7)
1357 and Normal Breast (MCF-10a) Cell Lines. [In Persian]. Sci J Kurdistan Univ Med Sci. 26, 1-10.
1358 Amoozegari, Z., Abyaz, S., & Noorbehbahani, M., 2016. Measurement of Hyaluronidase Enzyme Activity
1359 in Venom of Iranian Vipera Lebetina. [In Persian]. Jundishapur Sci Med J. 15, 363-370.
1360 Amoozegari, Z., Zare Mirakabadi, A., & Noorbehbahani, M., 2013. Purification of Blood Coagulation
1361 Factor V Activator from the Venom of Iranian Vipera Lebetina. [In Persian]. Jundishapur Sci Med
1362 J. 12, 21-32.
1363 Amoozgari, Z., Cheraghzadeh, M., Noorbehbahani, M., & Lamuchi Deli, N., 2020. Identification of
1364 Fibrinolytic Activity in Iranian Vipera Lebetina Venom. [In Persian]. J Mazandaran Univ Med Sci.
1365 30, 17-25.
1366 Amr, Z. S., Abu Baker, M. A., & Warrell, D. A., 2020. Terrestrial venomous snakes and snakebites in the
1367 Arab countries of the Middle East. Toxicon. 177, 1-15.
1368 Amrollahi Byoki, E., & Zare Mirakabadi, A., 2013. Partial purification and characterization of
1369 anticoagulant factor from the snake (echis carinatus) venom. Iran J Basic Med Sci. 16, 1139-
1370 1144.
1371 Ana Maria, R., 2021. Toxicology and snakes in ptolemaic Egyptian dynasty: The suicide of Cleopatra.
1372 Toxicol Rep. 8, 676-695.

1373 Angaji, S. A., Houshmandi, A., & Zare Mirakabadi, A., 2016. Acute Effects of the Iranian Snake (Naja Naja
1374 Oxiana) Venom on Heart. Biomacromolecular J. 2, 97-101.
1375 Ansari, A., 2020. Habitat evaluation of Levantine viper (Macrovipera lebetina. Linnaeus, 1758) in Haftad-
1376 Gholleh protected area, Markazi province, Iran. J Wildl Biodiv. 4, 1-7.
1377 Araujo, P. F., Silva, W. M. D., Franca, R. C., & Franca, F. G. R., 2018. A case of envenomation by
1378 neotropical Opisthoglyphous snake Thamnodynastes pallidus (Linnaeus, 1758) (Colubridae:
1379 Dipsadinae: Tachymenini) in Brazil. Rev Inst Med Trop Sao Paulo. 60, e38.
1380 Archundia, I. G., de Roodt, A. R., Ramos-Cerrillo, B., Chippaux, J. P., Olguin-Perez, L., Alagon, A., & Stock,
1381 R. P., 2011. Neutralization of Vipera and Macrovipera venoms by two experimental polyvalent
1382 antisera: a study of paraspecificity. Toxicon. 57, 1049-1056.
1383 Ariaratnam, C. A., Sheriff, M. H., Arambepola, C., Theakston, R. D., & Warrell, D. A., 2009. Syndromic
1384 approach to treatment of snake bite in Sri Lanka based on results of a prospective national
1385 hospital-based survey of patients envenomed by identified snakes. Am J Trop Med Hyg. 81, 725-
1386 731.
1387 Arnold, N., Robinson, M., & Carranza, S., 2009. A preliminary analysis of phylogenetic relationships and
1388 biogeography of the dangerously venomous Carpet Vipers, Echis (Squamata, Serpentes,
1389 Viperidae) based on mitochondrial DNA sequences. Amphibia-Reptilia. 30, 273-282.
1390 Asadi, A., Kaboli, M., Ahmadi, M., Kafash, A., Nazarizadeh, M., Behrooz, R., & Rajabizadeh, M., 2016.
1391 Prediction for relict population of Mountains Vipres (Montivipera spp) in western Iran; an
1392 ensemble distribution modeling along with climate change detection from past to future. [In
1393 Persian]. J Nat Environ. 69, 303-327.
1394 Asadi, A., Montgelard, C., Nazarizadeh, M., Moghaddasi, A., Fatemizadeh, F., Simonov, E., . . . Kaboli, M.,
1395 2019. Evolutionary history and postglacial colonization of an Asian pit viper (Gloydius halys
1396 caucasicus) into Transcaucasia revealed by phylogenetic and phylogeographic analyses. Sci Rep.
1397 9, 1224.
1398 Astaraki, P., Basati, G., Abbaszadeh, S., & Mahmoudi, G. A., 2020. A Review of medicinal plants used for
1399 snakebites and scorpion stings in Iran: A systematic review. Res J Pharm Technol. 13, 1565-1569.
1400 Babaie, M., Salmanizadeh, H., & Zolfagharian, H., 2013a. Blood coagulation induced by Iranian saw-
1401 scaled viper (echis carinatus) venom: identification, purification and characterization of a
1402 prothrombin activator. Iran J Basic Med Sci. 16, 1145-1150.
1403 Babaie, M., Zolfagharian, H., Salmanizadeh, H., Mirakabadi, A. Z., & Alizadeh, H., 2013b. Isolation and
1404 partial purification of anticoagulant fractions from the venom of the Iranian snake Echis
1405 carinatus. Acta Biochim Pol. 60, 17-20.
1406 Bagherian, A., & Kami, H., 2008. On taxonomic status of the saw-scaled viper genus Echis (Viperidae:
1407 Reptilia) in Iran. [In Persian]. Iran J Biol. 21, 501-508.
1408 Balali-Mood, M., & Shariat, M. (1999). *Scientific Basis Practical Guide of Envenomation; prevention,*
1409 *diagnosis and treatment. [In Persian]*. Tehran, Iran: Teimourzadeh.
1410 Balali Bahadorani, M., & Zare Mirakabadi, A., 2016. Cytopathic Effect of Snake (Echis Carinatus) Venom
1411 on Human Embryonic Kidney Cells. Asia Pac J Med Toxicol. 5, 88-93.
1412 Banaye Yazdipour, A., Sarbaz, M., Dadpour, B., Moshiri, M., & Kimiafar, K., 2020. Development a national
1413 minimum data set for poisoning registry in Iran. Int J Health Plan Manag. 35, 1453-1467.
1414 Banijamali, S. E., Amininasab, M., & Elmi, M. M., 2019. Characterization of a new member of kunitz-type
1415 protein family from the venom of Persian false-horned viper, Pseudocerastes persicus. Arch
1416 Biochem Biophys. 662, 1-6.
1417 Barati, M., & Davoudi, D., 2017. Evaluation of toxicity and anticancer activity of isolated fraction from
1418 the venom of Iranian cobra snake on acute lymphoblastic leukemia cells (Jurkat E6. 1). [In
1419 Persian]. Cell Tissue J. 8, 250-260.

1420 Barfaraz, A., & Harvey, A. L., 1994. The use of the chick biventer cervicis preparation to assess the
1421 protective activity of six international reference antivenoms on the neuromuscular effects of
1422 snake venoms in vitro. Toxicon. 32, 267-272.
1423 Barkagan, Z. S. (1964). *Diagnosis, symptoms and treatment of envenomings by snake venoms and*
1424 *arthropods of Central Asia. [In Russian].* (M. D.), Sverdlovsk State Medical Institute, Sverdlovsk,
1425 Russia.
1426 Bassam, M., 1995. Systemic changes in rats after injection of crude venom from cerastes gasperetti. J
1427 Saudi Heart Assoc. 7, 31-34.
1428 Batzri-Izraeli, R., & Bdolah, A., 1982. Isolation and characterization of the main toxic fraction from the
1429 venom of the false horned viper (Pseudocerastes fieldi). Toxicon. 20, 867-875.
1430 Bawaskar, H. S., & Bawaskar, P. H., 2019. Snakebite envenoming. Lancet. 393.
1431 Baxter, E. H., & Gallichio, H. A., 1976. Protection against sea snake envenomation: comparative potency
1432 of four antivenenes. Toxicon. 14, 347-355.
1433 Bazaa, A., Marrakchi, N., El Ayeb, M., Sanz, L., & Calvete, J. J., 2005. Snake venomics: comparative
1434 analysis of the venom proteomes of the Tunisian snakes Cerastes cerastes, Cerastes vipera and
1435 Macrovipera lebetina. Proteomics. 5, 4223-4235.
1436 Bazi, A., Ghasempouri, S. K., Sahebnasagh, A., & Saghafi, F., 2019. Bite by the Sheltopusik (Pseudopus
1437 apodus), Locally Called Petilus Snake, to Humans: A Case Report. Asia Pac J Med Toxicol. 8, 104-
1438 106.
1439 Bdolah, A., 1986. Comparison of venoms from two subspecies of the false horned viper (Pseudocerastes
1440 persicus). Toxicon. 24, 726-729.
1441 Behrooz, R., Kaboli, M., Arnal, V., Nazarizadeh, M., Asadi, A., Salmanian, A., . . . Montgelard, C., 2018.
1442 Conservation Below the Species Level: Suitable Evolutionarily Significant Units among Mountain
1443 Vipers (the Montivipera raddei complex) in Iran. J Hered. 109, 416-425.
1444 Behrooz, R., Kaboli, M., Nourani, E., Ahmadi, M., Alizadeh Shabani, A., Yousefi, M., . . . Rajabizadeh, M.,
1445 2015. Habitat modeling and conservation of the endemic Latifi's Viper (Montivipera latifii) in Lar
1446 National Park, Northern Iran. Herpetol Conserv Biol. 10, 572-582.
1447 Besharat, M., Vahdani, P., Abbasi, F., & Korooni Fardkhani, S., 2008. Reporting A Series of 100 Cases of
1448 Snake Bites in Loghman Hospital between 2000-2005. [In Persian]. Res Bull Med Sci. 13, 315-
1449 320.
1450 Betts, J., Young, R., Hilton-Taylor, C., Hoffmann, M., Rodriguez, J. P., Stuart, S. N., & Milner-Gulland, E. J.,
1451 2020. A framework for evaluating the impact of the IUCN Red List of Threatened Species.
1452 Conserv Biol. 34, 632-643.
1453 Bhat, R. N., 1974. Viperine snake bite poisoning in Jammu. J Indian Med Assoc. 63, 383-392.
1454 Blaylock, R. S., 2014. The identification and syndromic management of snakebite in South Africa. S Afr
1455 Fam Pract. 47, 48-53.
1456 Bok, B., Berroneau, M., Yousefi, M., Nerz, J., Deschandol, F., Berroneau, M., & Tiemann, L., 2017.
1457 Sympatry of Pseudocerastes persicus and P. urarachnoides in the western Zagros Mountains,
1458 Iran. Herpetol Notes. 10, 323-325.
1459 Bostanchi, H., Anderson, S. C., G., K. H., & J., P. T., 2006. A new species of Pseudocerastes with elaborate
1460 tail ornamentation from western Iran (Squamata: Viperidae). Proc Calif Acad Sci. 57, 443-450.
1461 Branch, W., 1982. Venomous snakes of southern Africa. 3. Concluding part: Colubridae. The Snake. 14, 1-
1462 17.
1463 Brandehoff, N., Smith, C. F., Buchanan, J. A., Mackessy, S. P., & Bonney, C. F., 2019. First reported case of
1464 thrombocytopenia from a Heterodon nasicus envenomation. Toxicon. 157, 12-17.
1465 Broad, A. J., Sutherland, S. K., & Coulter, A. R., 1979. The lethality in mice of dangerous Australian and
1466 other snake venom. Toxicon. 17, 661-664.

1467 Calvete, J. J., Ghezellou, P., Paiva, O., Matainaho, T., Ghassempour, A., Goudarzi, H., . . . Williams, D. J.,
1468 2012. Snake venomics of two poorly known Hydrophiinae: Comparative proteomics of the
1469 venoms of terrestrial Toxicocalamus longissimus and marine Hydrophis cyanocinctus. J
1470 Proteomics. 75, 4091-4101.
1471 Calvete, J. J., Pla, D., Els, J., Carranza, S., Damm, M., Hempel, B. F., . . . Encinar, J. R., 2021. Combined
1472 Molecular and Elemental Mass Spectrometry Approaches for Absolute Quantification of
1473 Proteomes: Application to the Venomics Characterization of the Two Species of Desert Black
1474 Cobras, Walterinnesia aegyptia and Walterinnesia morgani. J Proteome Res. 5, 5064-5078.
1475 Carey, J. E., & Wright, E. A., 1960. The toxicity and immunological properties of some sea-snake venoms
1476 with particular reference to that of Enhydrina schistosa. Trans R Soc Trop Med Hyg. 54, 50-67.
1477 Carné, A., Fathinia, B., & Rastegar-Pouyani, E., 2020. Molecular phylogeny of the Arabian Horned Viper,
1478 Cerastes gasperettii (Serpentes: Viperidae) in the Middle East. Zool Middle East. 66, 13-20.
1479 Casewell, N. R., Harrison, R. A., Wuster, W., & Wagstaff, S. C., 2009. Comparative venom gland
1480 transcriptome surveys of the saw-scaled vipers (Viperidae: Echis) reveal substantial intra-family
1481 gene diversity and novel venom transcripts. BMC Genomics. 10, 564.
1482 Celen, C., Kececiler, C., Karis, M., Gocmen, B., Yesil-Celiktas, O., & Nalbantsoy, A., 2018. Cytotoxicity of
1483 Silica Nanoparticles with Transcaucasian Nose-Horned Viper, Vipera ammodytes
1484 transcaucasiana, Venom on U87MG and SHSY5Y Neuronal Cancer Cells. Appl Biochem
1485 Biotechnol. 186, 350-357.
1486 Chan, Y. S., Cheung, R. C., Xia, L., Wong, J. H., Ng, T. B., & Chan, W. Y., 2016. Snake venom toxins: toxicity
1487 and medicinal applications. Appl Microbiol Biotechnol. 100, 6165-6181.
1488 Cherlin, V. A., 1981. The new saw-scaled viper Echis multisquamatus sp. nov. from south-western and
1489 Middle Asia. [In Russian]. Proc Zool Inst Acad Sci USSR. 101, 92-95.
1490 Cherlin, V. A., 1990. Taxonomic revision of the snake genus Echis (viperidae) II. An analysis of taxonomy
1491 and description of new forms. [In Russian]. Proc Zool Inst Leningrad. 207, 193-223.
1492 Chippaux, J. P., & Goyffon, M., 1998. Venoms, antivenoms and immunotherapy. Toxicon. 36, 823-846.
1493 Chowdhury, A., Zdenek, C. N., & Fry, B. G., 2022. Diverse and Dynamic Alpha-Neurotoxicity Within
1494 Venoms from the Palearctic Viperid Snake Clade of Daboia, Macrovipera, Montivipera, and
1495 Vipera. Neurotox Res.
1496 Chowdhury, A., Zdenek, C. N., Lewin, M. R., Carter, R., Jagar, T., Ostanek, E., . . . Fry, B. G., 2021. Venom-
1497 Induced Blood Disturbances by Palearctic Viperid Snakes, and Their Relative Neutralization by
1498 Antivenoms and Enzyme-Inhibitors. Front Immunol. 12, 688802.
1499 Chroni, E., Papapetropoulos, S., Argyriou, A. A., & Papapetropoulos, T., 2005. A case of fatal progressive
1500 neuropathy. Delayed consequence of multiple bites of a non-venomous snake? Clin Neurol
1501 Neurosurg. 108, 45-47.
1502 Corkill, N. L. (1932). *Snakes and Snake Bite in Iraq : A Handbook for Medical Officers*. London, UK
1503 Bailliere Tindall and Cox, Royal College of Medicine of Iraq.
1504 Corkill, N. L., 1939. Snake Specialists in Iraq. Iraq. 6, 45-52.
1505 Dadashi Arani, M., & Mastali Parsa, G. R., 2020. Medicine and Health in Ancient Iran, Persian Language
1506 and Literature, and the Divan of Hakim Mashreqi Shirazi. [In Persian]. J Payavard Salamat. 14,
1507 383-393.
1508 Dadpour, B., Shafahi, A., Monzavi, S. M., Zavar, A., Afshari, R., & Khoshdel, A. R., 2012. Snakebite
1509 prognostic factors: Leading factors of weak therapeutic response following snakebite
1510 envenomation. Asia Pac J Med Toxicol. 1, 27-33.
1511 Darevsky, I. S., 1966. Ecology of rock-viper (Vipera xanthina raddei Boettger) in the natural surroundings
1512 of Armenia. Mem Inst Butantan Simp Internac. 33, 81-83.

Darevsky, I. S. (1969). Family of Serpentine snakes (Colubridae) In: M. S. Giliarov, L. A. Zenkevich, & A. G. Bannikov (Eds.), *The Life of Animals, 4 (2): Amphibians and reptiles. [In Russian]* (pp. 351-391). Moscow, Russia: Prosveshenie Moskva.

Darracq, M. A., Cantrell, F. L., Klauk, B., & Thornton, S. L., 2015. A chance to cut is not always a chance to cure- fasciotomy in the treatment of rattlesnake envenomation: A retrospective poison center study. Toxicon. 101, 23-26.

Dashevsky, D., Debono, J., Rokyta, D., Nouwens, A., Josh, P., & Fry, B. G., 2018. Three-Finger Toxin Diversification in the Venoms of Cat-Eye Snakes (Colubridae: Boiga). J Mol Evol. 86, 531-545.

De Filippi, F. (1865). *Note di un viaggio di Persia nel 1862. [In Italian]*. Milan, Italy: G. Daelli e C. Editori.

Dehghani, R. (2010). *Environmental Toxicology. [In Persian]* (1st ed.). Kashan, Iran: Kashan University of Medical Sciences Publications.

Dehghani, R., Ahaki Varzaneh, A., Varzandeh, M., Akbari, M., & Jahani, A., 2022. Venomous animal bites and stings in Lordegan city, Chaharmahal Bakhtiari province of Iran in 2019–2020. J Entomol Res. 46, 694-698.

Dehghani, R., Dadpour, B., & Mehrpour, O., 2014a. Epidemiological Profile of Snakebite in Iran, 2009-2010 Based on Information of Ministry of Health and Medical Education. Int J Med Toxicol Forensic Med. 4, 33-41.

Dehghani, R., Fathi, B., Shahi, M. P., & Jazayeri, M., 2014b. Ten years of snakebites in Iran. Toxicon. 90, 291-298.

Dehghani, R., Kassiri, H., & Dehghani, M., 2020. A brief review on biting/stinging of animals and its risk of infection. Arch Clin Infect Dis. 15, e97499.

Dehghani, R., Mehrpour, O., Shahi, M. P., Jazayeri, M., Karrari, P., Keyler, D., & Zamani, N., 2014c. Epidemiology of venomous and semi-venomous snakebites (Ophidia: Viperidae, Colubridae) in the Kashan city of the Isfahan province in Central Iran. J Res Med Sci. 19, 33-40.

Dehghani, R., Rabani, D., Panjeh Shahi, M., Jazayeri, M., & Sabahi Bidgoli, M., 2012. Incidence of snake bites in kashan, iran during an eight year period (2004-2011). Arch Trauma Res. 1, 67-71.

Dehghani, R., Rastegar Pouyani, N., Dadpour, B., Keyler, D., Panjehshahi, M., Jazayeri, M., . . . Habibi Tamijani, A., 2016a. A survey on Non-Venomous Snakes in Kashan (Central Iran). J Biol Today World. 5, 65-75.

Dehghani, R., Sharif, A., Assadi, M. A., Haddad Kashani, H., & Sharif, M. R., 2016b. Fungal flora in the mouth of venomous and non-venomous snakes. Comp Clin Pathol. 25, 1207-1211.

Dehghani, R., Sharif, A., Madani, M., Kashani, H. H., & Sharif, M. R., 2016c. Factors Influencing Animal Bites in Iran: A Descriptive Study. Osong Public Health Res Perspect. 7, 273-277.

Dehghani, R., Sharif, M. R., Moniri, R., Sharif, A., & Haddad Kashani, H., 2015. The identification of bacterial flora in oral cavity of snakes. Comp Clin Pathol. 25, 279-283.

del Marmol, G. M., Mozaffari, O., & Gállego, J., 2016. Pseudocerastes urarachnoides: the ambush specialist. Bol Asoc Herpetol Esp. 27, 36-42.

Derakhshani, A., Silvestris, N., Hajiasgharzadeh, K., Mahmoudzadeh, S., Fereidouni, M., Paradiso, A. V., . . . Baradaran, B., 2020. Expression and characterization of a novel recombinant cytotoxin II from Naja naja oxiana venom: A potential treatment for breast cancer. Int J Biol Macromol. 162, 1283-1292.

Dhananjaya, B. L., Menon, J. C., Joseph, J. K., Raveendran, D. K., & Oommen, O. V. (2015). Snake Venom Detection Kit (SVDK): Update on Current Aspects and Challenges. In: P. Gopalakrishnakone, A. Faiz, R. Fernando, C. Gnanathasan, A. Habib, & Y. C.C. (Eds.), *Clinical Toxinology in Asia Pacific and Africa* (pp. 379-400). Netherlands, Dordrecht: Springer.

Di Nicola, M. R., Pontara, A., Kass, G. E. N., Kramer, N. I., Avella, I., Pampena, R., . . . Paolino, G., 2021. Vipers of Major clinical relevance in Europe: Taxonomy, venom composition, toxicology and clinical management of human bites. Toxicology. 453, 152724.

1561 Dorooshi, G., Javid, Z. N., Meamar, R., Farjzadegan, Z., Nasri, M., & Eizadi-Mood, N., 2021. Evaluation of
1562 The effects of Anti-Inflammatory Drugs on Local and Systemic manifestations of snakebite: A
1563 cross-sectional study. J Venom Res. 11, 21-25.
1564 Ebrahim, K., Shirazi, F. H., Mirakabadi, A. Z., & Vatanpour, H., 2015. Cobra venom cytotoxins; apoptotic
1565 or necrotic agents? Toxicon. 108, 134-140.
1566 Ebrahim, K., Vatanpour, H., Zare, A., Shirazi, F. H., & Nakhjavani, M., 2016. Anticancer Activity a of
1567 Caspian Cobra (Naja naja oxiana) snake Venom in Human Cancer Cell Lines Via Induction of
1568 Apoptosis. Iran J Pharm Res. 15, 101-112.
1569 Ebrahimi, V., Hamdami, E., Khademian, M. H., Moemenbellah-Fard, M. D., & Vazirianzadeh, B., 2018.
1570 Epidemiologic prediction of snake bites in tropical south Iran: Using seasonal time series
1571 methods. Clin Epidemiol Glob Health. 6, 208-215.
1572 Efendiev, I. N. (2021). Modern approaches to the provision of specialized medical aid for Gyurza bites
1573 and other viper family snakebites. [In Russian]. In: V. A. Manukovskiy, V. E. Parfenov, I. A.
1574 Voznyuk, & I. M. Barsukova (Eds.), *Dzhanelidzevskie Readings* (pp. 185-187). Saint Petersburg,
1575 Russia: Dzhanelidze Research Institute of Emergency Medicine.
1576 Elfiky, A. A., Girgis, E. F., Zid, M. M., & Mohamed, Y. E., 2022. Cross neutralization of some kinds of vipers
1577 and snake venoms from Africa and Middle East using VACSERA polyvalent viper antisera. J Egypt
1578 Soc Parasitol. 52, 363-370.
1579 Elkabbaj, D., Hassani, K., & El Jaoudi, R., 2012. Acute renal failure following the Saharan horned viper
1580 (Cerastes cerastes) bite. Arab J Nephrol Transplant. 5, 159-161.
1581 Elmi, M. M., Amininasab, M., Hondo, T., Kikuchi, J., Kuroda, Y., Naderi-Manesh, H., & Sarbolouki, M. N.,
1582 2006. Structural and functional characterization of a mutant of Pseudocerastes persicus
1583 natriuretic peptide. Protein Pept Lett. 13, 295-300.
1584 Eskafi, A. H., Bagheri, K. P., Behdani, M., Yamabhai, M., Shahbazzadeh, D., & Kazemi-Lomedasht, F.,
1585 2021. Development and characterization of human single chain antibody against Iranian
1586 Macrovipera lebetina snake venom. Toxicon. 197, 106-113.
1587 Eslamian, L., Mobaiyen, H., Bayat-Makoo, Z., Piri, R., Benisi, R., & Naghavi-Behzad, M., 2016. Snake bite
1588 in Northwest Iran: A retrospective study. J Anal Res Clin Med. 4, 133-138.
1589 Esmaeili Jahromi, H., Zare Mirakabadi, A., & Kamalzadeh, M., 2016. Evaluation of Iranian Snake
1590 'Macrovipera lebetina' Venom Cytotoxicity in Kidney Cell Line HEK-293. Asia Pac J Med Toxicol.
1591 5, 49-54.
1592 Esmaili, A., Kamyab, M., Fatemikia, H., Ahmadzadeh, H., Movahed, A., Kim, E., . . . Seyedian, R., 2021.
1593 Experimental Evaluation of Mouse Hind Paw Edema Induced by Iranian Naja oxiana Venom.
1594 Arch Razi Inst. 76, 139-147.
1595 Ettling, J., Aghasyan, A., & Aghasyan, L., 2012. Envenomation by an Armenian Viper, Montivipera raddei
1596 (Boettger 1890): A Case History. Russ J Herpetol. 19, 203-206.
1597 Fakharmanesh, Z., Rastegar Pouyani, E., & Kami, H. G., 2014. The Study of Genetic Variation in Different
1598 Populations of the Zigzag Mountain Viper (Montivipera Albicornuta) in Its Distribution Range by
1599 Using Mitochondrial Gene Sequencing. [In Persian]. J Anim Biol. 7, 67-74.
1600 Fallahi, N., Shahbazzadeh, D., Maleki, F., Aghdasi, M., Tabatabaie, F., & Khanaliha, K., 2020. The In Vitro
1601 Study of Anti-leishmanial Effect of Naja naja oxiana Snake Venom on Leishmania major. Infect
1602 Disord Drug Targets. 20, 913-919.
1603 Farstad, D., Thomas, T., Chow, T., Bush, S., & Stiegler, P., 1997. Mojave rattlesnake envenomation in
1604 southern California: a review of suspected cases. Wilderness Environ Med. 8, 89-93.
1605 Farzad, R., Gholami, A., Hayati Roodbari, N., & Shahbazzadeh, D., 2020. The anti-rabies activity of
1606 Caspian cobra venom. Toxicon. 186, 175-181.
1607 Farzan, M., Karami, M., & Kaseb, M. H., 2003. A case report of Volkmann's ischemic contracture in
1608 extensor muscle of forearm following snakebite. [In Persian]. Sci J Forensic Med. 9, 143-146.

1609 Farzaneh, E., Fouladi, N., Shafaee, Y., Mirzamohammadi, Z., Naslseraji, F., & Mehrpour, O., 2017.
1610 Epidemiological study of snakebites in Ardabil Province (Iran). Electron Physician. 9, 3986-3990.
1611 Farzanpay, R. (1990). *Ophiology. [In Persian]*. Iran, Tehran: Iran University Press
1612 Fatehi-Hassanabad, Z., & Fatehi, M., 2004. Characterisation of some pharmacological effects of the
1613 venom from Vipera lebetina. Toxicon. 43, 385-391.
1614 Fathi, B., Yonuesi, F., & Salami, F., 2022. Acute Venom Toxicity Determinations for Five Iranian Vipers
1615 and a scorpion. Iran J Toxicol. 16, 73-82.
1616 Fathinia, B., Anderson, S. C., Rastegar-Pouyani, N., Jahani, H., & Mohamadi, H., 2009. Notes on the
1617 natural history of Pseudocerastes urarachnoides (Squamata: Viperidae). Russ J Herpetol. 16,
1618 134-138.
1619 Fathinia, B., & Rastegar-Pouyani, N., 2010. On the species of Pseudocerastes (Ophidia: Viperidae) in Iran.
1620 Russ J Herpetol. 17, 275-279.
1621 Fathinia, B., Rastegar-Pouyani, N., & Rastegar-Pouyani, E., 2018. Molecular phylogeny and historical
1622 biogeography of genera Eristicophis and Pseudocerastes (Ophidia, Viperidae). Zool Scr. 47, 673-
1623 685.
1624 Fathinia, B., Rastegar-Pouyani, N., Rastegar-Pouyani, E., Todehdehghan, F., & Mansouri, M., 2016.
1625 Annual activity pattern of Pseudocerastes urarachnoides BOSTANCHI, ANDERSON, KAMI &
1626 PAPENFUSS, 2006, with notes on its natural history (Squamata: Serpentes: Viperidae).
1627 Herpetozoa. 29, 135-142.
1628 Fathinia, B., Rastegar-Pouyani, N., Rastegar-Pouyani, E., Toodeh-Dehghan, F., & Rajabizadeh, M., 2014.
1629 Molecular systematics of the genus Pseudocerastes (Ophidia: Viperidae) based on the
1630 mitochondrial cytochrome\beta gene. Turk J Zool. 38, 575-581.
1631 Fathinia, B., Rastegar Pouyani, N., & Rajabzadeh, M., 2011. The snake fauna of Ilam Province,
1632 southwestern Iran. Iran J Anim Biosyst. 6, 9-23.
1633 Fathinia, B., Rödder, D., Rastegar-Pouyani, N., Rastegar-Pouyani, E., Hosseinzadeh, M. S., & Kazemi, S.
1634 M., 2020. The past, current and future habitat range of the Spider-tailed Viper, Pseudocerastes
1635 urarachnoides (Serpentes: Viperidae) in western Iran and eastern Iraq as revealed by habitat
1636 modelling. Zool Middle East. 66, 197-205.
1637 Figueroa, A., McKelvy, A. D., Grismer, L. L., Bell, C. D., & Lailvaux, S. P., 2016. A Species-Level Phylogeny
1638 of Extant Snakes with Description of a New Colubrid Subfamily and Genus. PLoS One. 11,
1639 e0161070.
1640 Firouz, E. (2005). *The Complete Fauna of Iran*. New York, USA: I.B. Tauris.
1641 Francis, B., Bdolah, A., & Kaiser, II. 1995. Amino acid sequences of a heterodimeric neurotoxin from the
1642 venom of the false horned viper (Pseudocerastes fieldi). Toxicon. 33, 863-874.
1643 Freitas, I., Ursenbacher, S., Mebert, K., Zinenko, O., Schweiger, S., Wüster, W., . . . Fahd, S., 2020.
1644 Evaluating taxonomic inflation: towards evidence-based species delimitation in Eurasian vipers
1645 (Serpentes: Viperinae). Amphibia-Reptilia. 41, 285-311.
1646 Fry, B. G., Wuster, W., Ryan Ramjan, S. F., Jackson, T., Martelli, P., & Kini, R. M., 2003. Analysis of
1647 Colubroidea snake venoms by liquid chromatography with mass spectrometry: evolutionary and
1648 toxinological implications. Rapid Commun Mass Spectrom. 17, 2047-2062.
1649 Fuchs, J., Gessner, T., Kupferschmidt, H., & Weiler, S., 2022. Exotic venomous snakebites in Switzerland
1650 reported to the National Poisons Information Centre over 22 years. Swiss Med Wkly. 152,
1651 w30117.
1652 Garcia-Arredondo, A., Martinez, M., Calderon, A., Saldivar, A., & Soria, R., 2019. Preclinical Assessment
1653 of a New Polyvalent Antivenom (Inoserp Europe) against Several Species of the Subfamily
1654 Viperinae. Toxins (Basel). 11, 149.
1655 Garcia-Lima, E., & Laure, C. J., 1987. A study of bacterial contamination of rattlesnake venom. Rev Soc
1656 Bras Med Trop. 20, 19-21.

1657 Gasanov, S. E., Dagda, R. K., & Rael, E. D., 2014. Snake Venom Cytotoxins, Phospholipase A2s, and
1658 Zn(2+)-dependent Metalloproteinases: Mechanisms of Action and Pharmacological Relevance. J
1659 Clin Toxicol. 4, 1000181.
1660 Gasanov, S. E., Shrivastava, I. H., Israilov, F. S., Kim, A. A., Rylova, K. A., Zhang, B., & Dagda, R. K., 2015.
1661 Naja naja oxiana Cobra Venom Cytotoxins CTI and CTII Disrupt Mitochondrial Membrane
1662 Integrity: Implications for Basic Three-Fingered Cytotoxins. PLoS One. 10, e0129248.
1663 Ghelichy Salakh, A., Kami, H., & Rajabizadeh, M., 2020. Modeling the species distribution of Caucasian
1664 pit viper (Gloydius halys caucasicus)(Viperidae: Crotalinae) under the influence of climate
1665 change. Caspian J Environ Sci. 18, 217-226.
1666 Ghelichy Salakh, A., Kami, H. G., & Rajabizadeh, K., 2019. Distribution modeling of Caucasian pit viper,
1667 Gloydius halys caucasicus in Iran (Ophidia: Viperidae). [In Persian]. J Anim Environ. 11, 139-146.
1668 Ghezellou, P., Albuquerque, W., Garikapati, V., Casewell, N. R., Kazemi, S. M., Ghassempour, A., &
1669 Spengler, B., 2021. Integrating Top-Down and Bottom-Up Mass Spectrometric Strategies for
1670 Proteomic Profiling of Iranian Saw-Scaled Viper, Echis carinatus sochureki, Venom. J Proteome
1671 Res. 20, 895-908.
1672 Ghezellou, P., Dillenberger, M., Kazemi, S. M., Jestrzemski, D., Hellmann, B., & Spengler, B., 2022.
1673 Comparative Venom Proteomics of Iranian, Macrovipera lebetina cernovi, and Cypriot,
1674 Macrovipera lebetina lebetina, Giant Vipers. Toxins (Basel). 14, 716.
1675 Ghezellou, P., Garikapati, V., Kazemi, S. M., Strupat, K., Ghassempour, A., & Spengler, B., 2019. A
1676 perspective view of top-down proteomics in snake venom research. Rapid Commun Mass
1677 Spectrom. 33 Suppl 1, 20-27.
1678 Gholamifard, A., 2011. Endemism in the reptile fauna of Iran. Iran J Anim Biosyst. 7, 13-29.
1679 Gholamifard, A., & Esmaeili, H. R., 2010. First record and range extension of Field's horned viper,
1680 Pseudocerastes fieldi Schmidt, 1930 (Squamata: Viperidae), from Fars province, southern Iran.
1681 Turk J Zool. 34, 551-552.
1682 Gholamifard, A., & Rastegar-Pouyani, N. (2012). *Systematics and Distribution of Walterinnesia morgani*
1683 *(Mocquard, 1905) (Elapidae) in Iran.* Paper presented at the 5th Asian Herpetological
1684 Conference, Chengdu, China.
1685 Gholamifard, A., Rastegar Pouayni, N., & Esmaeili, H. R., 2012. Annotated checklist of reptiles of Fars
1686 Province, southern Iran. Iran J Anim Biosyst. 8, 155-167.
1687 Ghorbanpur, M., Zare Mirakabadi, A., Zokaee, F., & Zolfagarrian, H., 2010. Identification and partial
1688 purification of an anticoagulant factor from the venom of the Iranian snake Agkistrodon halys. J
1689 Venom Anim Toxins Incl Trop Dis. 16, 96-106.
1690 Ghorbanpur, M., Zare Mirakabadi, A., Zokaee, F., Zolfagarrian, H., & Rabiei, H., 2009. Purification and
1691 partial characterization of a coagulant serine protease from the venom of the Iranian snake
1692 Agkistrodon halys. J Venom Anim Toxins Incl Trop Dis. 15, 411-423.
1693 Ghulikyan, L. A., Mohamadvarzi, M., Ghukasyan, G. V., Kishmiryan, A. V., Zaqaryan, N. A., Kirakosyan, G.
1694 R., & Ayvazyan, N. M., 2016. Molecular events associated with Vipera latifi venom effect on
1695 condition of human red blood cells. Proc Yerevan State Univ Chem Biol. 240, 43-50.
1696 Gillett, A. K., Flint, M., & Mills, P. C., 2014. An antemortem guide for the assessment of stranded
1697 Australian sea snakes (Hydrophiinae). J Zoo Wildl Med. 45, 755-765.
1698 Gitter, S., Moroz-Perlmutter, C., Boss, J. H., Livni, E., Rechnic, J., Goldblum, N., & De Vries, A., 1962.
1699 Studies on the snake venoms of the near east: Walterinnesia aegyptia and Pseudocerastes
1700 fieldii. Am J Trop Med Hyg. 11, 861-868.
1701 Gold, B. S., Dart, R. C., & Barish, R. A., 2002. Bites of venomous snakes. N Engl J Med. 347, 347-356.
1702 Gonzales, D., 1978. Contribution to the clinical and epidemiological aspects of snake bites in Spain.
1703 Period Biol. 80, 135-139.

1704 Greene, S., Cheng, D., Vilke, G. M., & Winkler, G., 2021. How Should Native Crotalid Envenomation Be
1705 Managed in the Emergency Department? J Emerg Med. 61, 41-48.
1706 Guibé, J., 1957. Reptiles from Iran collected by Mr. Francis Petter. Description of a new Viperidae:
1707 Pseudocerastes latirostris, n. sp [In French]. Bull Mus Natl Hist. 29, 136-143.
1708 Gutierrez, J. M., 2018. Antivenoms: Life-saving drugs for envenomings by animal bites and stings.
1709 Toxicon. 150, 11-12.
1710 Gutierrez, J. M., Calvete, J. J., Habib, A. G., Harrison, R. A., Williams, D. J., & Warrell, D. A., 2017.
1711 Snakebite envenoming. Nat Rev Dis Primers. 3, 17063.
1712 Hafezi, G., Rahmani, A. H., Soleymani, M., & Nazari, P., 2018. An Epidemiologic and Clinical Study of
1713 Snake Bites during a Five-Year Period in Karoon, Iran. Asia Pac J Med Toxicol. 7, 13-16.
1714 Hajialiani, F., Elmi, T., Mohamadi, M., Sadeghi, S., Shahbazzadeh, D., Ghaffarifar, F., . . . Zamani, Z., 2020.
1715 Analysis of the active fraction of Iranian Naja naja oxiana snake venom on the metabolite
1716 profiles of the malaria parasite by (1)HNMR in vitro. Iran J Basic Med Sci. 23, 534-543.
1717 Hamza, L., Gargioli, C., Castelli, S., Rufini, S., & Laraba-Djebari, F., 2010. Purification and characterization
1718 of a fibrinogenolytic and hemorrhagic metalloproteinase isolated from Vipera lebetina venom.
1719 Biochimie. 92, 797-805.
1720 Harvey, A. L., Barfaraz, A., Thomson, E., Faiz, A., Preston, S., & Harris, J. B., 1994. Screening of snake
1721 venoms for neurotoxic and myotoxic effects using simple in vitro preparations from rodents and
1722 chicks. Toxicon. 32, 257-265.
1723 Hassanian-Moghaddam, H., Monzavi, S. M., Shirazi, F. M., Warrell, D. A., & Mehrpour, O., 2022. First
1724 report of a confirmed case of Montivipera latifii (Latifi's viper) envenoming and a literature
1725 review of envenoming by Montivipera species. Toxicon. 207, 48-51.
1726 Heiner, J. D., Bebarta, V. S., Varney, S. M., Bothwell, J. D., & Cronin, A. J., 2013. Clinical Effects and
1727 Antivenom Use for Snake Bite Victims Treated at Three US Hospitals in Afghanistan. Wilderness
1728 Environ Med. 24, 412-416.
1729 Hempel, B. F., Damm, M., Gocmen, B., Karis, M., Oguz, M. A., Nalbantsoy, A., & Sussmuth, R. D., 2018.
1730 Comparative Venomics of the Vipera ammodytes transcaucasiana and Vipera ammodytes
1731 montandoni from Turkey Provides Insights into Kinship. Toxins (Basel). 10, 23.
1732 Heydari Sereshk, Z., & Riyahi Bakhtiari, A., 2014. Distribution patterns of PAHs in different tissues of
1733 annulated sea snake (Hydrophis cyanocinctus) and short sea snake (Lapemis curtus) from the
1734 Hara Protected Area on the North Coast of the Persian Gulf, Iran. Ecotoxicol Environ Saf. 109,
1735 116-123.
1736 Höggren, M., Nilson, G., Andrén, C., Orlov, N. L., & Tuniyev, B. S., 1993. Vipers of the Caucasus: natural
1737 history and systematic review. Herpetol Nat Hist. 1, 11-19.
1738 Hosseinian Yousefkhani, S. S., Yousefi, M., Khani, A., & Rsategar-Pouyani, E., 2014. Snake fauna of
1739 Shirahmad wildlife refuge and Parvand protected area, Khorasan Razavi province, Iran. Herpetol
1740 Notes. 7, 75-82.
1741 Hosseinzadeh, M. S., Aliabadian, M., Rastegar-Pouyani, E., & Rastegar-Pouyani, N., 2014. The roles of
1742 environmental factors on reptile richness in Iran. Amphibia-Reptilia. 35, 215-225.
1743 Ibrahim, A. M., ElSefi, T. T., Ghanem, M., Fayed, A. M., & Shaban, N. A., 2017. A Horned Viper Bite Victim
1744 with PRES. Case Rep Neurol Med. 2017, 1835796.
1745 IFDA. (2021, Jan 4). Iran Essential Medicine List. 2nd ed. Tehran, Iran: Iranian Food & Drug
1746 Administration. Retrieved from: https://www.fda.gov.ir/getattachment/c1d15ec6-a2b8-4804-
1747 9c33-739e28d12e75
1748 Igci, N., & Demiralp, D. O., 2012. A preliminary investigation into the venom proteome of Macrovipera
1749 lebetina obtusa (Dwigubsky, 1832) from Southeastern Anatolia by MALDI-TOF mass
1750 spectrometry and comparison of venom protein profiles with Macrovipera lebetina lebetina
1751 (Linnaeus, 1758) from Cyprus by 2D-PAGE. Arch Toxicol. 86, 441-451.

Ineich, I., Girard, F., & Weinstein, S. A., 2020. Local envenoming by the Schokari sand racer, Psammophis schokari Forskal, 1775 (Serpentes, Psammophiidae) and a brief review of reported bites by sand racers (Psammophis spp.). Toxicon. 185, 72-75.

Isbister, G. K., Brown, S. G., Page, C. B., McCoubrie, D. L., Greene, S. L., & Buckley, N. A., 2013. Snakebite in Australia: a practical approach to diagnosis and treatment. Med J Aust. 199, 763-768.

Ishunin, G. I., 1950. Case of envenoming by a non-venomous snake. [In Russian]. Izv Akad Nauk Uzb SSR. 6, 93-95.

Jalali, A., Savari, M., Dehdardargahi, S., & Azarpanah, A., 2012. The pattern of poisoning in southwestern region of iran: envenoming as the major cause. Jundishapur J Nat Pharm Prod. 7, 100-105.

Javani Jouni, F., Zafari, J., Shams, E., Abdolmaleki, P., & Rastegari, A. A., 2022. Evaluation of Anti-Cancer Effects of Caspian Cobra (Naja naja oxiana) Snake Venom in Comparison with Doxorubicin in HeLa Cancer Cell Line and Normal HFF Fibroblast. [In Persian]. J Ilam Univ Med Sci. 29, 20-27.

Jayne, W. A., 1919. The Medical Gods of Ancient Iran. Ann Med Hist. 2, 8-13.

Jimenez-Cazalla, F. (2012). Malpolon insignitus (Geoffroy Saint-Hilaire, 1827). In: Martínez, G., León, R., Jiménez-Robles, O., González De la Vega, J. P., Gabari, V., Rebollo, B., Sánchez-Tójar, A., Fernández-Cardenete, J. R., Gállego, J. (Eds.). Moroccoherps. Amphibians and Reptiles of Morocco and Western Sahara. Retrieved from: http://www.moroccoherps.com/en/ficha/Malpolon_insignitus/

Joger, U. (1984). *The venomous snakes of the Near and Middle East*. Wiesbaden, Germany: Reichert Verlag.

Johnston, C. I., Ryan, N. M., Page, C. B., Buckley, N. A., Brown, S. G., O'Leary, M. A., & Isbister, G. K., 2017. The Australian Snakebite Project, 2005-2015 (ASP-20). Med J Aust. 207, 119-125.

Jowkar, H., Ostrowski, S., Tahbaz, M., & Zahler, P., 2016. The Conservation of Biodiversity in Iran: Threats, Challenges and Hopes. Iran Stud. 49, 1065-1077.

Junqueira-de-Azevedo, I. L., Campos, P. F., Ching, A. T., & Mackessy, S. P., 2016. Colubrid Venom Composition: An -Omics Perspective. Toxins (Basel). 8, 230.

Kadkhodazadeh, M., Rajabibazl, M., Motedayen, M., Shahidi, S., Veisi Malekshahi, Z., Rahimpour, A., & Yarahmadi, M., 2020. Isolation of Polyclonal Single-Chain Fragment Variable (scFv) Antibodies Against Venomous Snakes of Iran and Evaluation of Their Capability in Neutralizing the Venom. Iran J Pharm Res. 19, 288-296.

Kakanj, M., Ghazi-Khansari, M., Zare Mirakabadi, A., Daraei, B., & Vatanpour, H., 2015. Cytotoxic Effect of Iranian Vipera lebetina Snake Venom on HUVEC Cells. Iran J Pharm Res. 14, 109-114.

Kamyab, M., Kim, E., Hoseiny, S. M., & Seyedian, R., 2017. Enzymatic Analysis of Iranian Echis carinatus Venom Using Zymography. Iran J Pharm Res. 16, 1155-1160.

Karabuva, S., Vrkic, I., Brizic, I., Ivic, I., & Luksic, B., 2016. Venomous snakebites in children in southern Croatia. Toxicon. 112, 8-15.

Kassiri, H., Khodkar, I., Kazemi, S., Kasiri, N., & Lotfi, M., 2019. Epidemiological analysis of snakebite victims in southwestern Iran. J Acute Dis. 8, 260-264.

Kasturiratne, A., Wickremasinghe, A. R., de Silva, N., Gunawardena, N. K., Pathmeswaran, A., Premaratna, R., . . . de Silva, H. J., 2008. The global burden of snakebite: a literature analysis and modelling based on regional estimates of envenoming and deaths. PLoS Med. 5, e218.

Kaviani Pooya, H., 2010. Medicine and Evolution of Treatment in Ancient Iran. [In Persian]. J Med Hist. 2, 67-98.

Kazemi-Lomedasht, F., Yamabhai, M., Sabatier, J. M., Behdani, M., Zareinejad, M. R., & Shahbazzadeh, D., 2019. Development of a human scFv antibody targeting the lethal Iranian cobra (Naja oxiana) snake venom. Toxicon. 171, 78-85.

Kazemi, E., Kaboli, M., & Khorasani, N., 2021a. Genetic diversity of Naja oxiana (Eichwald, 1831) populations in Iran using cytochrome b mitochondrial marker. [In Persian]. J Anim Environ. 13, 197-206.

Kazemi, E., Nazarizadeh, M., Fatemizadeh, F., Khani, A., & Kaboli, M., 2021b. The phylogeny, phylogeography, and diversification history of the westernmost Asian cobra (Serpentes: Elapidae: Naja oxiana) in the Trans-Caspian region. Ecol Evol. 11, 2024-2039.

Kazemi Shishavan, M., & Maleki, R., 2018. Comparative Study of Symbol: Iranian Contemporary Architecture and Seljuk (Case Study:Tombes) Int J Archit Urban Dev. 8, 33-50.

Kazemi, S. M., Al-Sabi, A., Long, C., Shoulkamy, M. I., & Abd El-Aziz, T. M., 2021c. Case Report: Recent Case Reports of Levant Blunt-Nosed Viper Macrovipera lebetina obtusa Snakebites in Iran. Am J Trop Med Hyg. 104, 1870-1876.

Kazemi, S. M., Jahan-Mahin, M. H., Mohammadian-Kalat, T., Hosseinzadeh, M. S., & Weinstein, S. A., 2023a. Local envenoming by the coinsnake or Asian racer, Hemorrhois nummifer and mountain racer or leopard snake, Hemorrhois ravergieri (Serpentes: Colubridae, Colubrinae) in Iran: A reminder of the importance of species identification in the medical management of snakebites. Toxicon. 226, 107070.

Kazemi, S. M., Jahan-Mahin, M. H., Zangi, B., Khozani, R. S., & Warrell, D. A., 2023b. A case of envenoming by a Persian false-horned viper Pseudocerastes persicus (Duméril, Bibron & Duméril, 1854) (Serpentes: Viperidae) in Southeastern Iran. Toxicon. 223, 107009.

Kelly, C. M. R., Barker, N. P., Villet, M. H., & Broadley, D. G., 2009. Phylogeny, biogeography and classification of the snake superfamily Elapoidea: a rapid radiation in the late Eocene. Cladistics. 25, 38-63.

Khadem-Rezaiyan, M., Moallem, S. R., & Afshari, R., 2018. Epidemiology of Snake, Spider and Scorpion Envenomation in Mashhad, Khorasan Razavi, Iran (2004-2011). Iran J Toxicol. 12, 27-31.

Khan, S. U., & Al-Saleh, S. S., 2015. Biochemical characterization of a factor X activator protein purified from Walterinnesia aegyptia venom. Blood Coagul Fibrinolysis. 26, 772-777.

Khani, S., Kami, H., & Rajabizadeh, M., 2017. Geographic variation of Gloydius halys caucasicus (Serpentes: Viperidae) in Iran. Zool Middle East. 63, 303-310.

Khosravani, M., Mohebbi Nodez, S. M., Rafatpanah, A., Mosalla, S., & Fekri, S., 2018. The first study of snake and scorpion envenomation in Qeshm Island, South of Iran. J Entomol Zool Stud. 6, 982-987.

Khosrojerdi, H., & Amini, M., 2013. Acute and delayed stress symptoms following snakebite. Asia Pac J Med Toxicol. 2, 140-144.

Kirakosyan, G., Mohamadvarzi, M., Ghulikyan, L., Zaqaryan, N., Kishmiryan, A., & Ayvazyan, N., 2016. Morphological and functional alteration of erythrocyte ghosts and giant unilamellar vesicles caused by Vipera latifi venom. Comp Biochem Physiol C Toxicol Pharmacol. 190, 48-53.

Kochar, D. K., Tanwar, P. D., Norris, R. L., Sabir, M., Nayak, K. C., Agrawal, T. D., . . . Simpson, I. D., 2007. Rediscovery of severe saw-scaled viper (Echis sochureki) envenoming in the Thar desert region of Rajasthan, India. Wilderness Environ Med. 18, 75-85.

Kochva, E. (1990). Venomous snakes of Israel. In: P. Gopalkrishnakone & L. M. Chou (Eds.), *Snakes of Medical Importance (Asia-Pacific region)* (pp. 311-321). Singapore, Singapore: Venom and Toxin Group, National University of Singapore.

Kocourek, I., 1990. Beware of Coluber snakes! [In Croatian]. ŽIVA (Journal of Czechoslovakian Academy of Sciences). 38, 130.

Kuch, U., & Mebs, D., 2002. Envenomations by Colubrid Snakes in Africa, Europe, and the Middle East. J Toxicol Toxin Rev. 21, 159-179.

Kudriavtsev, S. V., 1983. Verified case of poisoning with the venom of the Central Asian cobra (Naja oxiana Eichw., 1831). [In Russian]. Ter Arkh. 55, 113-114.

1846 Kukushkin, O., Iskenderov, T., Bunyatova, S., & Zinenko, O., 2012. Additions to the distribution of Vipera
1847 eriwanensis (Serpentes: Viperidae) in Transcaucasia, with comments on the identity of vipers in
1848 northeastern Azerbaijan. Herpetol Notes. 5, 423-427.
1849 Kularatne, S. A., 2002. Common krait (Bungarus caeruleus) bite in Anuradhapura, Sri Lanka: a
1850 prospective clinical study, 1996-98. Postgrad Med J. 78, 276-280.
1851 Kumlutas, Y., Ilgaz, C., & Candan, K., 2015. Westernmost record of Montivipera wagneri (NILSON &
1852 ANDREN, 1984). Herpetozoa. 28, 98-101.
1853 Kurtovic, T., Lang Balija, M., Ayvazyan, N., & Halassy, B., 2014. Paraspecificity of Vipera a. ammodytes-
1854 specific antivenom towards Montivipera raddei and Macrovipera lebetina obtusa venoms.
1855 Toxicon. 78, 103-112.
1856 Latifi, M., 1984. Variation in yield and lethality of venoms from Iranian snakes. Toxicon. 22, 373-380.
1857 Latifi, M. (1985). *Snakes of Iran. [In Persian]*. Tehran, Iran: Iranian Department of Environment.
1858 Latifi, M. (1991). *Snakes of Iran (English translated version)*. Oxford, Ohio: Society for the Study of
1859 Amphibians and Reptiles.
1860 Latifi, M., R., H. A., & Eliazan, M., 1966. The Poisonous Snakes of Iran. Mem Inst Butantan Simp Internac.
1861 33, 735-744.
1862 Latifi, M., & Tabatabai, M., 1989. Studies on Echis carinatus venoms and antivenoms of different
1863 countries. Arch Razi Inst. 40, 97-105.
1864 Lauer, C., Zickgraf, T. L., & Weisse, M. E., 2011. Case report of probable desert black snake
1865 envenomation in 22-year-old male causing profound weakness and respiratory distress.
1866 Wilderness Environ Med. 22, 246-249.
1867 Lavonas, E. J., Ruha, A. M., Banner, W., Bebarta, V., Bernstein, J. N., Bush, S. P., . . . Hospital, A., 2011.
1868 Unified treatment algorithm for the management of crotaline snakebite in the United States:
1869 results of an evidence-informed consensus workshop. BMC Emerg Med. 11, 2.
1870 Lewis, R. L., & Gutmann, L., 2004. Snake venoms and the neuromuscular junction. Semin Neurol. 24,
1871 175-179.
1872 Liapis, K., Charitaki, E., & Psaroulaki, A., 2019. Case Report: Spherocytic Hemolytic Anemia after
1873 Envenomation by Long-Nosed Viper (Vipera ammodytes). Am J Trop Med Hyg. 101, 1442-1445.
1874 Lifshitz, M., Maimon, N., & Livnat, S., 2003. Walterinnesia aegyptia envenomation in a 22-year-old
1875 female: a case report. Toxicon. 41, 535-537.
1876 Lillywhite, H. B., Sheehy, C. M., 3rd, Brischoux, F., & Grech, A., 2014. Pelagic sea snakes dehydrate at sea.
1877 Proc Biol Sci. 281, 20140119.
1878 Logonder, U., Krizaj, I., Rowan, E. G., & Harris, J. B., 2008. Neurotoxicity of ammodytoxin a in the
1879 envenoming bites of Vipera ammodytes ammodytes. J Neuropathol Exp Neurol. 67, 1011-1019.
1880 Lomonte, B., Pla, D., Sasa, M., Tsai, W. C., Solorzano, A., Urena-Diaz, J. M., . . . Calvete, J. J., 2014. Two
1881 color morphs of the pelagic yellow-bellied sea snake, Pelamis platura, from different locations of
1882 Costa Rica: snake venomics, toxicity, and neutralization by antivenom. J Proteomics. 103, 137-
1883 152.
1884 Lumsden, N. G., Fry, B. G., Manjunatha Kini, R., & Hodgson, W. C., 2004. In vitro neuromuscular activity
1885 of 'colubrid' venoms: clinical and evolutionary implications. Toxicon. 43, 819-827.
1886 Mackessy, S. P., 2002. Biochemistry and pharmacology of colubrid snake venoms. J Toxicol Toxin Rev.
1887 21, 43-83.
1888 Madani, R., Razavi, S. M., & Golchinfar, F., 2018. Determination of thelethal dose (LD50) and the
1889 effective dose (ED50) of Iranian horned viper venom. [In Persian]. Vet Res Biol Prod. 31, 70-76.
1890 Malekara, E., Pazhouhi, M., Rashidi, I., & Jalili, C., 2020. Anti-proliferative and cytotoxic effect of Iranian
1891 snake (Vipera raddei kurdistanica) venom on human breast cancer cells via reactive oxygen
1892 species-mediated apoptosis. Res Pharm Sci. 15, 76-86.

Malekoutian, M., Karamiani, R., & Rastegar-Pouyani, N., 2018. Study of Snake Fauna of Kangavar County, Kermanshah Province. [In Persian]. J Environ Sci Technol. 20, 257-264.

Malik, G. M., 1995. Snake bites in adults from the Asir region of southern Saudi Arabia. Am J Trop Med Hyg. 52, 314-317.

Mamonov, G., 1977. Case report of envenomation by the mountain racer Coluber ravergieri in USSR. The Snake. 9, 27-28.

Marinov, I., Atanasov, V. N., Stankova, E., Duhalov, D., Petrova, S., & Hubenova, A., 2010. Severe coagulopathy after Vipera ammodytes ammodytes snakebite in Bulgaria: a case report. Toxicon. 56, 1066-1069.

Mashhadi, I., Kavousi, Z., Peymani, P., Salman Zadeh Ramhormozi, S., & Keshavarz, K., 2017. Economic Burden of Scorpion Sting and Snake Bite from a Social Perspective in Iran. Shiraz E Med J. 18, e57573.

Massey, D. J., Calvete, J. J., Sanchez, E. E., Sanz, L., Richards, K., Curtis, R., & Boesen, K., 2012. Venom variability and envenoming severity outcomes of the Crotalus scutulatus scutulatus (Mojave rattlesnake) from Southern Arizona. J Proteomics. 75, 2576-2587.

McDiarmid, R. W., Campbell, J. A., & Touré, T. A. (1999). *Snake species of the world : a taxonomic and geographic reference*. Washington, DC: Herpetologists' League.

Mebert, K., Göçmen, B., Iğci, N., Karış, M., Oğuz, M. A., Yıldız, M. Z., . . . Ursenbacher, S., 2020. Mountain Vipers in Central-Eastern Turkey: Huge Range Extensions for Four Taxa Reshape Decades of Misleading Perspectives. Herpetol Conserv Biol. 15, 169-187.

Mehdizadeh Kashani, T., Vatanpour, H., Zolfagharian, H., Hooshdar Tehrani, H., Heydari, M. H., & Kobarfard, F., 2012. Partial Fractionation of Venoms from Two Iranian Vipers, Echis carinatus and Cerastes persicus Fieldi and Evaluation of Their Antiplatelet Activity. Iran J Pharm Res. 11, 1183-1189.

Mehrpour, O., Akbari, A., Nakhaee, S., Esmaeli, A., Mousavi Mirzaei, S. M., Ataei, H., & Amirabadizadeh, A., 2018. A case report of a patient with visual hallucinations following snakebite. J Surg Trauma. 6, 73-76.

Mehta, S. R., & Sashindran, V. K., 2002. Clinical Features and Management of Snake Bite. Med J Armed Forces India. 58, 247-249.

Meissner, A., Hausmann, B., Linn, C., Piepgras, P., Monig, H., Wronski, R., & Bruhn, H. D., 1989. Defibrination syndrome after snake bites. [In German]. Dtsch Med Wochenschr. 114, 1484-1487.

Mertens, R., 1965. The not well-known “sidewinders” of the Asian secret adders. [In German]. Natur und Museum Frankfurt a. M., 95, 346-352.

Minton, S. A., 1966. A contribution to the herpetology of West Pakistan. Bull Am Mus Nat Hist. 134, 27-184.

Minton, S. A., 1990. Venomous bites by nonvenomous snakes: an annotated bibliography of colubrid envenomation. J Wilderness Med. 1, 119-127.

Minton, S. A., Jr., 1967. Paraspecific protection by elapid and sea snake antivenins. Toxicon. 5, 47-55.

Mirtschin, P., Rasmussen, A., & Weinstein, S. (2018). *Australia's Dangerous Snakes: Identification, Biology and Envenoming* (1st ed.). Melbourne, Australia: CSIRO Publishing.

Mitel'man, L. S., 1966. Action of venom of the central Asian cobra (Naja oxiana eich.) on the blood-coagulating system. [In Russian]. Biull Eksp Biol Med. 62, 69-71.

Modahl, C. M., & Mackessy, S. P., 2019. Venoms of Rear-Fanged Snakes: New Proteins and Novel Activities. Front Ecol Evol. 7, 279.

Modahl, C. M., Saviola, A. J., & Mackessy, S. P. (2016). Venoms of Colubrids. In *Venom Genomics and Proteomics* (pp. 51-79). Dordrecht, Netherlands: Springer.

1940 Mohammad Alizadeh, A., Hassanian-Moghaddam, H., Zamani, N., Rahimi, M., Mashayekhian, M.,
1941 Hashemi Domeneh, B., . . . Ostadi, A., 2016. The Protocol of Choice for Treatment of Snake Bite.
1942 Adv Med. 2016, 7579069.
1943 Mohebbi, G., Seyedian, R., & Nabipour, I., 2016. The toxinology of sea snakes: A systematic review. [In
1944 Persian]. Iran South Med J. 19, 662-703.
1945 Mondal, R. N., Chowdhury, F. R., Rani, M., Mohammad, N., Islam, M. M., Haque, M. A., & Faiz, M. A.,
1946 2012. Pre-Hospital and Hospital Management Practices and Circumstances behind Venomous
1947 Snakebite in Northwestern Part of Bangladesh. Asia Pac J Med Toxicol. 1, 18-21.
1948 Monzavi, S. M., Afshari, R., Khoshdel, A. R., Mahmoudi, M., Salarian, A. A., Samieimanesh, F., . . .
1949 Mihandoust, A., 2019a. Analysis of effectiveness of Iranian snake antivenom on Viper venom
1950 induced effects including analysis of immunologic biomarkers in the Echis carinatus sochureki
1951 envenomed victims. Toxicon. 158, 38-46.
1952 Monzavi, S. M., Afshari, R., Khoshdel, A. R., Salarian, A. A., Khosrojerdi, H., & Mihandoust, A., 2019b.
1953 Interspecies Variations in Clinical Envenoming Effects of Viper Snakes Evolutionized in a
1954 Common Habitat: A Comparative Study on Echis carinatus sochureki and Macrovipera lebetina
1955 obtusa Victims in Iran. Asia Pac J Med Toxicol. 8, 107-114.
1956 Monzavi, S. M., Dadpour, B., & Afshari, R., 2014. Snakebite management in Iran: Devising a protocol. J
1957 Res Med Sci. 19, 153-163.
1958 Monzavi, S. M., Salarian, A. A., Khoshdel, A. R., Dadpour, B., & Afshari, R., 2015. Effectiveness of a clinical
1959 protocol implemented to standardize snakebite management in Iran: initial evaluation.
1960 Wilderness Environ Med. 26, 115-123.
1961 Moradi, N., Rastegar-Pouyani, N., & Rastegar-Pouyani, E., 2014. Geographic variation in the morphology
1962 of Macrovipera lebetina (Linnaeus, 1758) (Ophidia: Viperidae) in Iran. Acta Herpetol. 9, 187-202.
1963 Moradi, N., Shafiei, S., & Sehhatisabet, M. E., 2013. The snake fauna of Khabr National Park, southeast of
1964 Iran. Iran J Anim Biosyst. 9, 41-55.
1965 Moradi, S. H., Rastegar Pouyani, E., Hosseinian, S., & Zargan, J., 2021. Evaluation ecological niche
1966 between Platyceps rhodorachis and P. karelini (Serpentes: Colubridae) in Iran. Iran J Anim
1967 Biosyst. 17, 147-155.
1968 Moradiasl, E., Adham, D., Mirzanejadasl, H., Eghbali, H., Solimanzadeh, H., Rafinejad, J., . . . Akbarzadeh,
1969 T., 2018. Spatial Analysis of Snakebites in Ardabil Province Using GIS during 2011-2015. [In
1970 Persian]. J Safe Prom Injury Prev. 6, 81-86.
1971 Moridikia, A., Zargan, J., Sobati, H., Goodarzi, H. R., & Hajinourmohamadi, A., 2018. Anticancer and
1972 antibacterial effects of Iranian viper (Vipera latifii) venom; an in-vitro study. J Cell Physiol. 233,
1973 6790-6797.
1974 Moshtaghie, M., Kaboli, M., & Salehi, M., 2018. Investigating the morphological changes of Hemorrhois
1975 ravergieri (Reptilia: Ophidia: Colubridae) in Iran. [In Persian]. J Anim Environ. 10, 87-96.
1976 Motedayen, M. H., Nikbakht Brujeni, G., Rasaee, M. J., Zare Mirakabadi, A., Khorasani, A., Eizadi, H., . . .
1977 Esmaeilzad, M., 2018. Production of a Human Recombinant Polyclonal Fab Antivenom against
1978 Iranian Viper Echis carinatus. Arch Razi Inst. 73, 287-294.
1979 Mozaffari, O., Kamali, K., & Fahimi, H. (2016). *The Atlas of Reptiles of Iran. [In Persian]*. Tehran, Iran:
1980 Iranian Department of Environment.
1981 Mülder, J., 2017. A review of the distribution of Vipera ammodytes transcaucasiana Boulenger, 1913
1982 (Serpentes: Viperidae) in Turkey. Biharean Biol. 11, 23-26.
1983 Nabipour, I. (2012). *The venomous animals of the Persian Gulf. [In Persian]*. Bushehr, Iran: Bushehr
1984 University of Medical Sciences Press.
1985 Nabipour, I., Khoshdel, A. R., Golaghaei, A. R., Tashakori Beheshti, A., & Afshari, R., 2015. Clinico-
1986 epidemiologic Study on Marine Envenomations and Injuries in South Iran, Persian Gulf Coasts.
1987 Asia Pac J Med Toxicol. 4, 112-115.

Naik, B. S., 2017. "Dry bite" in venomous snakes: A review. Toxicon. 133, 63-67.
Najmabadi, M. (1992). *History of Medicine in Iran. [In Persian]*. Tehran, Iran: University of Tehran Press.
Nalbantsoy, A., İgci, N., Gocmen, B., & Mebert, K., 2016. Cytotoxic potential of Wagner's Viper, Montivipera wagneri, venom. North-West J Zool. 12, 286-291.
Nasiripour, A., Ranjbar, B., Naderimanesh, H., Mehrnezhad, F., Soufian, S., Sadeghi, G., & Kolahian, S., 2008. Structural-Functional Studies of Peptides Derived from a Long-Chain Snake Neurotoxin Naja Naja Oxiana. [In Persian]. Physiol Pharmacol. 12, 209-220.
Nasrabadi, R., Rastegar-Pouyani, E., Hosseinian Yousefkhani, S., & Khani, A., 2016. A checklist of herpetofauna from Sabzevar, Northeastern Iran. Iran J Anim Biosyst. 12, 255-259.
Nasri Nasrabadi, N., Mohammadpour Dounighi, N., Ahmadinejad, M., Rabiei, H., Tabarzad, M., Najafi, M., & Vatanpour, H., 2022. Isolation of the Anticoagulant and Procoagulant Fractions of the Venom of Iranian Endemic Echis carinatus. Iran J Pharm Res. 21, e127240.
Navidpour, S., Salemi, A., & Zare Mirakabadi, A., 2019. First Case Report of an Unusual Echis genus (Squamata: Ophidia: Viperidae) Body Pattern Design in Iran. Arch Razi Inst. 74, 197-202.
Nayernouri, T., 2015. A Brief History of Ancient Iranian Medicine. Arch Iran Med. 18, 549-551.
Nazari, A., Samianifard, M., Rabie, H., & Mirakabadi, A. Z., 2020. Recombinant antibodies against Iranian cobra venom as a new emerging therapy by phage display technology. J Venom Anim Toxins Incl Trop Dis. 26, e20190099.
Nejadrahim, R., Sahranavard, M., Aminizadeh, A., & Delirrad, M., 2019. Snake Envenomation in North-West Iran: A Three-Year Clinical Study. Int J Med Toxicol Forensic Med. 9, 31-38.
Nikolić, S., Antić, M., Pavić, A., Ajtić, R., & Pavić, S., 2021. Analysis of the venomous snakebite patients treated in the Užice General Hospital (Western Serbia) between 2006 and 2018. Srp Arh Celok Lek. 149, 189-195.
Nilson, G., & Andrén, C., 1984. Systematics of the Vipera xanthina complex (Reptilia: Viperidae). II. An overlooked viper within the xanthina species-group in Iran. Bonn Zool Beitr. 35, 175.
Nilson, G., & Rastegar-Pouyani, N., 2007. Walterinnesia aegyptia Lataste, 1887 (Ophidia: Elapidae) and the status of Naja morgani Mocquard 1905. Russ J Herpetol. 14, 7-14.
Nilson, G., & Rastegar-Pouyani, N., 2013. The occurence of Telescopus nigriceps (Ahl, 1924) in western Iran, with comments on the Genus Telescopus (Serpentes: Colubridae). Zool Middle East. 59, 131-135.
Nilson, G., Tuniyev, B., Andrén, C., & Orlov, N., 1999. Vipers of Caucasus: taxonomic considerations. Kaupia. 8, 103-106.
Nodooshan, M. M., Sobati, H., Malekara, E., Goodarzi, H. R., Ebrahimi, F., Normohamadi, A., & Zargan, J., 2021. Crude venom of Pseudocerastes persicus snake: From the antibacterial to anticancer effects. Rom J Mil Med. 124.
Oghabian, Z., Ebrahimi, F., Farhadpour, S., Shojaeepour, S., & Dehghani, R., 2022. Clinical Manifestations of Snakebite Patients Referred to Afzalipour Hospital in Kerman - Southeastern Iran. Asia Pac J Med Toxicol. 11, 146-151.
Oghalaie, A., Kazemi-Lomedasht, F., Zareinejad, M. R., & Shahbazzadeh, D., 2017. Antiadhesive and cytotoxic effect of Iranian Vipera lebetina snake venom on lung epithelial cancer cells. J Family Med Prim Care. 6, 780-783.
Oh, A. M. F., Tan, C. H., Tan, K. Y., Quraishi, N. H., & Tan, N. H., 2019. Venom proteome of Bungarus sindanus (Sind krait) from Pakistan and in vivo cross-neutralization of toxicity using an Indian polyvalent antivenom. J Proteomics. 193, 243-254.
Op den Brouw, B., Coimbra, F. C. P., Bourke, L. A., Huynh, T. M., Vlecken, D. H. W., Ghezellou, P., . . . Fry, B. G., 2021a. Extensive Variation in the Activities of Pseudocerastes and Eristicophis Viper Venoms Suggests Divergent Envenoming Strategies Are Used for Prey Capture. Toxins (Basel). 13, 112.

2036 Op den Brouw, B., Ghezellou, P., Casewell, N. R., Ali, S. A., Fathinia, B., Fry, B. G., . . . Ikonomopoulou, M.
2037 P., 2021b. Pharmacological Characterisation of Pseudocerastes and Eristicophis Viper Venoms
2038 Reveal Anticancer (Melanoma) Properties and a Potentially Novel Mode of Fibrinogenolysis. Int J
2039 Mol Sci. 22, 6896.
2040 Oraie, H., 2020. Genetic evidence for occurrence of Macrovipera razii (Squamata, Viperidae) in the
2041 central Zagros region, Iran. Herpetozoa. 33, 27.
2042 Oraie, H., Rastegar-Pouyani, E., Khosravani, A., Moradi, N., Akbari, A., Sehhatisabet, M. E., . . . Joger, U.,
2043 2018. Molecular and morphological analyses have revealed a new species of blunt-nosed viper
2044 of the genus Macrovipera in Iran. Salamandra. 54, 233-248.
2045 Papenfuss, T., Shafiei Bafti, S., & Nilson, G. (2021). *Eristicophis macmahoni. The IUCN Red List of*
2046 *Threatened Species 2021: e.T164709A1070000*. Retrieved from
2047 Patikorn, C., Blessmann, J., Nwe, M. T., Tiglao, P. J. G., Vasaruchapong, T., Maharani, T., . . .
2048 Chaiyakunapruk, N., 2022. Estimating economic and disease burden of snakebite in ASEAN
2049 countries using a decision analytic model. PLoS Negl Trop Dis. 16, e0010775.
2050 Patra, A., Chanda, A., & Mukherjee, A. K., 2019. Quantitative proteomic analysis of venom from
2051 Southern India common krait (Bungarus caeruleus) and identification of poorly immunogenic
2052 toxins by immune-profiling against commercial antivenom. Expert Rev Proteomics. 16, 457-469.
2053 Perry, G., 1988. Mild toxic effects resulting from the bites of Jan's desert racer, Coluber rhodorachis, and
2054 Moila's snake, Malpolon moilensis (Ophidia: Colubridae). Toxicon. 26, 523-524.
2055 Pillai, L. V., Ambike, D., Husainy, S., Khaire, A., Captain, A., & Kuch, U., 2012. Severe Neurotoxic
2056 Envenoming and Cardiac Complications after the Bite of a 'Sind Krait' (Bungarus cf. sindanus) in
2057 Maharashtra, India. Trop Med Health. 40, 103-108.
2058 Pla, D., Quesada-Bernat, S., Rodriguez, Y., Sanchez, A., Vargas, M., Villalta, M., . . . Calvete, J. J., 2020.
2059 Dagestan blunt-nosed viper, Macrovipera lebetina obtusa (Dwigubsky, 1832), venom. Venomics,
2060 antivenomics, and neutralization assays of the lethal and toxic venom activities by anti-
2061 Macrovipera lebetina turanica and anti-Vipera berus berus antivenoms. Toxicon X. 6, 100035.
2062 Pommier, P., & de Haro, L., 2007. Envenomation by Montpellier snake (Malpolon monspessulanus) with
2063 cranial nerve disturbances. Toxicon. 50, 868-869.
2064 Pook, C. E., Joger, U., Stumpel, N., & Wuster, W., 2009. When continents collide: phylogeny, historical
2065 biogeography and systematics of the medically important viper genus Echis (Squamata:
2066 Serpentes: Viperidae). Mol Phylogenet Evol. 53, 792-807.
2067 Pymm, R. (2017). Serpent Stones: Myth and Medical Application. In: C. J. Duffin, C. Gardner-Thorpe, & R.
2068 T. J. Moody (Eds.), *Geology and Medicine: Historical Connections* (pp. 163-180). Bath, UK: The
2069 Geological Society Publishing House.
2070 Pyron, R. A., Burbrink, F. T., & Wiens, J. J., 2013. A phylogeny and revised classification of Squamata,
2071 including 4161 species of lizards and snakes. BMC Evol Biol. 13, 93.
2072 Rahmani, A. H., Hazrati, B., & Alidadi, H., 2022. Evaluation of the frequency of shaldon's catheter
2073 complications in the hemodialysis patients in Ahvaz Razi hospital. Asia Pac J Med Toxicol. 11, 58-
2074 61.
2075 Rahmani, A. H., Jalali, A., Alemzadeh-Ansari, M. H., Tafazoli, M., & Rahim, F., 2014. Dosage comparison
2076 of snake anti-venomon coagulopathy. Iran J Pharm Res. 13, 283-289.
2077 Rajabi, M., Dadpour, B., Rahimi, P., & Moshiri, M., 2022. Rapid progressive course of naja naja oxiana-
2078 bitten patient. J Kerman Univ Med Sci. 29, 79-83.
2079 Rajabizadeh, M. (2013). *Biodiversity of the snakes in northern and western mountains of Iran, with*
2080 *special emphasis on biodiversity in colubroids (Doctoral dissertation).* Ghent University, Ghent,
2081 Belgium.
2082 Rajabizadeh, M. (2018). *Snakes of Iran. [In Persian]*. Tehran, Iran: Iranshensai Publishing.

Rajabizadeh, M., Nilson, G., & Kami, H. G., 2011a. A new species of mountain viper (Ophidia: Viperidae) from the Central Zagros Mountains, Iran. Russ J Herpetol. 18, 235-240.

Rajabizadeh, M., Nilson, G., Kami, H. G., & Naderi, A. R., 2011b. Distribution of the subgenus Acridophaga Reuss, 1927 (Serpentes: Viperidae) in Iran. Iran J Anim Biosyst. 7, 83-87.

Rajabizadeh, M., & Rezghi, M., 2021. A comparative study on image-based snake identification using machine learning. Sci Rep. 11, 19142.

Rajabizadeh, M., Yazdanpanah, A., & Ursenbacher, S., 2012. Preliminary analysis of dorsal pattern variation and sexual dimorphism in Montivipera latifii (Mertens, Darevsky and Klemmer, 1967) (Ophidia: Viperidae). Acta Herpetol. 7, 13-21.

Ramezani, M., Kami, H., & Ahmadpanah, N., 2011. Faunistic studies on snakes of West Golestan state. Proc Soc Behav Sci. 19, 811-817.

Rasmi, A., 2016. Contribution of Persian culture to origination of medicine symbol. [In Persian]. Med Hist J. 4, 33-67.

Rasouli, M. R., Saadat, S., Haddadi, M., Gooya, M. M., Afsari, M., & Rahimi-Movaghar, V., 2011. Epidemiology of injuries and poisonings in emergency departments in Iran. Public Health. 125, 727-733.

Rasoulinasab, F., Rasoulinasab, M., Shahbazzadeh, D., Asadi, A., & Kaboli, M., 2020. Comparison of venom from wild and long-term captive Gloydius caucasicus and the neutralization capacity of antivenom produced in rabbits immunized with captive venom. Heliyon. 6, e05717.

Rastegar-Pouyani, E., Oraie, H., Khosravani, A., Kaboli, M., Mobaraki, A., Yousefi, M., . . . Wink, M., 2014. A re-evaluation of taxonomic status of Montivipera (Squamata: Viperidae) from Iran using a DNA barcoding approach. Biochem Syst Ecol. 57, 350-356.

Rastegar-Pouyani, N., Gholamifard, A., Karamiani, R., Bahmani, Z., Mobaraki, A., Abtin, E., . . . Sayyadi, F., 2015. Sustainable Management of the Herpetofauna of the Iranian Plateau and Coastal Iran. Amphib Reptile Conserv. 9, 1-15.

Rastegar-Pouyani, N., Kami, H. G., Rajabzadeh, H. R., Shafiei, S., & Anderson, S. C., 2008. Annotated Checklist of Amphibians and Reptiles of Iran. Iran J Anim Biosyst. 4, 7-30.

Razok, A., Shams, A., & Yousaf, Z., 2020. Cerastes cerastes snakebite complicated by coagulopathy and cardiotoxicity with electrocardiographic changes. Toxicon. 188, 1-4.

Reading, C. J., Luiselli, L. M., Akani, G. C., Bonnet, X., Amori, G., Ballouard, J. M., . . . Rugiero, L., 2010. Are snake populations in widespread decline? Biol Lett. 6, 777-780.

Reid, H. A., 1956. Sea-snake bite research. Trans R Soc Trop Med Hyg. 50, 517-542.

Reid, H. A., 1961. Myoglobinuria and sea-snake-bite poisoning. Br Med J. 1, 1284-1289.

Rezaei-Orimi, J., Amrollahi-Sharifabadi, M., Aghabeiglooei, Z., Nasiri, E., & Mozaffarpur, S. A., 2022. Rhazes's methodology in the science of toxicology. Arch Toxicol. [Online ahead of print].

Rezaei-Orimi, J., Nasiri, E., Moallemi, M., & Padashi, S., 2019. A Review on the Diagnosis and Management of Bites in the Canon of Medicine of Avicenna. [In Persian]. J Mazandaran Univ Med Sci. 29, 175-188.

Rezaie-Atagholipour, M., Ghezellou, P., Hesni, M. A., Dakhteh, S. M., Ahmadian, H., & Vidal, N., 2016. Sea snakes (Elapidae, Hydrophiinae) in their westernmost extent: an updated and illustrated checklist and key to the species in the Persian Gulf and Gulf of Oman. Zookeys. 129-164.

Rezaie-Atagholipour, M., Riyahi-Bakhtiari, A., Rajabizadeh, M., & Ghezellou, P., 2012a. Status of the Annulated Sea Snake, Hydrophis cyanocinctus, in the Hara Protected Area of the Persian Gulf: (Reptilia: Elaphidae: Hydrophiinae). Zool Middle East. 57, 53-60.

Rezaie-Atagholipour, M., Riyahi-Bakhtiari, A., Sajjadi, M., Yap, C. K., Ghaffari, S., Ebrahimi-Sirizi, Z., & Ghezellou, P., 2012b. Metal concentrations in selected tissues and main prey species of the annulated sea snake (Hydrophis cyanocinctus) in the Hara Protected Area, northeastern coast of the Persian Gulf, Iran. Mar Pollut Bull. 64, 416-421.

Riley, B. D., Pizon, A. F., & Ruha, A. (2011). Snakes and other reptiles. In: L. S. Nelson, N. A. Lewin, M. A. Howland, R. S. Hoffman, L. R. Goldfrank, & N. E. Flomenbaum (Eds.), *Goldfrank's Toxicologic Emergencies.* (pp. 1601-1610). New York, USA: McGraw-Hill.

Rosenberg, H. I., Bdolah, A., & Kochva, E., 1985. Lethal factors and enzymes in the secretion from Duvernoy's gland of three colubrid snakes. J Exp Zool. 233, 5-14.

Rosenberg, H. I., Kinamon, S., Kochva, E., & Bdolah, A., 1992. The secretion of Duvernoy's gland of Malpolon monspessulanus induces haemorrhage in the lungs of mice. Toxicon. 30, 920-924.

RVSRI. (2021). Razi™ Pentavalent snake antivenom immunoglobulin prescribing information. Tehran, Iran: Razi Vaccine and Serum Research Institute (RVSRI). Retrieved from: https://english.rvsri.ac.ir/portal/home/?WEBSITE/240651/240900/240909/Pentavalent-snake-antivenom-immunoglobulin

Saameie, M. (2020, Mar 27, 2020). Venom. [In Persian]. Tehran, Iran: The Great Islamic Encyclopaedia. Retrieved from: https://cgie.org.ir/fa/article/257535

Sadeghi, M., Barazandeh, M., Zakariaei, Z., Davoodi, L., Tabaripour, R., Fakhar, M., & Zakariaei, A., 2021. Massive cutaneous complications due to snakebite: A case report and literature review. Clin Case Rep. 9, e04129.

Safaei-Mahroo, B., Ghaffari, H., Fahimi, H., Broomand, S., Yazdanian, M., Najafi-Majd, E., . . . Nasrabadi, R., 2015. The herpetofauna of Iran: checklist of taxonomy, distribution and conservation status. Asia Herpetol Res. 6, 257-290.

Safaei-Mahroo, B., Ghaffari, H., Salmabadi, S., Kamangar, A., Almasi, S., Kazemi, S. M., & Ghafoor, A., 2016. Eastern Montpellier Snake (Malpolon insignitus fuscus) Ophiophagy Behavior from Zagros Mountains. Russ J Herpetol. 24, 69-72.

Sagheb, M. M., Sharifian, M., Moini, M., & Salehi, O., 2011a. Acute renal failure and acute necrotizing pancreatitis after Echis carinatus sochureki bite, report of a rare complication from southern Iran. Prague Med Rep. 112, 67-71.

Sagheb, M. M., Sharifian, M., Moini, M., & Salehi, O., 2011b. Clinical features of snake bite in southern Iran. Trop Doct. 41, 236-237.

Salmanizadeh, H., Babaie, M., & Zolfagharian, H., 2013. In vivo evaluation of homeostatic effects of Echis carinatus snake venom in Iran. J Venom Anim Toxins Incl Trop Dis. 19, 3.

Salmanzadeh Zehkesh, S., & Mohammadpour Donighi, N., 2021. Synthesis of sodium alginate nanoparticles containing Agkistrodon halys snake venom and evaluation of biological activity and survival of colon cancer cells (SW-480). [In Persian]. Res Karyotic Cell Tissue. 2, 35-42.

Samianifard, M., Nazari, A., Tahoori, F., & Mohamadpour Dounighi, N., 2021. Proteome Analysis of Toxic Fractions of Iranian Cobra (Naja naja Oxiana) Snake Venom Using Two-Dimensional Electrophoresis and Mass Spectrometry. Arch Razi Inst. 76, 127-138.

Sanders, K. L., Lee, M. S., Mumpuni, Bertozzi, T., & Rasmussen, A. R., 2013. Multilocus phylogeny and recent rapid radiation of the viviparous sea snakes (Elapidae: Hydrophiinae). Mol Phylogenet Evol. 66, 575-591.

Sanz, L., Ayvazyan, N., & Calvete, J. J., 2008. Snake venomics of the Armenian mountain vipers Macrovipera lebetina obtusa and Vipera raddei. J Proteomics. 71, 198-209.

Saviola, A. J., Peichoto, M. E., & Mackessy, S. P., 2014. Rear-fanged snake venoms: an untapped source of novel compounds and potential drug leads. Toxin Rev. 33, 185-201.

Schaetti, B., Kucharzewski, C., Masroor, R., & Rastegar Pouyani, E., 2012. Platyceps karelini (Brandt, 1838) from Iran to Pakistan and revalidation of Coluber chesneii Martin, 1838 (Reptilia: Squamata: Colubrinae). Revue Suisse de Zoologie. 119, 441-483.

Schneemann, M., Cathomas, R., Laidlaw, S. T., El Nahas, A. M., Theakston, R. D., & Warrell, D. A., 2004. Life-threatening envenoming by the Saharan horned viper (Cerastes cerastes) causing micro-

angiopathic haemolysis, coagulopathy and acute renal failure: clinical cases and review. QJM. 97, 717-727.
Schöttler, W. H. A., 1938. The venoms of Vipera latastei and V. lebetina. [In German]. Z Hyg Infektionskr. 120, 408-434.
Schweiger, M., 1991. Coluber ravergieri Ménétries, 1832-an unusual aggressive Snake. [In German]. Herpetofauna. 13, 70.
Shadnia, S., Esmaily, H., Sasanian, G., Pajoumand, A., Hassanian-Moghaddam, H., & Abdollahi, M., 2007. Pattern of acute poisoning in Tehran-Iran in 2003. Hum Exp Toxicol. 26, 753-756.
Shahbazi, B., Najafabadi, Z. S., Goudarzi, H., Sajadi, M., Tahoori, F., & Bagheri, M., 2019. Cytotoxic effects of Pseudocerastes persicus venom and its HPLC fractions on lung cancer cells. J Venom Anim Toxins Incl Trop Dis. 25, e20190009.
Shahi, M., Jaberhashemi, S. A., Hosseinzadeh, M. S., & Kazemi, S. M., 2022. A new Record of Persian Krait Bungarus persicus Abtin, Nilson, Mobaraki, Hosseini, Dehgannejhad 2014 (Serpentes: Elapidae: Bungarinae) from Hormozgan Province, Southern Iran. Ecopersia. 10, 173-177.
Shahidi Bonjar, L., 2014. Design of a new therapy to treat snake envenomation. Drug Des Devel Ther. 8, 819-825.
Shanaki Bavarsad, M., Amoozegari, Z., & Noorbehbahani, M., 2009. Phospholipase A2 Activity in Crude Venom and Fractions Separated from Iranian Vipera Lebetina Venom. [In Persian]. Jundishapur Sci Med J. 8, 355-360.
Sharifi, I., Tabatabaie, F., Nikpour, S., Mostafavi, M., Tavakoli Oliaee, R., Sharifi, F., . . . Shahbazzadeh, D., 2021. The Effect of Naja naja oxiana Snake Venom Against Leishmania tropica Confirmed by Advanced Assays. Acta Parasitol. 66, 475-486.
Shaw, C. J., 1925. Notes on the effect of the bite of McMahons viper (E macmahonii). J Bombay Nat Hist Soc. 30, 485-486.
Shaykhi Ilanloo, S., Khani, A., Kafash, A., & Rastegar Pouyani, E., 2015. Reptile fauna of the Khajeh protected area, with assessingits similarities with physiogeographical area of the Iranian Lizards. [In Persian]. J Taxon Biosyst. 7, 13-22.
Shi, J., Yang, D., Zhang, W., & Ding, L., 2016. Distribution and infraspecies taxonomy of Gloydius halys-Gloydius intermedius complex in China (Serpentes: Crotalinae). Chin J Zool. 51, 777-798.
Shockley, C. H., 1949. Herpetological notes for Ras Jiunri, Baluchistan. Herpetologica. 5, 121-123.
Shoorabi, M., Nazarizadeh Dehkordi, M., Kaboli, M., & Rastegar Pouyani, E., 2017. Phylogenetic Relationships, Genetic Structure and Differentiation of the Caspian Cobra (Naja oxiana Eichwald 1831) snake in Iran Using D-Loop Mitochondrial DNA Marker. [In Persian]. Mod Genet J. 12, 253-263.
Sinaei, N., Zare Mirakabadi, A., Jafari, E., Najafi, A., Behnam, B., & Karami-Mohajeri, S., 2022. Induction of Apoptosis in Glioblastoma Cell Line (U87-MG) by Caspian Cobra (Naja naja oxiana) Snake Venom. Proc Natl Acad Sci India Sect B Biol Sci. 92, 269-274.
Sindaco, R., Venchi, A., & Grieco, C. (2013). *The Reptiles of the Western Palearctic. Volume 2: Annotated Checklist and Distributional Atlas of the Snakes of Europe, North Africa, Middle East and Central Asia, with an Update to Volume 1*. Latina, Italy: Edizioni Belvedere.
Sitprija, V., 2006. Snakebite nephropathy. Nephrology (Carlton). 11, 442-448.
Soleimanfallah, D., Hojati, V., Shajiee, H., Sharafi, S., Babaei Savasari, R., & Khani, S., 2018. A Study on Reptile fauna of Sefid Kouh-Aresk No-Hunting Area in Semnan Province. [In Persian]. J Anim Environ. 10, 97-106.
Soleimani, G., Shafighi Shahri, E., Shahraki, N., Godarzi, F., Soleimanzadeh Mousavi, S. H., & Tavakolikia, Z., 2021. Clinical and Laboratory Findings and Prognosis of Snake and Scorpion Bites in Children under 18 Years of Age in Southern Iran in 2018-19. Int J Pediatr. 9, 12795-12804.

Spawls, S., & Branch, W. (1995). *Dangerous Snakes of Africa: Natural History - Species Directory - Venoms and Snakebite*. Fort Myers, FL: Ralph Curtis Publishing.

Stümpel, N., & Joger, U., 2009. Recent advances in phylogeny and taxonomy of Near and Middle Eastern Vipers–an update. Zookeys. 31, 179-191.

Stümpel, N., Rajabizadeh, M., Avcı, A., Wüster, W., & Joger, U., 2016. Phylogeny and diversification of mountain vipers (Montivipera , Nilson et al., 2001) triggered by multiple Plio–Pleistocene refugia and high-mountain topography in the Near and Middle East. Mol Phylogenet Evol. 101, 336-351.

Sultanov, M. N., 1966. Clinical course and treatment of Tarbophis fallax iberus bite. [In Russian]. Med Parazitol (Mosk). 35, 570-572.

Sultanov, M. N., 1983. Experience with the treatment of poisonous snake bites. [In Russian]. Klin Med (Mosk). 61, 105-109.

Sunagar, K., Jackson, T. N., Undheim, E. A., Ali, S. A., Antunes, A., & Fry, B. G., 2013. Three-fingered RAVERs: Rapid Accumulation of Variations in Exposed Residues of snake venom toxins. Toxins (Basel). 5, 2172-2208.

Sunagar, K., Khochare, S., Senji Laxme, R. R., Attarde, S., Dam, P., Suranse, V., . . . Captain, A., 2021. A Wolf in Another Wolf's Clothing: Post-Genomic Regulation Dictates Venom Profiles of Medically-Important Cryptic Kraits in India. Toxins (Basel). 13.

Suraweera, W., Warrell, D., Whitaker, R., Menon, G., Rodrigues, R., Fu, S. H., . . . Jha, P., 2020. Trends in snakebite deaths in India from 2000 to 2019 in a nationally representative mortality study. Elife. 9.

Taheri, S., 2015. The Inversion of a Symbol Concept. [In Persian]. J Fine Art Vis Art. 20, 25-34.

Taherian, M., Yaghoobi, H., & Bandehpour, M., 2016. Evaluation of the Coagulant Effect of Zanjani and Latifi Viper Snake Venom Endemic in Iran. Trends Pept Protein Sci. 1, 27-30.

Talebi Mehrdar, M., 2020. Two Proteins From Snake Venom Have Potent Antibacterial Effects Against Bacillus Anthracis and Streptococcus Pneumoniae. Iran J Toxicol. 14, 139-144.

Talebi Mehrdar, M., Madani, R., Hajihosseini, R., & Moradi Bidhendi, S., 2017. Antibacterial Activity of Isolated Immunodominant Proteins of Naja Naja (Oxiana) Venom. Iran J Pharm Res. 16, 297-305.

Talebzadeh-Farooji, M., Amininasab, M., Elmi, M. M., Naderi-Manesh, H., & Sarbolouki, M. N., 2004. Solution structure of long neurotoxin NTX-1 from the venom of Naja naja oxiana by 2D-NMR spectroscopy. Eur J Biochem. 271, 4950-4957.

Talyzin, F. F. (1963). *Snakes. [In Russian]*. Retrieved from Moscow, Russia:

Tamiya, N., & Puffer, H., 1974. Lethality of sea snake venoms. Toxicon. 12, 85-87.

Tan, C. H., Tan, K. Y., Lim, S. E., & Tan, N. H., 2015. Venomics of the beaked sea snake, Hydrophis schistosus: A minimalist toxin arsenal and its cross-neutralization by heterologous antivenoms. J Proteomics. 126, 121-130.

Tan, C. H., Tan, K. Y., Ng, T. S., Sim, S. M., & Tan, N. H., 2018. Venom Proteome of Spine-Bellied Sea Snake (Hydrophis curtus) from Penang, Malaysia: Toxicity Correlation, Immunoprofiling and Cross-Neutralization by Sea Snake Antivenom. Toxins (Basel). 11, 3.

Theakston, R. D., Phillips, R. E., Warrell, D. A., Galagedera, Y., Abeysekera, D. T., Dissanayaka, P., . . . Aloysius, D. J., 1990. Envenoming by the common krait (Bungarus caeruleus) and Sri Lankan cobra (Naja naja naja): efficacy and complications of therapy with Haffkine antivenom. Trans R Soc Trop Med Hyg. 84, 301-308.

Theakston, R. D., & Warrell, D. A., 1991. Antivenoms: a list of hyperimmune sera currently available for the treatment of envenoming by bites and stings. Toxicon. 29, 1419-1470.

Todehdehghan, F., Salemi, A., & Fathinia, B., 2019. Identification key for Echis snakes (Serpents: Viperidae) of the East, South East, and South West of Iran. J Entomol Zool Stud. 7, 1180-1185.

Tok, C. V., & Kumluts, Y., 1996. On Vipera ammodytes transcaucasiana (Viperidae) from Perşembe, Black Sea region of Turkey. Zool Middle East. 13, 47-50.

Tsai, M. C., Lee, C. Y., & Bdolah, A., 1983. Mode of neuromuscular blocking action of a toxic phospholipase A2 from Pseudocerastes fieldi (Field's horned viper) snake venom. Toxicon. 21, 527-534.

Tu, A. T., 1974. Sea snake investigation in the Gulf of Thailand. J Herpetol. 8, 201-210.

Tuniyev, B., Nilson, G., Agasyan, A., Orlov, N. L., & Tuniyev, S. (2009a). *Vipera eriwanensis. The IUCN Red List of Threatened Species 2009: e.T164679A114547682*. Retrieved from https://www.iucnredlist.org/species/164679/114547682

Tuniyev, B., Nilson, G., Kasaka, Y., Avci, A., Agasyan, A., Orlov, N. L., & Tuniyev, S. (2009b). *Vipera transcaucasiana. The IUCN Red List of Threatened Species 2009: e.T164708A114549008*. Retrieved from https://www.iucnredlist.org/species/164708/114549008

Tushiev, A., 1963. On the issue of clinics and treatment in bites by venomous snakes. [In Russian]. Zdravookhr Turkmenistana. 7, 32-34

Valenta, J., Stach, Z., & Svitek, M., 2010. Acute pancreatitis after viperid snake cerastes cerastes envenoming: a case report. Prague Med Rep. 111, 69-75.

Van den Enden, E., & Bottieau, E., 2005. Envenoming by the viperid snake Eristicophis macmahonii. Toxicon. 46, 918-920.

Wallach, V., Williams, K. L., & Boundy, J. (2017). *Snakes of the World*. Boca Raton, FL: CRC Press

Warrell, D. A. (1994). Sea Snake Bites in the Asia-Pacific Region. In: P. Gopalakrishnakone (Ed.), *Sea Snake Toxinology* (pp. 1-36). Singapore: Singapore University Press.

Warrell, D. A. (1995). Clinical Toxicology of Snakebite in Africa and The Middle East / Arabian Peninsula. In: J. Meier & J. White (Eds.), *Handbook of Clinical Toxicology of Animal Venoms and Poisons* (pp. 433-492). Boca Raton, USA: CRC Press

Warrell, D. A., 2010. Snake bite. Lancet. 375, 77-88.

Warrell, D. A. (2016). *Guidelines for the management of snake-bites* (2nd ed.). New Delhi; India: WHO Press.

Weinstein, S. A., Griffin, R., & Ismail, A. K., 2014. Non-front-fanged colubroid ("colubrid") snakebites: three cases of local envenoming by the mangrove or ringed cat-eyed snake (Boiga dendrophila; Colubridae, Colubrinae), the Western beaked snake (Rhamphiophis oxyrhynchus; Lamprophiidae, Psammophinae) and the rain forest cat-eyed snake (Leptodeira frenata; Dipsadidae). Clin Toxicol (Phila). 52, 277-282.

Weinstein, S. A., & Minton, S. A., 1984. Lethal potencies and immunoelectrophoretic profiles of venoms and Vipera bornmulleri and Vipera latifii. Toxicon. 22, 625-629.

Weinstein, S. A., Warrell, D. A., & Keyler, D. E. (2023a). Medically significant bites by non-front-fanged snakes (NFFCs). In *"Venomous" Bites from "Non-Venomous Snakes"* (2nd ed., pp. 155-594). Cambridge, MA: Elsevier.

Weinstein, S. A., Warrell, D. A., & Keyler, D. E. (2023b). *"Venomous" Bites from "Non-Venomous Snakes"* (2nd Ed.). Cambridge, MA Elsevier

Weinstein, S. A., White, J., Keyler, D. E., & Warrell, D. A., 2013. Non-front-fanged colubroid snakes: a current evidence-based analysis of medical significance. Toxicon. 69, 103-113.

White, J., 2005. Snake venoms and coagulopathy. Toxicon. 45, 951-967.

World Health Organization. (2021). Antivenom and Manufacturers. Snakebite Information and Data Platform. Retrieved from: https://www.who.int/teams/control-of-neglected-tropical-diseases/snakebite-envenoming/snakebite-information-and-data-platform/overview#tab=tab_1

Xie, B., Dashevsky, D., Rokyta, D., Ghezellou, P., Fathinia, B., Shi, Q., . . . Fry, B. G., 2022. Dynamic genetic differentiation drives the widespread structural and functional convergent evolution of snake venom proteinaceous toxins. BMC Biol. 20, 4.

Yaghmour, F., Els, J., Maio, E., Whittington-Jones, B., Samara, F., El Sayed, Y., . . . Mupandawana, M., 2022. Oil spill causes mass mortality of sea snakes in the Gulf of Oman. Sci Total Environ. 825, 154072.

Yayon, A., Sikular, E., & Keynan, A., 1988. Desert black snake bites. [In Hebrew]. Harefuah. 115, 269-270.

Yousefi, M., Ahmadi, M., Nourani, E., Behrooz, R., Rajabizadeh, M., Geniez, P., & Kaboli, M., 2015. Upward Altitudinal Shifts in Habitat Suitability of Mountain Vipers since the Last Glacial Maximum. PLoS One. 10, e0138087.

Yousefi, M., Kafash, A., Khani, A., & Nabati, N., 2020. Applying species distribution models in public health research by predicting snakebite risk using venomous snakes' habitat suitability as an indicating factor. Sci Rep. 10, 18073.

Yousefi, M., Kafash, A., Valizadegan, N., Sheykhi Ilanloo, S., Rajabizadeh, M., Malekoutikhah, S., . . . Ashrafi, S., 2019. Climate Change is a Major Problem for Biodiversity Conservation: A Systematic Review of Recent Studies in Iran. Contemp Probl Ecol. 12, 394-403.

Zaeri, S., Aghaei, Z., Mashayekhi, N. R., Salemi, A., & Seyedian, R. J., 2021a. Pharmacoligical characterization of the iranian Cerastes cerastes gasperettii (Reptilia: Ophidia: Viperidae) venom. J Emerg Pract Trauma. 7, 123-126.

Zaeri, S., Fatemikia, H., Kamyab, M., Esmaili, A., Kim, E., Mohammadpour Dounighi, N., . . . Seyedian, R., 2021b. Hemodynamic Changes Provoked through Intravascular Injection of the Echis carinatus Venom in Rats. Arch Razi Inst. 76, 599-607.

Zaher, H., Murphy, R. W., Arredondo, J. C., Graboski, R., Machado-Filho, P. R., Mahlow, K., . . . Grazziotin, F. G., 2019. Large-scale molecular phylogeny, morphology, divergence-time estimation, and the fossil record of advanced caenophidian snakes (Squamata: Serpentes). PLoS One. 14, e0216148.

Zamani, N., Modir-Fallah Rad, L., Soltaninejad, K., & Shadnia, S., 2016. A retrospective study on snakebite victims in a tertiary referral center. Iran J Toxicol. 10, 47-50.

Zare Mirakabadi, A., & Horrieh, P., 2020. The toxicity induction in human dermal fibroblasts (HDF) cells by saliva of Echis carinatus sochureki. [In Persian]. Res Karyotic Cell Tissue. 1, 1-8.

Zare Mirakabadi, A., & Teymurzadeh, S. (2009). *Venomous Snakes of Iran; Prevention, First Aid and Treatment. [In Persian]*. Tehran, Iran: Teimourzadeh Publication.

Zargan, J., Mirzaei Nodushan, M., Sobati, H., Haji Noormohammadi, A., Goodarzi, H. R., & Ebrahimi, F., 2022. In-Vitro Evaluation of Anticancer and Antibacterial Properties of Pseudocerastes Persicus Snake Venom Fractions. [In Persian]. Jundishapur Sci Med J. 21, 122-137.

Zinenko, O., Stumpel, N., Mazanaeva, L., Bakiev, A., Shiryaev, K., Pavlov, A., . . . Joger, U., 2015. Mitochondrial phylogeny shows multiple independent ecological transitions and northern dispersion despite of Pleistocene glaciations in meadow and steppe vipers (Vipera ursinii and Vipera renardi). Mol Phylogenet Evol. 84, 85-100.

Zolfagharian, H., & Dounighi, N. M., 2015. Study on development of Vipera lebetina snake anti-venom in chicken egg yolk for passive immunization. Hum Vaccin Immunother. 11, 2734-2739.

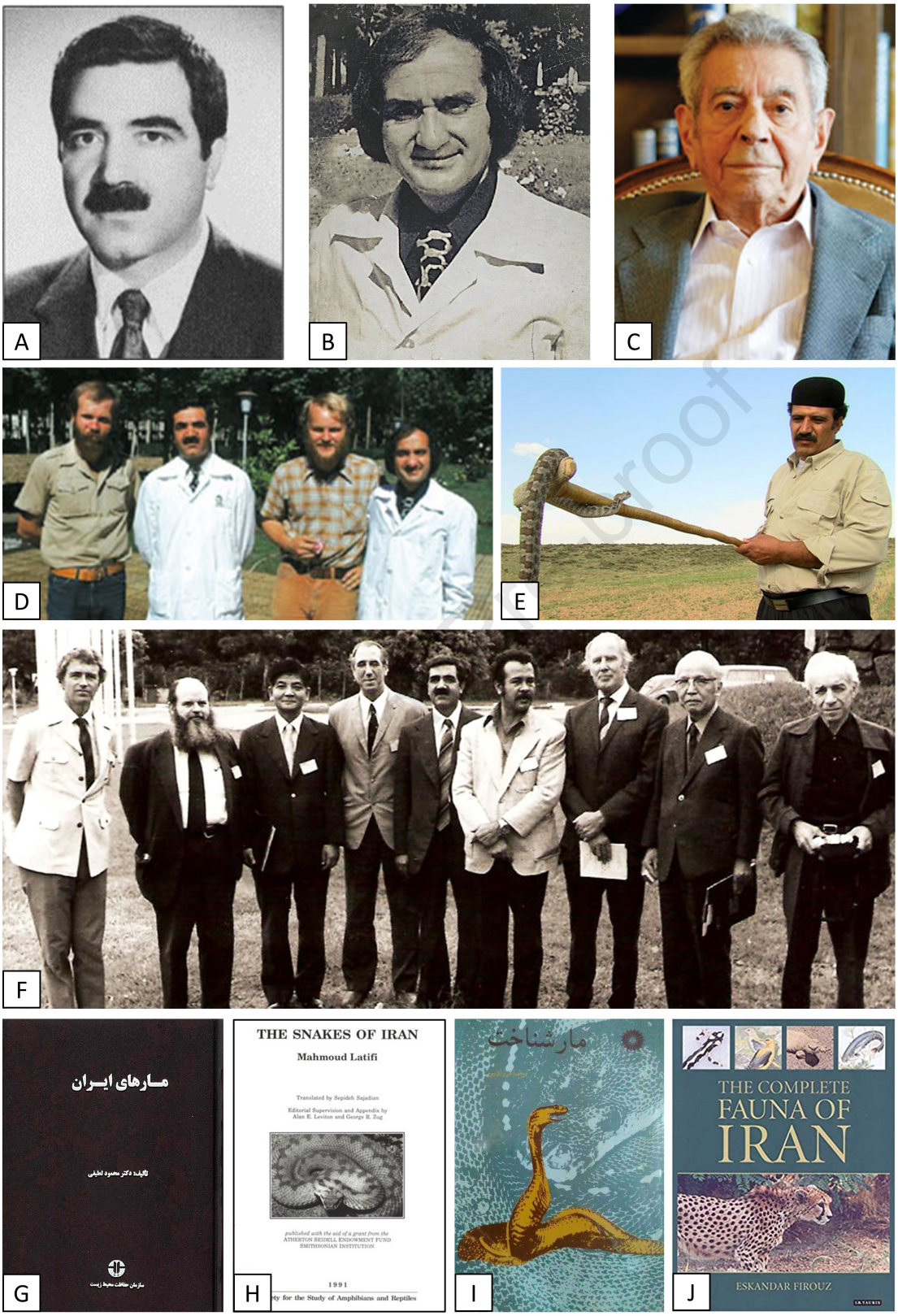
A
B
C
D
E
F
G
مارهای ایران
تألیف: دکتر محمود لطیفی
H
THE SNAKES OF IRAN
Mahmoud Latifi
Translated by Sepideh Sajadian
Editorial Supervision and Appendix by
Alan E. Leviton and George R. Zug
published with the aid of a grant from the
ATHERTON SEIDELL ENDOWMENT FUND
SMITHSONIAN INSTITUTION
1991
I
مارشناخت
J
THE COMPLETE
FAUNA OF
IRAN
ESKANDAR FIROUZ

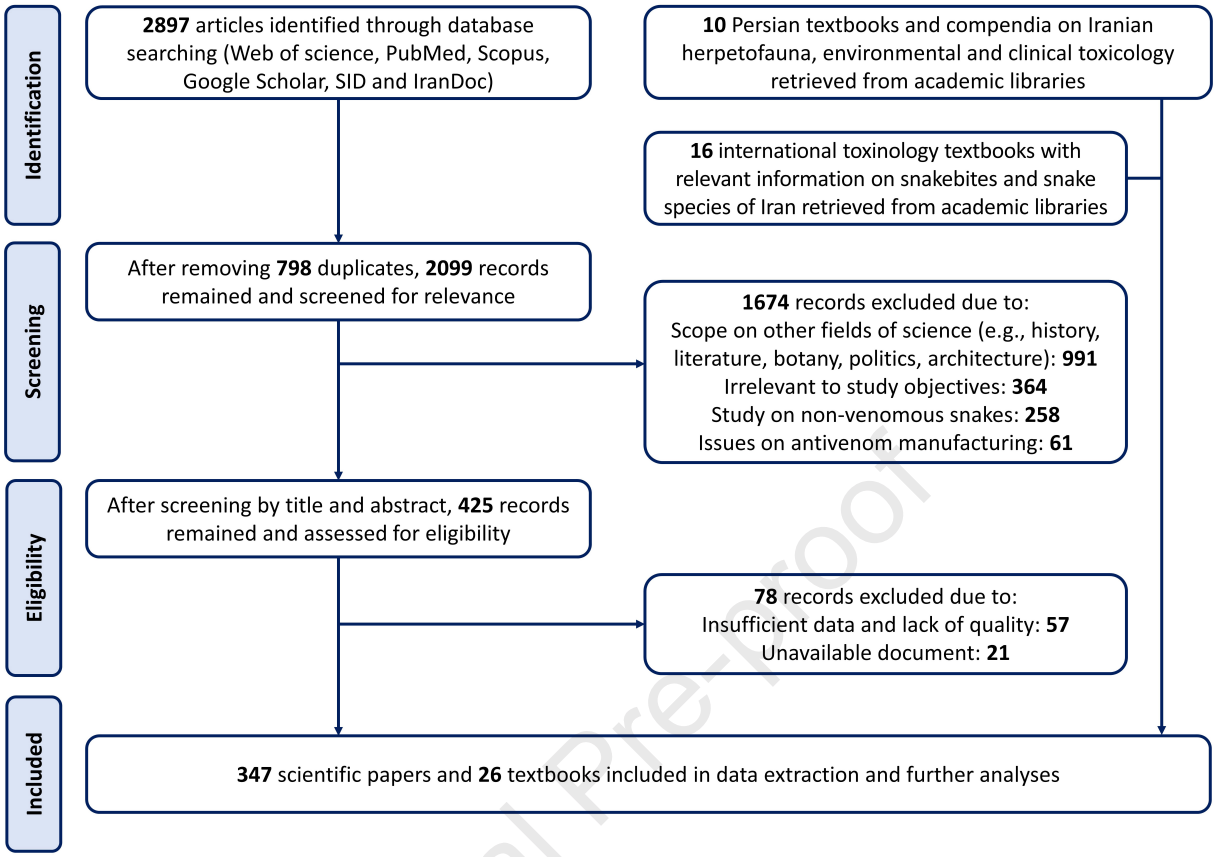

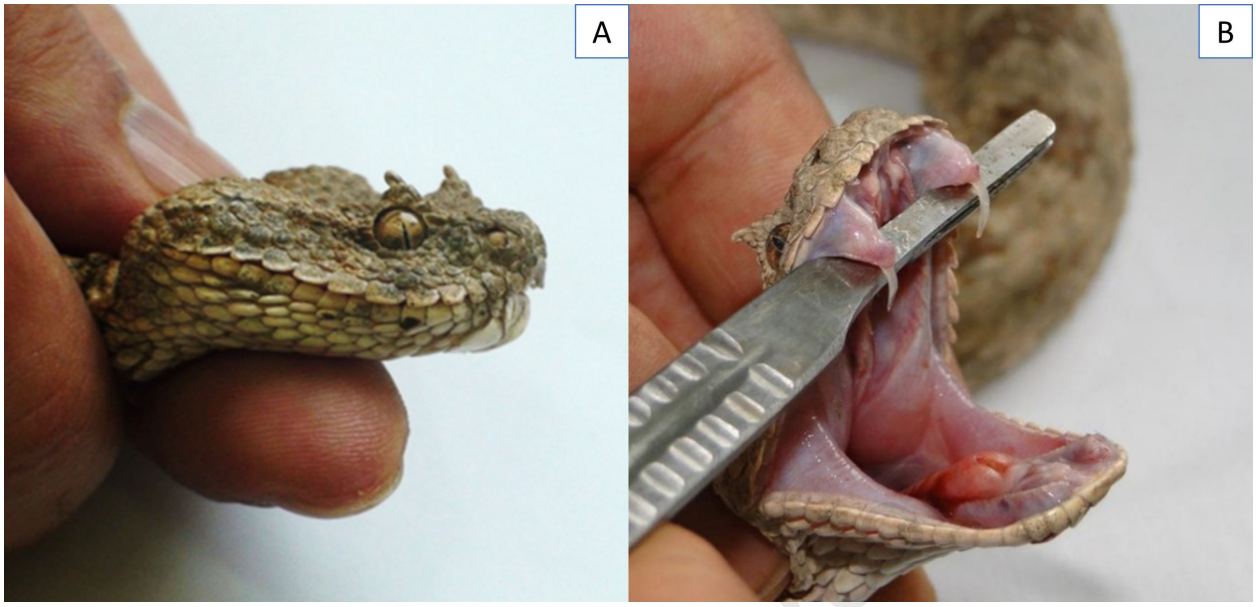

HIGHLIGHTS

1. A comprehensive review on medically important snakes in Iran regarding geographical distribution, taxonomy, venom composition

2. A focus on environmental value of Iran's medically important snakes

3. A critical appraisal of clinical effects of medically important snakes in Iran

4. A detailed evaluation of clinical management of snakebite envenoming in Iran

Ethical Statement

No experimentation on human or animal subjects was involved in this study.

Declaration of interests

☒ The authors declare that they have no known competing financial interests or personal relationships that could have appeared to influence the work reported in this paper.

☐ The authors declare the following financial interests/personal relationships which may be considered as potential competing interests: